



Outcome of revision total knee arthroplasty with bone allograft in 30 cases

Katrina F. FRANKE, Iulian NUSEM, Gaugin GAMBOA, David A.F. MORGAN

From Queensland Hips and Knees, Brisbane Private Hospital, Queensland, Australia

Revision Total Knee Arthroplasty is often complicated by large bone defects in the distal femur and proximal tibia. These defects can be managed in a variety of ways including the use of allograft bone. The purpose of this study was to retrospectively evaluate the clinical outcome of revision total knee arthroplasty cases where allograft bone was used.

Thirty revision TKA's (27 patients) performed between 1994 and 2009 were followed for a mean of 5 years (1-14 years). Preoperative bone defects were classified using the Anderson Orthopaedic Research Institute classification system. Patient follow-up entailed calculation of the Knee Society Score and radiological assessment of the revision joint replacement in addition to review of complications.

Kaplan Meier analysis predicted survivorship at 5 years as 93%, with further revision surgery as end point. The average Knee Society Score was 76.4, with 19 (63%) of knees scoring "excellent" results, 4 (14%) "good", 1 (3%) "fair" and 6 (20%) were "poor". The overall complication rate was 23.3%. Radiological lucency was demonstrated on recent radiographs for one patient. Three knees were re-revised at 1 year, 6 years and 8 years respectively.

Our study demonstrates promising short to medium term results with the use of allograft bone in revision total knee replacement presenting with significant bone loss.

Keywords : revision knee arthroplasty ; allograft bone grafts.

INTRODUCTION

Some cases of revision total knee arthroplasty (TKA) present with large bone defects. These can be secondary to osteolysis, implant migration, or bone loss due to multiple revisions. Large bone defects can be managed using megaprotheses, custom made implants, metal augments and stems, cement fillers, or allograft bone. The method chosen depends on multiple factors, including size and type of defect, cause of bone loss and patient specific factors, including age.

-
- Katrina F. Franke¹, Orthopaedic surgeon.
 - Iulian Nusem^{1,2,5}, Orthopaedic surgeon.
 - Gaugin Gamboa³, Orthopaedic surgeon.
 - David A.F. Morgan^{3,4,5}, Orthopaedic surgeon.

¹*Department of Orthopaedics, Logan Hospital, Queensland, Australia.*

²*Griffith University, Gold Coast Campus, Queensland, Australia.*

³*Queensland Hips and Knees, Brisbane Private Hospital, Queensland, Australia.*

⁴*University of Queensland, Queensland, Australia.*

⁵*Queensland Bone Bank, Queensland, Australia.*

Correspondence : Katrina F. Franke, Orthopaedic Department, Logan Hospital, Armstrong Road, Meadowbrook 4131, Queensland. E-mail : katrina_franke@health.qld.gov.au

© 2013, Acta Orthopædica Belgica.

There are several advantages for using bone allograft to fill bone defects, including the ability to fashion the allograft to fit the defect. This enables restoration of a good anatomical framework in which to place the metallic prosthesis. Restoration of bone stock is advantageous in the possible event that further operative management be needed at a later stage. Although allograft use requires a great deal of preoperative planning, fashioning of the graft occurs intraoperatively, making this a dynamic process. It is often noted that estimation of defect size from radiological studies preoperatively underestimates the true bone defect size. Dynamic fashioning hence allows more accurate and complete filling of the bone loss. Bulk allograft is available as proximal tibia and distal femur, and femoral head, which is also commonly used as a source of morsellised bone stock.

Disadvantages of bone allograft use include a reported increase in susceptibility to infection (2), and potential for disease transmission (4). There is also potential for bone resorption due to immune reaction (3), fracture (2), and non-union of the allograft (2,5,13).

The purpose of this study is to present medium-term clinical and radiological review of patients

who received allograft bone in complex cases of revision TKA presenting with bone defects.

PATIENTS AND METHODS

Between 1994 and 2009, 33 revision TKA procedures using allograft bone were performed in 30 patients. All operations were performed at one hospital by the senior author (DAFM). Three patients were excluded from the study, as follow-up Knee Society Score (KSS) score had not been calculated prior to their deaths. It is noted however that patients' graft survival was 1 year, 7 years and 8 years respectively with no plan for further surgical management. Hence, follow-up was performed on 30 revision TKA procedures in 27 patients.

Aseptic loosening of primary knee replacement was the reason for 29 revision surgeries, and one revision was performed following aseptic loosening of a unicompartmental knee replacement. Minimum follow-up was 1 year, with the average of 5 years (1-14 years) (Table I). The average age at time of surgery was 72.1 years (60-85 years). One patient was lost to follow-up after one year, and hence was regarded as a failed procedure. Review of the Australian National Joint Registry did not reveal further revision surgery for this patient.

Bone defects were classified using the Anderson Orthopaedic Research Institute (AORI) bone defect classification (7) (Fig. 1). Preoperatively, 13 knees (43%)

Table I. — Clinical characteristics of 27 patients who had revision TKA with bone allograft augmentation

Clinical characteristics		Number
Age at time of surgery		72.1 year (60-85 years)
Follow-up time		5 years (1-14 years)
Gender	Male	12
	Female	15
Surgical side	left	14
	right	16
Anderson Orthopaedic Research Institute classification	AORI 1	13 (43%)
	AORI 2a	6 (20%)
	AORI 2b	2 (7%)
	AORI 3	9 (30%)
Bone defect	Femoral and Tibial	11 (37%)
	Tibial alone	18 (60%)
	Femoral alone	1 (3%)
Allograft type	morsellised	21 (70%)
	bulk	9 (30%)

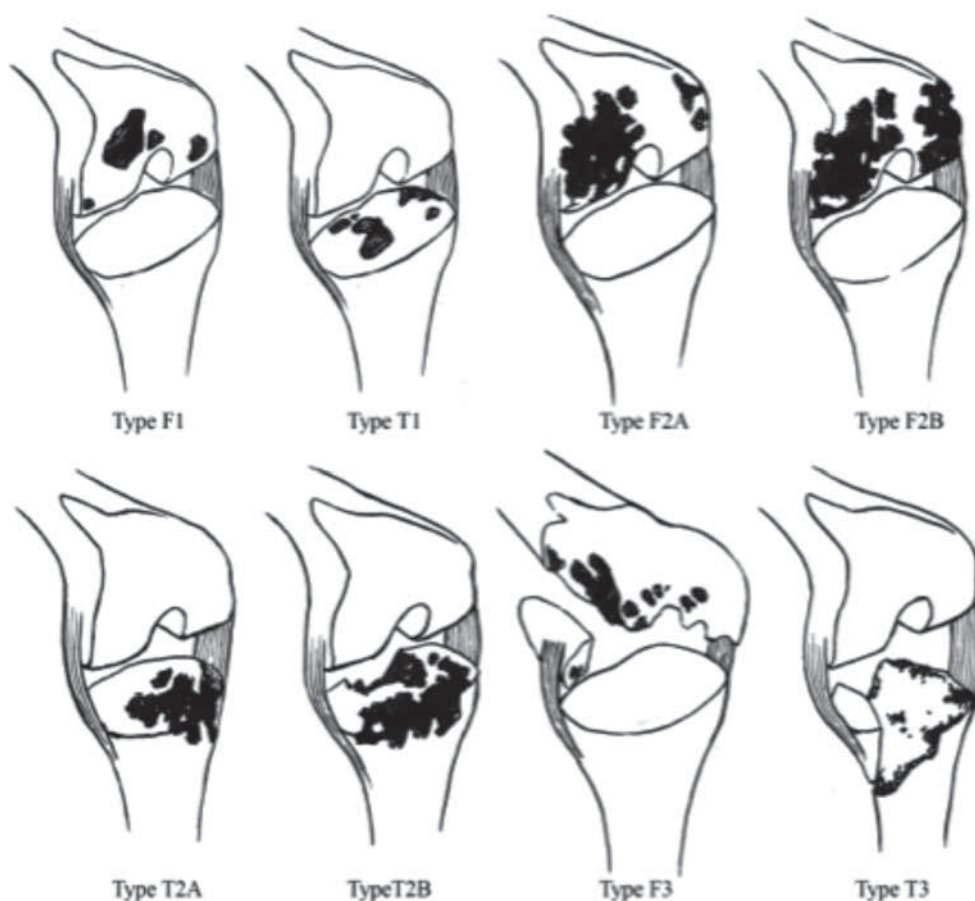


Fig. 1. — Anderson Orthopaedic Research Institute (AORI) classification system (Engh 1997). Type F1-intact metaphyseal cortical bone, femur. Type T1-intact metaphyseal cortical bone, tibia. Type F2A-damaged metaphyseal cortical bone, femur, unicondylar. Type F2B-damaged metaphyseal cortical bone, femur, bicondylar. Type T2A-damaged metaphyseal cortical bone, tibia, one plateau. Type T2B-damaged metaphyseal cortical bone, tibia, two plateaus. Type F3-deficient metaphyseal cortical bone, with major loss of femoral condyle. Type T3-deficient metaphyseal cortical bone, with major loss of tibial plateau. (Permission granted to use these image from Nova Science Publishers, Inc).

were classified as type 1 defects, 6 knees (20%) as type 2a defects, 2 knees (7%) as type 2b defects and 9 knees (30%) as type 3 defects (Fig. 2, 3). Eighteen knees (60%) presented with isolated tibial bone defects, 11 knees (37%) had both tibial and femoral bone loss, and 1 knee (3%) had an isolated femoral bone defect. Morsellised allograft was used in 21 (70%) cases. In 2 (22%) of these cases, structural allograft was used to reconstruct both tibial and femoral defects, in 6 (66%) cases, structural allograft was used to reconstruct tibial defects, and in 1 case (11%), structural allograft was used to reconstruct femoral defects (Fig. 4, 5). The total number of structural allografts used was 11.

All allografts were sourced from the Queensland Bone Bank, which complies with all standards of the American

Association of Tissue Banks (17) and with the code of good manufacturing of the Therapeutic Goods Administration (TGA) in Australia. All allografts were sterilized using gamma irradiation (25 +/- 5 kGy).

Surgical technique

The knee was approached via a medial parapatellar approach using the previous skin incision. After adequate exposure, the failed implants were removed along with nonviable bone and necrotic tissue, until a healthy, bleeding tissue bed was achieved. Five separate tissue samples were taken and sent for testing, to ensure there was no infection. The bone defects were then re-assessed and the type of allograft needed was determined. Structural

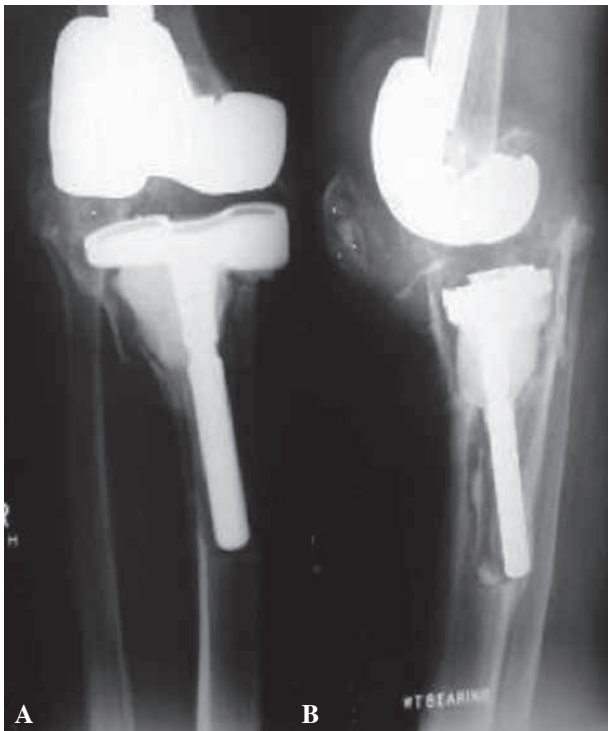


Fig. 2. — Preoperative anteroposterior (A) and lateral (B) radiographs of a right knee demonstrating an AORI type-3 tibial defect. (Permission granted to use these images from Nova Science Publishers, Inc).

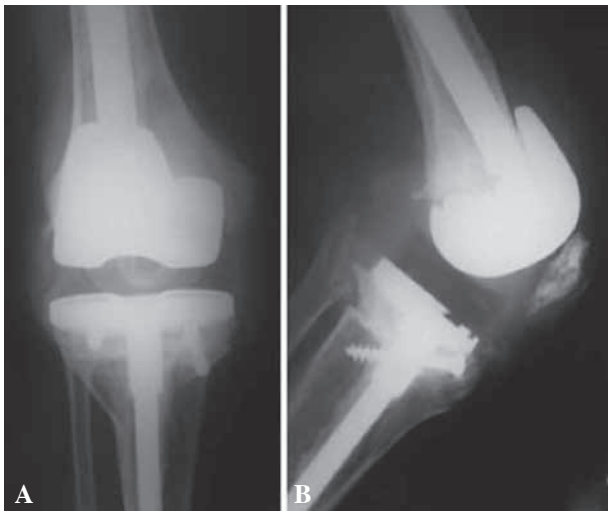


Fig. 3. — Preoperative anteroposterior (A) and lateral (B) radiographs of a right knee demonstrating an AORI type-3 femoral defect obtained eight years after revision TKA using a proximal tibial allograft. Note union of the allograft to host bone and no signs of loosening of the tibial implant. (Permission granted to use these images from Nova Science Publishers, Inc).

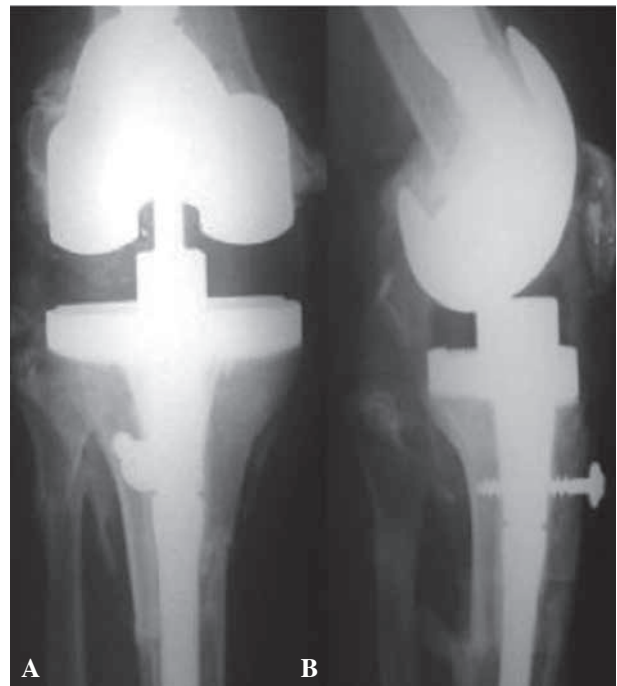

Fig. 4. — Post operative anteroposterior (A) and lateral (B) radiographs showing a revision with tibial allograft-implant composite. The tibial tubercle osteotomy is reattached to the allograft with a screw. (Permission granted to use these images from Nova Science Publishers, Inc).

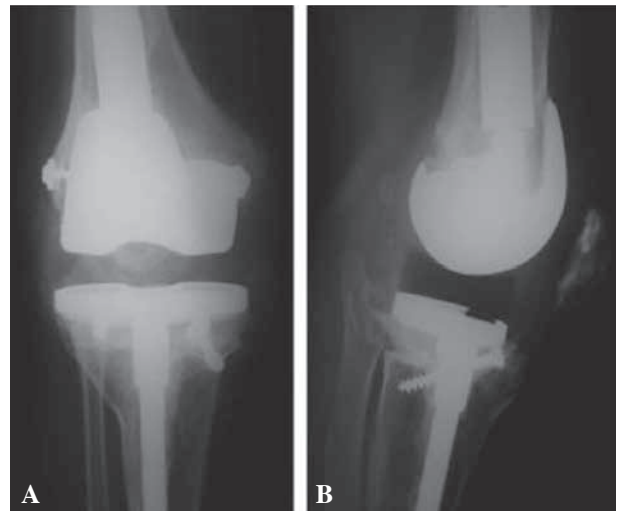


Fig. 5. — Anteroposterior (A) and lateral (B) radiographs showing a revision with femoral allograft-implant composite. The epicondyles are reattached to the allograft with screws. (Permission granted to use these images from Nova Science Publishers, Inc).

allograft was then brought into the operating room, samples were taken for bacteriologic studies and the allograft was immersed in warm Betadine solution to thaw. The level of joint line was then determined from intact host bone. The host femoral and/or tibial canals were reamed until a good press fit of the trial stem was achieved. With the trial implants in place, the amount of bone loss was evaluated and the size of allograft calculated. The allograft was fashioned to size on a standard cutting jig. Grafts were oversized and then trimmed as necessary. A step cut osteotomy of the host bone at the host allograft junction was performed, which assisted in maintaining rotational stability and increased the host-allograft contact surface area. Fixation of the implant to the allograft was achieved using cementing methods. The stem was then inserted into the prereamed tibial or femoral medullary canal, and the allograft-implant composite was fitted to host bone. For contained defects, morsellised bone was prepared from thawed femoral head using a bone mill, and was then press fit into defects as required, before the fitting of new implants. Leg length, patella tracking, ROM and knee tension were assessed. Wounds were then thoroughly washed with pulse lavage, and the knee was closed in layers over a drain. Postoperatively, ROM exercises were commenced as soon as possible after the surgery. Protected weight bearing was maintained until there were radiological signs of union between the host and allograft bone.

Patients were reviewed by an independent investigator not involved in the surgical procedure (KFF). They were assessed using the KSS (11), where a KSS score of 80 to 100 was considered as excellent, a score of 70 to 79 was considered as good, a score of 60 to 69 was considered as fair, and a score below 60 was considered as poor. Range of motion was measured using a goniometer. Radiographs were analyzed for signs of loosening, implant migration, graft resorption, graft fracture and graft fragmentation. Joint alignment measurements were also made on radiographs to assist with calculation of the anatomical axis for KSS.

Survivorship analysis was performed using Kaplan-Meier survivorship curves and 95% confidence intervals were identified at 5 and 10 years post operatively with the need for re-revision of the implant or the allograft considered as end point.

RESULTS

The patients were followed for a mean of 5 years (1-14 years). At the last review, using the KSS,

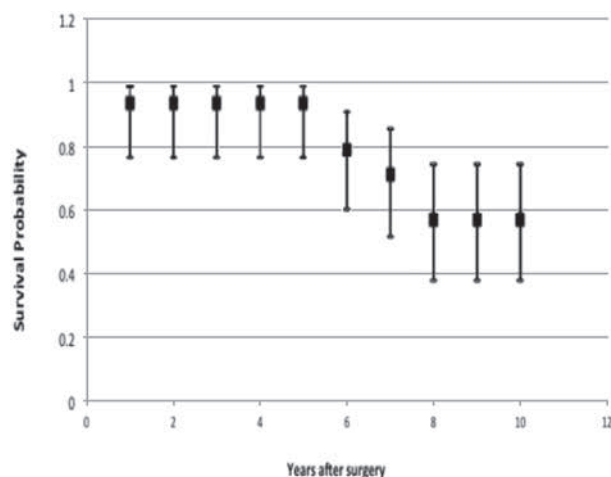


Fig. 6. — Kaplan-Meier Survivorship curve for revision TKR with allograft with confidence intervals.

19 knees (63%) were graded as “excellent”, 4 knees (13%) were graded as “good”, 1 knee (3%) was graded as “fair”, and 6 knees (20%) were graded as “poor”. The average post operative KSS was 76.4 with a range of 0 (patient lost to follow-up) to 99.

A revision-free survival was calculated as 93% at 5 years (95% confidence interval 0.765-0.988) and 57% at 10 years (95% confidence interval 0.378-0.742) (Fig. 6).

Three knees were re-revised for aseptic loosening. Of them, one knee (AORI T3, F3 defects ; structural allograft to tibia and femur) required further surgery at one year for aseptic loosening of the femoral component. At 6 years, the patients KSS was 95 points. One knee (AORI T3, structural allograft) had further surgery at 6 years using structural allografts to both tibia and femur. At 10 years post re-revision, the KSS was 90 points. One patient (AORI T3, F1 defects ; structural allograft to tibia, morsellised graft to femur) presented with loosening of the femoral component at 8 years. Structural allograft was used to manage the femoral defect. The KSS was 60 points at 6 years.

Radiolucencies around the medial tibial plateau in one knee (AORI T2a, morsellised graft) at 3 years after the revision was noted. The patient was asymptomatic and had a KSS of 88 points.

Complications were encountered in 7 cases (23%) (Table II). Three patients presented with late

Table II. — Complication breakdown

Complication	Number
Joint infection	3 (10%)
Haematoma requiring evacuation	1 (3.3%)
Quadriceps tendon rupture	1 (3.3%)
Non union	1 (3.3%)
Symptomatic DVT	1 (3.3%)

infections (at 2, 6 and 7 years). Of them, one patient was managed with a two-stage revision (KSS 89 points at 6 months), one patient was managed with a knee arthrodesis (KSS 75 points at 4 years), and one patient is being managed with suppressive antibiotic treatment for a chronic discharging sinus.

In one case, evacuation of a post-operative haematoma was required. One patient presented with quadriceps tendon rupture 10 weeks post surgery, which was primarily repaired. At last review, the patient had full range of motion of the knee with no extensor lag. One patient developed a symptomatic DVT and PE 3 years following his surgery. The patient was not treated at our facility and the details surrounding this presentation are limited. One patient underwent further surgery with supplemental morsellised bone allograft at one year for a non-union between structural allograft and host bone.

DISCUSSION

Patients undergoing revision TKA may present with large osseous defects. These commonly occur secondary to osteolysis, implant migration, implant loosening or from multiple revisions. Addressing these deficiencies is necessary to enable stable implant fixation at time of revision surgery. Allograft use offers an option to reconstruct bone deficiencies; however, it is technically demanding. In this study, both morsellised and structural allograft were used to reconstruct bone deficiencies present at the time of revision TKA.

There is reasonably limited data published in the English literature on the use of bone allograft in revision TKA. The majority of these studies comment on outcome in the short to medium term, but there is a paucity of data for long term results. A few factors

contribute to this. Firstly, the aged patient demographic, with revision surgery typically performed in the 8th decade of life contributes greatly to difficulties with long term follow-up. In addition, revision TKA together with allograft use is an uncommon procedure. The National Joint Registry for England and Wales for the year 2007 recorded 65,532 TKR of which 3,320 (5%) were revision procedures (12). Review of the Australian National Joint Replacement Registry, shows there were 380,726 knee replacement procedures recorded between 1/9/1999 and 31/12/2011. Of these, 16,420 (4.3%) were recorded as revision procedures. This included major total, major partial and minor revision procedures. Not all of these would have had large bone defects, and those that did, may have been managed in ways other than allograft use.

A review of the current literature published in English speaking journals, shows that a number of studies have been performed where bone allograft has been used in revision TKA. Reported survival rates of revision TKR with allograft bone ranges between 67% and 86% with follow-up ranging between 5 and 10 years (2,5,6,9,12). These studies suggest that the use of structural allograft for bone defects in revision TKA is a viable option.

We recognize certain limitations to our study. Firstly, it is a relatively small study size, with only 30 revision surgeries. Our study grouped all allograft use together, not differentiating cases with morsellised graft from the more complex cases managed with structural allograft. This was done to increase the study size, but has made direct comparison with other studies difficult. Our follow-up time has also been limited. Although the average follow-up time is 5 years, with a range of 1-14 years, in 15 cases (50%) it has been 4 years or less. In the majority of cases, review was conducted by a single independent interviewer who was not involved with the surgery. A small group of patients, due to distance (often residing up to 1200 km from treatment location), underwent telephone interview and clinical review by their local General Practitioners. This may lead to some variability in results. Unfortunately, preoperative Knee Society scores were not routinely recorded for all patients, eliminating the ability to make direct clinical comparisons with

post operative outcomes. It should be noted however, that pre operative assessment from clinical notes routinely showed considerable pre operative pain and functional loss, leading patients to opt for the highly complex revision surgery. On a positive note, having all operations performed by the same surgeon is a great advantage, eliminating inter-operator variability.

Direct comparison of our results with other clinical studies reviewing the use of structural allografts in revision TKA is difficult. This is due to lack of uniformity in defect classifications, type of allograft used, variation in follow-up evaluation and classification and interpretation of complications. Generally, most authors agree that success from allograft revision TKA is possible, with good functional outcome and a reasonable rate of complications.

Despite the limitations in our study, results are promising, and comparable to other published data. A large number of published studies on revision TKA with allograft use have fewer than 20 cases (13, 16,18). Therefore our study on 30 cases can be considered a significant contributor to this area of study.

In this study, graft survivability, with subsequent revision as the endpoint was calculated as 93% at 5 years (95% CI : 0.765-0.988). The 5-year data is comparable and in fact exceeds the results reported in other similar studies. Our 10-year data was calculated as 57% survivorship (95% CI : 0.38-0.74) which compares more poorly with other studies. This is contributed to by the relatively small patient subset reaching the 10-year follow-up mark. Clatworthy *et al* (5) reported 92% survivorship at 5 years and 72% at the 10-year mark for their study on 52 revision knees with allograft bone. Engh *et al* (7) report 91% survivorship at 10 years in their study in 49 knees with AORI Type 3 tibial bone defects, managed with structural allograft. There was calculated 80.7% survivorship at 5 years in a study by Bauman *et al* (2), and Lyall *et al* (12) report 85.2% survivorship at 5.4 years. Ghazavi *et al* (9) calculate a 67% survivorship at 5 years in 28 patients with massive bone loss in revision TKR.

In theory, there is an increased susceptibility to infection with the use of bone allograft, with non vascularised allografts providing an excellent nidus for infection (9). Late infection is of particular con-

cern. Three patients (10%) in our study presented with late infection. In all cases, infection manifested beyond 2 years from the index revision TKA. Although high, this rate is comparable to other studies. Rates of infection were reported to range between 0 and 10% with the use of allografts in revision TKA (1,2,5,7,9). Infection rate in non allograft revision total knee replacement has been reported as 0-4.5%, which is significantly lower than infection risk in revision surgery with allograft bone use (5,9).

In summary, our findings suggest that structural bone allograft use is a viable option in complex revision TKA with major bone loss. Increased patient numbers and extended follow-up of patients over the next few years will allow medium and long-term outcomes to be assessed with more weight.

REFERENCES

1. **Backstein D, Safir O, Gross A.** Management of bone loss. structural grafts in revision total knee arthroplasty. *Clin Orthop Relat Res.* 2006 ; 446 : 104-112.
2. **Bauman RD, Lewallen DG, Hanssen AD.** Limitations of structural allograft in revision total knee arthroplasty. *Clin Orthop Relat Res.* 2009 ; 467 : 818-824.
3. **Berrey BH Jr, Lord CF, Gebhardt MC, Mankin HJ.** Fractures of allografts. Frequency, treatment and end-results. *J Bone Joint Surg* 1990 ; 72-A : 825-833.
4. **Buck BE, Malinin TI, Brown MD.** Bone transplantation and human deficiency virus. An estimate of risk of acquired immunodeficiency syndrome (AIDS). *Clin Orthop Relat Res* 1989 ; 240 : 129-136.
5. **Clatworthy MG, Balance J, Brick GW, Chandler HP, Gross AE.** The use of structural allograft for uncontained defects in revision total knee arthroplasty : a minimum five-year review. *J Bone Joint Surg* 2001 ; 83-A : 404-411.
6. **Dennis DA, Little LR.** The structural allograft composite in revision total knee arthroplasty. *Orthopedics* 2005 ; 28 : 1005.
7. **Engh GA, Ammeen DJ.** Bone loss with revision total knee arthroplasty : defect classification and alternatives for reconstruction. *Instr Course Lect.* 1999 ; 48 : 167-175.
8. **Engh GA, Ammeen DJ.** Use of structural allograft in revision total knee Arthroplasty in knees with severe tibial bone loss. *J Bone Joint Surg* 2007 ; 89-A : 2640-2647.
9. **Ghazavi MT, Stockley I, Yee G, Davis A, Gross AE.** Reconstruction of massive bone defects with allograft in revision total knee arthroplasty. *J Bone Joint Surg* 1997 ; 79-A : 17-25.
10. **Greenwald S, Boden SD, Goldberg VM, Yaszemski M.** Bone graft substitutes : facts, fictions and applications.

American Academy of Orthopaedic Surgeons 73rd Annual Meeting, 2006 Chicago, Illinois.

11. **Insall JN, Dorr LD, Scott RD, Scott WN.** Rationale of the Knee Society clinical rating system. *Clin Orthop Relat Res.* 1989 ; 248 : 13-14.
12. **Lyall HS, Sanghrajka A, Scott G.** Severe tibial bone loss in revision total knee replacement managed with structural femoral head allograft. A prospective case series from the Royal London Hospital. *Knee* 2009 ; 16 : 326-331.
13. **Mnaymneh W, Emerson RH, Borja F, Head WC, Malinin TI.** Massive allografts in salvage revisions of failed total knee arthroplasties. *Clin Orthop Relat Res* 1990 ; 260 : 144-153.
14. **National Joint Replacement Registry, Supplementary Report 2012 :** Demographics of Knee Arthroplasty, published October 2012.
15. **Richards CJ, Garbuz DS, Pugh L, Masri B.** Revision total knee arthroplasty. clinical outcome comparison with and without the use of femoral head structural allograft. *J Arthroplasty.* 2011 ; 26 : 1299-1304.
16. **Tahakis PJ, Beaver WB, Brick GW.** Techniques and results of allograft reconstruction in revision total knee arthroplasty. *Clin Orthop Relat Res* 1994 ; 303 : 86-94.
17. **Tomford WW, Mankin HJ.** Cadaver procurement. In : Fawcett KJ, Barr AR, eds. *Tissue Banking.* American Association of Blood Banks, Arlington, 1987, pp 97-107.
18. **Wilde AH, Schickendantz MS, Stulberg BN, Go RT.** The incorporation of tibial allografts in total knee arthroplasty. *J Bone Joint Surg* 1990 ; 6-A : 815-824.