



## Calcaneocuboid distraction arthrodesis with allogenic bone grafting for correction of pes planovalgus

Natalia GUTTECK, Susanne LEBEK, David WOHLRAB, Karl-Stefan DELANK, Alexander ZEH

*From Martin Luther University, Halle Wittenberg, Germany*

Calcaneocuboid distraction arthrodesis is regarded as an excellent and reliable surgical procedure for correction of pes planovalgus. Despite a potentially high complication rate, the use of an autologous iliac crest graft is regarded as the method of choice. In a prospective trial the results in 12 feet after calcaneocuboid distraction arthrodesis for pes planovalgus correction with allogenic bone graft were investigated. The mean age was 64 (52-81) years. An angle-stable plate was generally used for fixation of the arthrodesis. Successful bone healing was diagnosed clinically if local pain was absent during weight bearing, forefoot manipulation and palpation. The AOFAS score improved from 58.9 ( $\pm 6$ ) points preoperatively to 89.8 ( $\pm 6,3$ ) points 12 months postoperatively and the Visual Analogue Pain Scale (VAS) from 5.1 ( $\pm 1,4$ ) to 0.7 ( $\pm 1$ ) 12 months postoperatively.

On radiological analysis, the lateral and dorsoplantar talometatarsal axis, hindfoot axis, the navicular floor distance and talonavicular coverage angle improved considerably. Bone fusion was observed in 11 of 12 cases postoperatively.

In conclusion, the use of an allogenic graft for calcaneocuboid distraction arthrodesis did not result in a higher pseudarthrosis rate compared with results reported after use of an autologous iliac crest graft. Fixation with an angle-stable plate is recommended.

**Keywords:** pes planovalgus ; allogenic bone graft ; hindfoot deformity ; tibialis posterior tendon dysfunction.

## INTRODUCTION

Various surgical techniques have been described for correction of pes planovalgus (4,13,16,23). It was shown that soft tissue surgery alone leads to unsatisfactory results (6,11). Triple arthrodesis is seen as an effective salvage procedure. However, it should be avoided to maintain normal biomechanics of the hindfoot (8). Therefore, surgical procedures are preferred, that are not associated with complete fusion of the hindfoot. Lengthening of the lateral column by a calcaneocuboidal distraction arthrodesis is an established method for correction of a pes planovalgus in particular if there is an additional abduction deformity of the forefoot. The question whether an autograft or an allograft should be used remains open. A nonunion rate up to 30% has been reported

- 
- Natalia Gutteck, MD, Senior House Officer.
  - Susanne Lebek, MD, Consultant.
  - David Wohlrab, Professor, Consultant.
  - Karl-Stefan Delank, Professor, Chief of the Department.
  - Alexander Zeh, MD, Assistant Professor, Consultant.
- Department of Orthopaedic Surgery and Traumatology, Martin Luther University of Halle Wittenberg, Faculty of Medicine, Halle/Saale, Germany.*
- Correspondence : Natalia Gutteck, Department of Orthopaedic Surgery and Traumatology, Martin-Luther-University of Halle-Wittenberg, Faculty of Medicine, Halle/Saale, Germany.  
E-mail : natalia.gutteck@uk-halle.de
- © 2013, Acta Orthopædica Belgica.
-

after a calcaneocuboid distraction arthrodesis with an autograft (9,23). In contrast Dolan *et al* found a faster osseous integration of an allograft in Evans osteotomy (5). There are only a few reports about comparative results regarding the use of allogenic or autologous bone for lateral column lengthening. Grier *et al* observed a pseudarthrosis rate under 6% with allograft compared with 30% with autograft (9).

Distraction arthrodesis with autologous bone taken from the iliac crest is a challenging procedure: besides donor site morbidity, a complication rates from 0.5 to 63% have been reported. The convalescence takes longer (14,20). Severe complications have been reported, such as pelvic fractures, injuries of the iliosacral joint, nerve and vascular injuries and deep wound infections, besides less severe complications like persisting pain, local hypaesthesia, superficial wound infection, wound healing disturbances, haematomas and keloid formation (14,20).

The use of processed allografts presents several advantages: their availability irrespective of the anatomic situation and bone quality, absence of donor site complications. In a prospective trial the results after calcaneocuboid distraction arthrodesis for correction of pes planovalgus by means of an allograft were analyzed.

## MATERIAL AND METHODS

In a prospective study, the results after a calcaneocuboid arthrodesis for pes planovalgus correction (stage 2b-4) in 12 (8 women, 4 men) consecutive patients were analyzed. The mean age was 64 (52-81) years. The deformity was associated with long-standing tibialis posterior tendon insufficiency. Forefoot abduction was present in all cases. Two patients smoked and two other patients had diabetes. No patient had systemic rheumatoid disease.

Femoral heads harvested during total hip arthroplasties which were processed using the Marburg Bone Bank System by thermal disinfection (Telos, Marburg, Germany) were used for graft preparation (7). A trapezoid wedge harvested from the head-neck junction was inserted in press fit manner after cartilage removal and distraction of the calcaneocuboidal joint (Fig. 2). The graft was placed with its cortical bone side laterally (Fig. 3). The mean graft size was 11.9 mm (10-18 mm). The calcaneocuboid contact surfaces were repeatedly drilled to enhance angiogenesis. Correct alignment of the talonavicular

joint was assessed by fluoroscopy. The preparation and placement of the graft were evaluated as correct if motion of the graft or opening of the arthrodesis were absent during inversion and eversion of the foot.

An angle-stable plate was used in most patients for fixation of the arthrodesis (Fa. Intercus GmbH, Bad Blabkenburg, Germany) (Fig. 1, 2). A lag screw was used in two patients. K-wire was used in one patient. A calcaneocuboid distraction arthrodesis without any further procedure was performed in three cases. Talonavicular fusion as additional surgical procedure was performed in three patients, transfer of the flexor digitorum longus tendon transfer in four, navicular-cuneiform fusion in one and tarsometatarsal I fusion in one. All patients were treated in a lower leg plaster cast and mobilised with floor contact for 8 weeks.

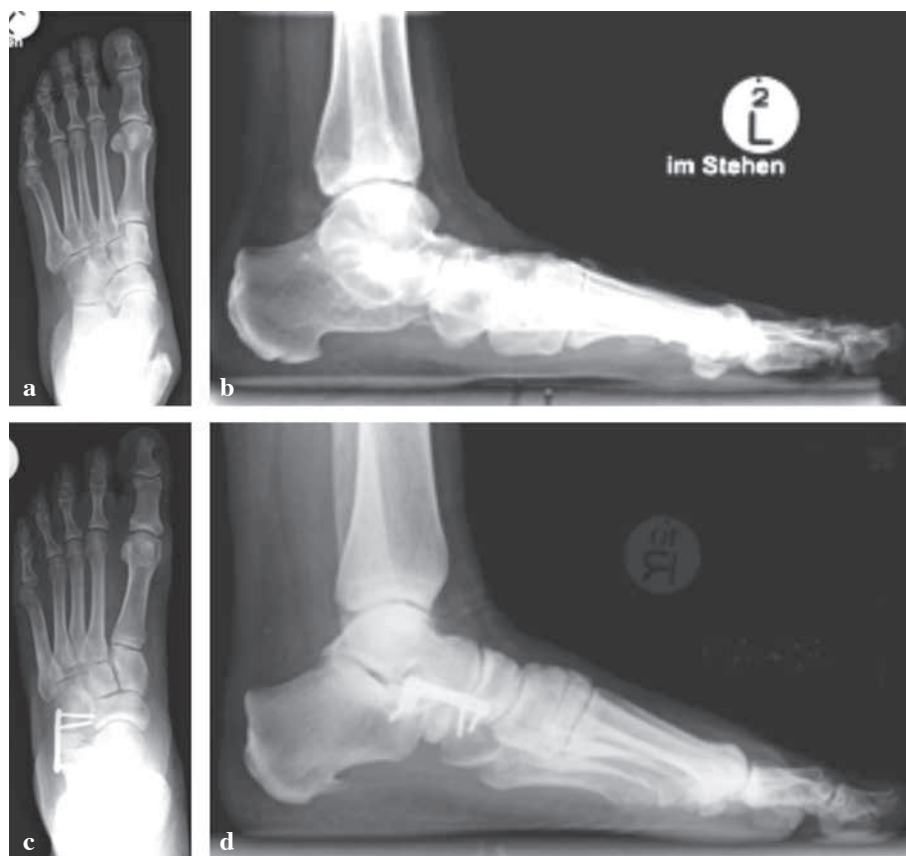Clinical and radiological assessments were performed preoperatively, 8 weeks and one year postoperatively. A long hindfoot view as well as weight bearing dorsoplantar and lateral radiographs were taken (17).

The lateral talometatarsal axis and the navicular floor distance were measured in lateral radiographs and the dorsoplantar talometatarsal axis and talonavicular coverage angle were assessed in dorsoplantar radiographs. Radiographic assessment was performed using the digital measuring system PACS (Picture Archiving and Communication System). Visual analogue pain scale (VAS) and the Hindfoot AOFAS (American Orthopaedic Foot and Ankle Society) score were assessed preoperatively and one year postoperatively. Successful bone healing was diagnosed clinically if local pain was absent during weight bearing, forefoot manipulation and palpation.

Healing of the arthrodesis was assessed according to the criteria of Rush *et al* (19). Failed bone healing was determined with apparent lucency lines and increasing gap as well as increasing sclerosis lines, absent trabecular bone bridges and breakage of the osteosynthesis material. Blurred bony boundaries of the osteotomy, presence of trabecular bone bridges and intact material were signs of successful bone healing.

## RESULTS

The AOFAS score improved from 58.9 ( $\pm 6$ ) points preoperatively to 89.8 ( $\pm 6,3$ ) points 12 months postoperatively. The VAS improved from an average value of 5.1 ( $\pm 1.4$ ) to 0.7 ( $\pm 1$ ) 12 months postoperatively. In accordance to the radiological and clinical definitions for a successful bone healing an osseous fusion of the allograft was



**Fig. 1.** — a,b) Dorsoplantar and lateral weight bearing radiographs show a pes planovalgus deformity ; c, d) Reconstruction of the pes planovalgus by calcaneocuboid distraction arthrodesis with allogenic bone grafting (one year postoperatively).

observed in 11 of 12 cases on average 10 weeks postoperatively.

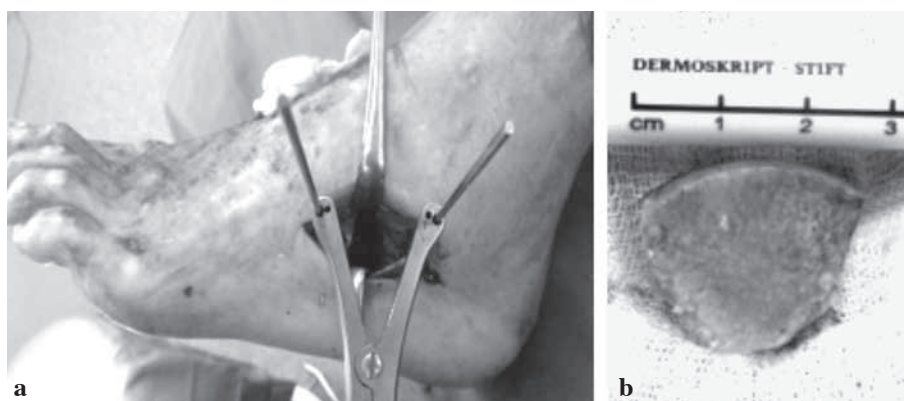
The lateral and dorsoplantar talometatarsal axis were corrected to normal values postoperatively. The navicular floor distance and talonavicular coverage angle improved considerably (Table I). The hindfoot axis decreased significantly from  $8.4^\circ$  ( $\pm 1.4^\circ$ ) to  $4.3^\circ$  ( $\pm 1.4^\circ$ ) valgus on average.

In one case hypaesthesia of the lateral foot was observed without clinical consequence. There was one nonunion with loss of the correction and the need for reoperation. In this patient, a transfer of the flexor digitorum longus tendon and fixation with a lag screw was performed. The revision surgery included a talonavicular arthrodesis and a calcaneocuboid distraction rearthrodesis with an angle stable plate. The patient died unfortunately during the assessment time.

## DISCUSSION

Lengthening of the lateral column of the foot is regarded as an excellent option for pes planovalgus correction (22-24). Interposition of an iliac crest bone graft is usual. Harvesting this bone graft may be associated with a considerable complication rate (14, 20).

In this study an allogenic graft was prepared from harvested femoral heads, which were processed by the Lobator™ technique (Telos GmbH, Marburg, Germany). This processing technique does not significantly affect the mechanical stability and was proven to allow for a more reliable osseous integration compared with autoclaved bone graft (12). Furthermore it was shown that the osteoinductive and osteoconductive properties are preserved (7). The effect of the processing technique on the osteo-



**Fig. 2.** — a) Intraoperative site after preparation and distraction of the calcaneocuboid joint ; b) customised allogenic bone graft

inductive and biomechanical quality of bone grafts has been described previously (1,3,7,21).

The highest biocompatibility is postulated for autologous bone grafts (1,7). However, the availability and quality of autologous bone grafts may be limited because of osteoporosis. In addition the high complication rate has to be considered as a real disadvantage (14,20).

There are few reports on the use of allogenic bone grafts for lateral column lengthening. Grier *et al* showed in their retrospective study a significantly lower rate of nonunion after calcaneocuboid distraction arthrodesis using an allogenic bone graft compared with an iliac crest bone graft in combination with platelet rich plasma (9). The authors concluded to a relative advantage for using an allogenic graft for lateral column lengthening.

In contrast Grunander and Thodarson observed nonunions in 7 of 16 cases after calcaneocuboid arthrodesis with an allogenic femoral head bone graft. The high pseudarthrosis rate was explained by the insufficient rigidity of the fixation with a tubular plate. Therefore, the use of an angle stable plate, which avoids the collapse of the allogenic bone graft was recommended (10).

The higher nonunion rate after calcaneocuboidal arthrodesis in contrast to Evans osteotomy was already reported (23). Toolan *et al* showed the superiority of an angle stable plate compared with a two-screw osteosynthesis (23). The results of other studies also underline the advantages of the use of an angle stable plate. Thomas *et al* observed two

nonunions in 17 patients after calcaneocuboid distraction arthrodesis with iliac crest bone grafts in combination with an angle-stable plate (22). In a similar study Bolt *et al* found three nonunions among 25 calcaneocuboid distraction arthrodeses with an angle-stable plate (2).

Considering these results the high rate of successful bone healing in the present study is explained by the press fit implantation of the allogenic bone graft and the use of an angle stable plate. By experience, the allogenic bone graft from the head-neck junction of the femoral head shows a higher mechanical stability compared with an autologous iliac crest bone graft. This bone graft is characterized by strong and thick cortical bone, which offers the possibility for a press fit implantation without destruction of the graft.

Additionally, it has been shown that an angle-stable plate offers advantages regarding fixation (22-24).

The present study has several limitations. Computed tomography (CT) is regarded as the method of choice to diagnose a successful bone healing (15). However, considering a full weight bearing without pain, a radiological conspicuous bone healing and the lack of a clinical sign of pseudarthrosis following the criteria of this study we saw no indication to perform a CT scan which is associated with a high radiation. A further limitation of the study may be seen in the number of additional corrective forefoot surgeries which were performed to address individual clinical features.

Table I. — Radiological measurement of the dorsoplantar and lateral radiographs preoperatively and one year postoperatively

	Preoperative	Postoperative
Lateral talometatarsal axis	33° (± 4)	4° (± 1)
Dorsoplantar talometatarsal axis	26° (± 5)	2° (± 1)
Talonavicular coverage angle	24° (± 13)	3° (± 1)
Navicular floor distance (mm)	11 (± 2)	29 (± 5)

In conclusion, the use of an allogenic bone graft from the head-neck junction of the femoral head for a calcaneocuboid distraction arthrodesis does not result in a higher nonunion rate compared with the use of an autologous iliac crest graft. It also avoids any donor site morbidity. The use of an angle stable plate for fixation is recommended.

## REFERENCES

- Bauer TW, Muschler GF.** Bone graft materials. An overview of the basic science. *Clin Orthop Relat Res* 2000 ; 371 : 10 - 27.
- Bolt PM, Coy S, Toolan BC.** A comparison of lateral column lengthening and medial osteotomy of the calcaneus for the reconstruction of adult acquired flatfoot. *Foot Ankle Int* 2007 ; 28 : 1115-230.
- Boyce T, Edwards J, Scarborough N.** Allograft bone. The influence of processing on safety and performance. *Orthop Clin North Am* 1999 ; 30 : 571-578.
- Catanzariti AR, Lee MS, Mendicino RW.** Posterior calcaneal displacement osteotomy for adult acquired flatfoot. *J Foot Ankle Surg* 2000 ; 39 : 2-14.
- Dolan CM, Henning JA, Anderson JG et al.** Randomized prospective study comparing tri-cortical iliac crest autograft to allograft in the lateral column lengthening component for operative correction of adult acquired flatfoot deformity. *Foot Ankle Int* 2007 ; 28 : 8-12.
- Funk DA, Cass JR, Johnson KA.** Acquired adult flat foot secondary to posterior tibial-tendon pathology. *J Bone Joint Surg* 1986 ; 68-A : 95-102.
- Gotzen L, v. Garrel T, Hofmann CH.** *Knochenersatz-Aktueller Stand und Perspektiven. Jubiläumsausgabe der Deutschen Gesellschaft für Unfallchirurgie. Teil II : Allgemeine Behandlungsgebiete.* Springer Verlag, Berlin.
- Graves SC, Stephenson K.** The use of subtalar and triple arthrodesis in the treatment of posterior tibial tendon dysfunction. *Foot Ankle Clin* 1997 ; 2 : 319-328.
- Grier KM, Walling AK.** The use of tricortical autograft versus allograft in lateral column lengthening for adult acquired flatfoot deformity : an analysis of union rates and complications. *Foot Ankle Int* 2010 ; 31 : 760-769.
- Grunander TR, Thordarson DB.** Results of calcaneocuboid distraction arthrodesis. *Foot Ankle Surg* 2012 ; 18 : 15-18.
- Johnson KA, Strom DE.** Tibialis posterior tendon dysfunction. *Clin Orthop Relat Res* 1989 ; 245 : 223-227.
- Knaepler H, Garrel T, Gotzen L.** [Investigations on the desinfection and sterilisation of allogenic bone grafts.] (in German). *Heft Unfallheil* 1994 ; 235 : 1-101.
- Kitaoka H B, Kura H, Luo Z-P, An K-A.** Calcaneocuboid distraction arthrodesis for posterior tibial tendon dysfunction and flatfoot. *Clin Orthop Relat Res* 2000 ; 381 : 241-247.
- Lerner T, Griefingholt H, Liljenqvist U.** [Bone substitutes in scoliosis surgery.] (in German). *Orthopäde* 2009 ; 38 : 181-188.
- Martone J, Poel LV, Levy N.** Complications of arthrodesis and nonunion. *Clin Podiatr Med Surg* 2012 ; 29 : 11-18.
- Myerson MS, Badekas A, Schon LC.** Treatment of stage II posterior tibial tendon deficiency with flexor digitorum longus tendon transfer and calcaneal osteotomy. *Foot Ankle Int* 2004 ; 25 : 445-450.
- Reilingh ML, Beimers L, Tuijthof GJM et al.** Measuring hindfoot alignment radiographically : the long axial view is more reliable than hindfoot alignment view. *Skeletal Radiol* 2010 ; 39 : 1103-1108.
- Richter M, Zech S.** Lengthening osteotomy of the calcaneus and flexor digitorum longus tendon transfer in flexible flatfoot deformity improves talo-1st metatarsal-Index, clinical outcome and pedographic parameter. *Foot Ankle Surg* 2013 ; 19 : 56-61.
- Rush SM, Hamilton GA, Ackerson LM.** Mesenchymal stem cell allograft in revision foot and ankle surgery : a clinical and radiographic analysis. *J Foot Ankle Surg* 2009 ; 48 : 163-169.
- Sasso RC, Lehuac JC, Shaffrey C.** Iliac crest bone graft donor site pain after anterior lumbar interbody fusion : a prospective patient satisfaction outcome assessment. *J Spinal Disord Tech* 2005 ; 18 : 77-81.
- Shin S, Yano H, Fukunaga T et al.** Biomechanical properties of heat-treated bone grafts. *Arch Orthop Trauma Surg* 2005 ; 125 : 1-5.
- Thomas RL, Wells BC, Garrison RL, Prada SA.** Preliminary result comparing two methods of lateral column lengthening. *Foot Ankle Int* 2001 ; 22 : 107-119.



- 23. Toolan BC, Sangeorzan BJ, Hansen ST.** Complex reconstruction for the treatment of dorsolateral peritalar subluxation of the foot. *J Bone Joint Surg* 1999 ; 81-A : 1545-1560.
- 24. Trnka HJ, Easley M, Myerson M.** The role of calcaneal osteotomies for correction of adult flatfoot. *Clin Orthop Relat Res* 1999 ; 365 : 50-64.
- 25. van der Krans A, Louwerens JW, Anderson P.** Adult acquired flexible flatfoot, treated by calcaneocuboid distraction arthrodesis, posterior tibial tendon augmentation, and percutaneous Achilles tendon lengthening. A prospective outcome study of 20 patients. *Acta Orthop* 2006 ; 77 : 156-163.