



Does the wedge wing in the neck screw prevent cut-out failure in OTA/AO 31-A2 trochanteric fractures in elderly patients?

Cuneyd GUNAY, Hakan ATALAR, Murat ALTAY, Osman Yuksel YAVUZ,
Ahmet Ozgur YILDIRIM, Ozdamar Fuad OKEN

From Ankara Numune Training and Research Hospital, Ankara, Turkey

The purpose of this retrospective study was to evaluate the effects of Dyna Locking Trochanteric (DLT) nail (U & I Corporation 529-1, Yonghyun-dong, Uijungbu Kyunggi-Do, Korea 480-050) in 31-A1 and 31-A2 intertrochanteric femur fractures. Eighty-seven patients (63 female and 24 male, mean age 77 years) were treated. The mean duration of follow-up was 16.6 ± 3.1 months (range, 12-24 months). There were 36 cases of 31-A1 and 51 cases of 31-A2 fractures. The duration of surgery, fluoroscopy screening time, the blood loss, the hospital stay, the tip-apex distance were significantly less in the 31-A1 fracture group compared with the 31-A2 fracture group ($p < 0.001$). Cut-out was observed in 13 patients (14.9%) above 80 years old with 31-A2 fractures. Especially in elderly patients with unstable 31-A2 fractures, the wedge wing on the neck screw does not work properly. Therefore further biomechanical investigations and also prospective clinical studies with larger series are needed to improve the device.

Key words : Intertrochanteric fractures ; Tip apex distance ; Intramedullary nailing ; Cutting out ; Outcomes ; Complication.

INTRODUCTION

Intertrochanteric femur fractures are one of the most common fractures which represent a major health risk for elderly people. Due to their poor bone quality, it is very difficult to achieve and maintain stable fixation (20). These patients should

be mobilized as soon as possible to prevent complications associated with immobilization (14,23). Several fixation devices have been developed to overcome the difficulties encountered in the treatment but the ideal one is still a matter of debate (5,21).

■ Cuneyd Gunay, MD, Orthopaedic Surgeon.

■ Ahmet Ozgur Yildirim, MD, Orthopaedic Surgeon.

■ Ozdamar Fuad Oken, MD, Orthopaedic Surgeon, Associate Professor.

Department of Orthopaedic Surgery and Traumatology, Ankara Numune Training and Research Hospital, Ankara, Turkey.

■ Hakan Atalar, MD, Orthopaedic Surgeon, Associate Professor.

Department of Orthopaedic Surgery and Traumatology, Gazi University School of Medicine, Ankara, Turkey.

■ Murat Altay, MD, Orthopaedic Surgeon, Associate Professor.

Department of Orthopaedic Surgery and Traumatology, Kecioren Training and Research Hospital, Ankara, Turkey.

■ Osman Yuksel Yavuz, MD, Orthopaedic Surgeon.

Department of Orthopaedic Surgery and Traumatology, Turgut Ozal University School of Medicine, Ankara, Turkey.

Correspondence : Cuneyd Gunay, Department of Orthopaedic Surgery and Traumatology, Ankara Numune Training and Research Hospital, Ulku mah. Talatpasa Bulvarı No : 5, PK : 06100, Altındağ, Ankara, Turkey.

Phone : +90 312 5085101

Fax : +90 312 3114340

E-mail : cuneydgunay@hotmail.com

© 2014, Acta Orthopædica Belgica.

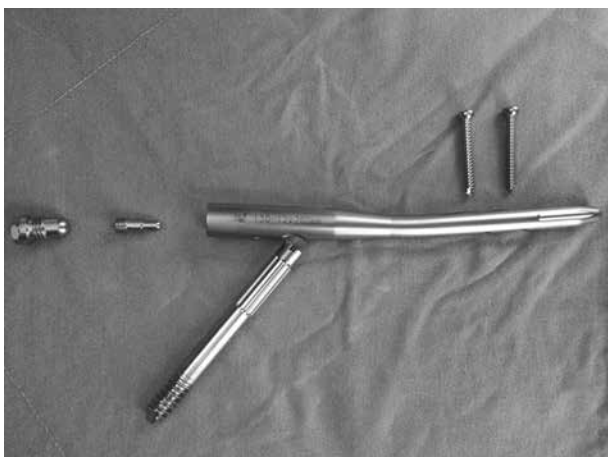

Fig. 1a. — The figure is demonstrating the Dyna Locking Trochanteric Nail, consists of intramedullary nail, neck screw, distal locking screws, fixed nail cap and end cap.

The Dyna Locking Trochanteric (DLT) nail (U & I Corporation 529-1, Yonghyun-dong, Uijungbu Kyunggi-Do, Korea 480-050) is a recent addition to the growing list of intramedullary implants. To the best of our knowledge, no published reports in English literature have systematically assessed the role of the newly developed DLT nail on the basis of a study on a relatively large series. The objective of this study was to evaluate the clinical and radiological outcomes of low velocity intertrochanteric fractures fixed by DLT nail in 31-A1 and A2 fractures with particular emphasis on our experience.

PATIENTS AND METHODS

A single centre multi-surgeon retrospective study was conducted on 95 patients older than 60 years who underwent DLT nail (DLT™ Nail, U & I Corporation 529-1, Yonghyun-dong, Uijungbu Kyunggi-Do, Korea 480-050) (Figs. 1a-b) implantation for intertrochanteric fractures of the femur. Eight patients who died during the 1st postoperative year due to medical complications were not evaluated. A total of 87 patients, 63 female (72.4%) and 24 male (27.6%) with a mean age of 77 years (range, 60-96 years) were available for the outcome analysis. The etiology of all the fractures was a simple fall. The fractures were classified according to the OTA/AO classification system as 31-A (19), and the patients were classified according to the fracture types as Group 1 (31-A1) and Group 2 (31-A2). Thus, 36 patients (41.4%) were classified as 31-A1 and 51 patients (58.6%) as 31-A2



Fig. 1b. — The figure is demonstrating the wedge wings in the neck screw.

fractures. The mean follow-up period was 16.6 ± 3.1 months (range 12-24 months).

All patients underwent surgery as soon as co-morbidities permitted. Spinal anesthesia was used in 75 patients (86.2%), and general anesthesia in 12 patients (13.8%). All patients received one dose of 1 gr cefazoline as prophylaxis. The patient was positioned on an orthopaedic surgical table. Closed reduction was performed under C-arm fluoroscopy in a supine position. Bone grafting was not used. Dynamization was not made in any case.

The DLT nail used in this study was developed in Korea in 2007, and was made from TI alloy (Ti-6Al-4V ELI). The standard operative technique recommended by the manufacturer, as described in detail in instruction manuals, was used. All the study patients had implantation of the 200 mm nail measuring 10 or 11 mm in diameter and with a neck screw angle of 125° .

The time of surgery and total fluoroscopy time were recorded and intraoperative blood loss was measured. Suction drains were not used. Low-molecular-weight heparin was given to all patients starting from admission and for a 6-week period thereafter.

Postoperatively, weight bearing as tolerated was allowed from the day after surgery irrespective of the fracture type. Active quadriceps exercises were started on day 2. Patients were discharged when they were able to walk confidently with assistance.

The position of the neck screw within the femoral head was determined using the method of Cleveland and Bosworth (7) (Fig. 2). The Tip-Apex distance (TAD) was calculated according to the Baumgaertner formula (3). On the post-operative radiographs, the quality of the

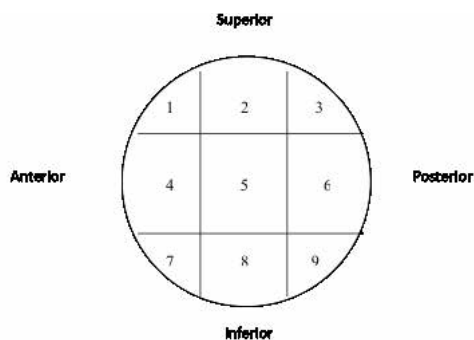


Fig. 2. — Position of the neck screw within the femoral head ; the femoral head is divided into nine zones and enumerated.

fracture reduction was evaluated using Baumgaertner criteria modified by Fogagnolo *et al* (8) (Table I). The neck-shaft angle of the femur was also measured.

Clinical and radiographical examinations were performed at 1, 3, 6 and 12 months postoperatively and every 6 months in the second year. Hip function was assessed according to the Harris Hip Score (HHS) (11).

Results comparing between Group 1 and Group 2 were statistically analyzed using SPSS (Version 13.0 ; SPSS Inc. Chicago, IL, USA). Comparative analysis was performed with the Chi-Square or Fisher's exact (for 2 × 2 tables) test for categorical variables. When distribution was considered to be normal, two sided Student's t-test was performed, otherwise the Mann-Whitney U test was used. A value of $p < 0.05$ was considered statistically significant.

RESULTS

No intraoperative complication was found in either group. There was no early or late infection, no fractures of the femoral shaft or trochanter and no nail breakage was experienced. With the excep-

tion of 13 cut-out complicated fractures, full union of all the other fractures was observed within 3 months postoperatively.

When Group 1 and Group 2 were evaluated according to operation time, blood loss during surgery, TAD, neck-shaft angle, HHS, hospital stay, fluoroscopy screening time and cut-out complication, there was a statistically significant difference in Group 1 in all the above-mentioned parameters (Table II) ($p < 0.001$).

All the cut-out complications (13 patients, 14.9%) were observed in Group 2 within the first 12 weeks after surgery and all required second surgery. Figure 3 demonstrate one of our cut-out complications including the preoperative and postoperative images of an 86 year old woman (Fig. 3a-d). In one patient the nail was exchanged for another DLT nail because of fracture-site fusion and in the remaining patients the nails were removed, and non-cemented partial hip arthroplasty was performed.

Reduction quality was determined as acceptable in 17 patients (19.5%), poor in 7 patients (8%) and good in 63 patients (72.5%). However, cut-out occurred in 5 patients (38.5%) with acceptable, in 7 patients (53.8%) with poor and also in 1 patient (7.7%) with good reduction quality. The reduction quality was statistically significant for the cut-out patients ($p < 0.001$).

According to the zones, three different configurations of cut-out were observed in relation to the primary position of the neck screw. The screws were placed in zone 2 in 5 patients (38.5%), in zone 3 in 6 patients (46.1%) and in zone 5 in 2 patients (15.4%). Blade malposition (zones 2 and 3) was significantly associated with the development of

Table I. — Postoperative evaluation of reduction (8)

Alignment	Anteroposterior plane : Normal collodiaphysial angle or slight valgus Lateral plane : Angulation less than 20°
Displacement of main fragments	More than 80% overlapping in both planes Shortening less than 5mm
Result	Good : Meets both criteria Acceptable : Meets only one criteria Poor : Does not meet both criteria

Table II. — Results according to fracture types

	31-A1	31-A2	P value
Mean duration of surgery	29.1 ± 6.6 min (range 19-51 min)	38.5 ± 5.1 min (range 26-50 min)	P < 0.001
Peroperative fluoroscopy time	38.8 ± 4.9 sec (range 33-59 sec)	53.5 ± 3.4 sec (range 36-52 sec)	P < 0.001
Blood loss	172.4 ± 42.0 ml (range 110-285 ml)	211.2 ± 32.9 ml (range 160-290 ml)	P < 0.001
Hospital stay	4.2 ± 1 days (range 3-7 days)	5.1 ± 1.2 days (range 3-9 days)	P < 0.001
Tip Apex Distance	24 ± 1.5 mm (range 21-28mm)	25.9 ± 1.8 mm (range 22-29 mm)	P < 0.001
Harris Hip Score	86.5 ± 4.7 points (range 76-95 points)	75.4 ± 7.4 points (range 58-87 points)	P < 0.001
Neck-shaft angle	133.3° ± 3.9° (range 128°±144°)	130° ± 4.3° (range 122°±140°)	P < 0.001
Cut-out complication numbers	0	13	P < 0.001

cut-out complication in the patients who had cut-out ($p < 0.001$).

Of the 53 (60.9%) patients with $TAD \leq 25$ mm, 6 patients (11.3%) also had a cut-out. Of the 34 patients (39.1%) with $TAD > 25$ mm, 7 patients (20.6%) had a cut-out. The TAD was not found to correlate with the implant cut-out rate and was not found to be statistically significant ($p = 0.21$).

DISCUSSION

Elderly patients are highly susceptible to postoperative complications, with mortality rates of approximately 30% within 1 year and many more will experience significant functional loss (4). This study evaluated patients with low velocity intertrochanteric fractures. The aim was to assess the DLT nail used on 31-A1 and 31-A2 fractures according to the parameters mentioned in (Table II) and to compare with other intramedullary nails described in literature with regards to cut-out complications.

The DLT device is suitable for both 31-A1 and 31-A2 fractures in respect of operation time, fluoroscopy screening time and blood loss during surgery compared to proximal reconstruction nails (9, 16,17,18,20).

The most serious and destructive hip joint complication is an antero-cranial perforation of a lag screw, such as the cut-out (5,13). This multifactorial complication is related to the contributions applied to the bone, type of fracture, quality of fracture reduction and position of the fixation devices (9,22). The majority of cut-outs in this study had a combination of the critical factors such as non-anatomical reduction, non-optimal lag screw position and the characteristic unstable fracture pattern (Table III).

Careful technique in respect of accurate TAD remains the most important factor in achieving a good result and avoiding implant cut-out. It has been shown that (2,3,10) the TAD is the most valuable factor in determining the likelihood of lag screw cut-out, with a distance of > 25 mm as an indicator of unsatisfactory screw placement and statistically increased rate of cut-out. However, in our study, the TAD was not found to correlate with cut-out complications.

In earlier studies, lag screw cut-out has been reported to range from 8% to 23% (1,3), but with improved surgical technique, failures of fixation have been reported to be as low as 1.6-3% (2,6,15). Lenich *et al.* reported cut-out rates of 14% with proximal femoral nail (PFN), 7% with Gleitnagel, 2.5% with Trochanteric Fixation Nail and 5.7%

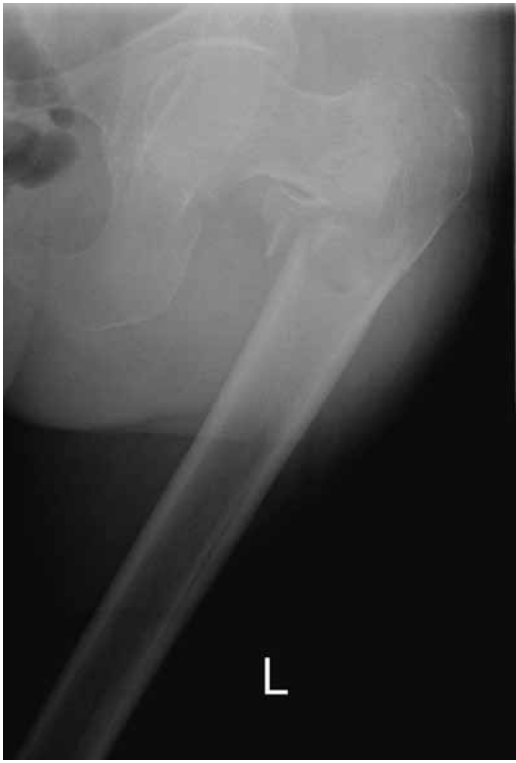

Fig. 3a. — Pre-operative anteroposterior radiograph of the left hip demonstrating 31-A2 intertrochanteric fracture in an 86-year-old woman.

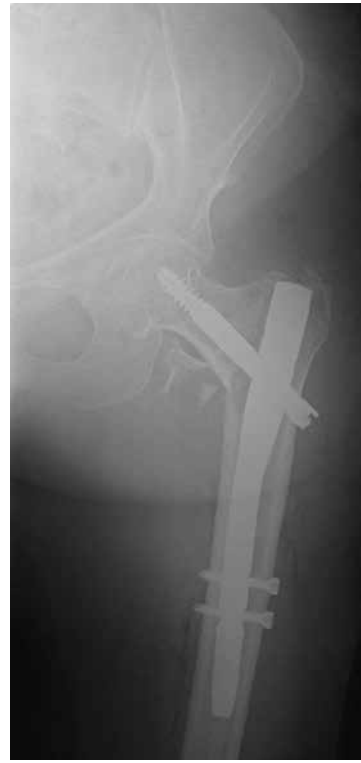

Fig. 3b. — Post-operative anteroposterior radiograph of the same patient treated with DLT nail.

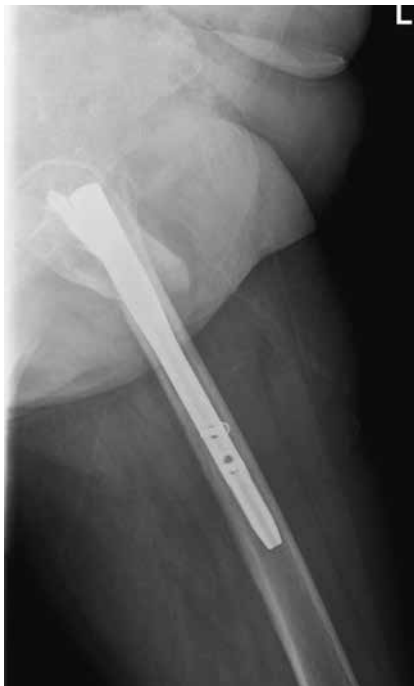

Fig. 3c. — Post-operative lateral radiograph of the left hip.

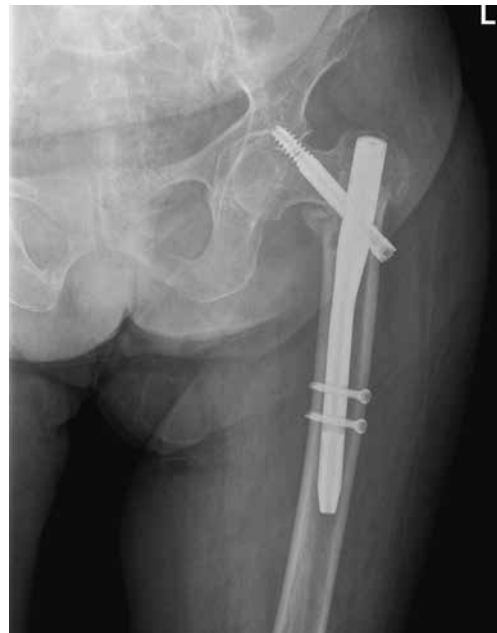

Fig. 3d. — An anteroposterior radiograph of the left hip demonstrating the cut-out of the neck screw at 5 weeks post-operatively.

Table III. — The characteristics of patients with cut-out complication

No	Descriptive Values		Radiological Results				Functional Outcomes
	Age (year)	Fracture Type	TAD (mm)	Zone	NSA (degree)	RQ	HHS (points)
1	82	31-A2	22	3	130°	Poor	78
2	83	31-A2	24	2	125°	Acceptable	64
3	86	31-A2	22	3	125°	Poor	67
4	81	31-A2	28	3	128°	Acceptable	78
5	96	31-A2	24	2	125°	Poor	58
6	88	31-A2	28	2	125°	Acceptable	62
7	85	31-A2	26	3	122°	Good	66
8	88	31-A2	25	3	125°	Acceptable	59
9	89	31-A2	28	2	124°	Poor	64
10	86	31-A2	25	5	128°	Acceptable	62
11	88	31-A2	28	3	126°	Poor	61
12	87	31-A2	27	2	124°	Poor	67
13	91	31-A2	29	5	132°	Poor	65

HHS : Harris Hip Score, RQ : Reduction Quality, NSA : Neck-Shaft Angle, TAD : Tip-Apex Distance.

with Proximal Femoral Nail-Antirotation (16). Herman *et al.* reported a rate of 6.6% cut-out in fractures treated with PFN (12). In the current study, the cut-out rates with DLT nail are much higher than those associated with other implants in literature. Our cut-out rate was 13 out of 51 31-A2 fractures (25%). On the other hand Barton *et al* reported only 5 cut-out complication in 210 31-A2 fractures (2%).

The most possible explanation for our higher cut-out rate was the improper functioning of the wedge wings in the lag screw. This created cut-out complication in elderly patients with unstable 31-A2 fractures. During the operation, the wedge wing in the neck screw was opened to prevent the twisting and the rotation of the screw in the femoral head. Normally wedge wings hold the femoral head more rigidly and also improve axial stability. However, it was thought that in patients with poor bone quality, the wedge wings in the neck screw do not work properly (Figs. 3a-d). In the current study, the majority of the cut-out complications occurred in

the superior quadrant of the femoral head. The cut-out is caused by an eccentric positioning of the lag screw into the femoral head. When the patient starts walking, this becomes a pivot point and the femoral head starts rotating around the wedge wings on the screw.

This study has a number of limitations. The nature of the review was retrospective. The DLT nail device was not compared to other internal fixation systems. More detailed information regarding the bone mineral density of the 13 cut-out patients, using the dual energy x-ray absorpsiometry (DEXA) method, was not available. However, this study is among the first to evaluate this new fixation device. The two year data with no patients lost to follow-up show a high complication rate. According to the findings of this study, DLT nail is a superior implant for 31-A1 fractures compared to 31-A2 fractures (Figs. 4a-d) (Table II).

In this study the cut-out complication was seen to be closely related to the position of the lag screw, reduction quality and unstable fracture pattern. It

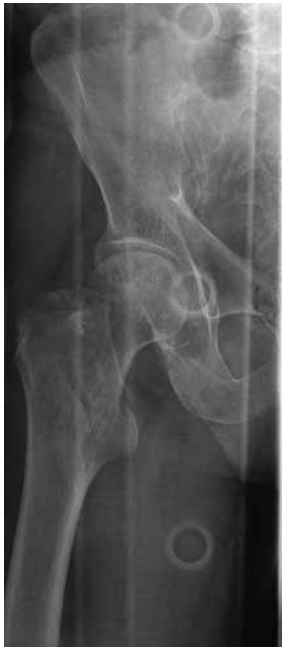

Fig. 4a. — Pre-operative anteroposterior radiograph of the right hip demonstrating 31-A1 intertrochanteric fracture in a 78-year-old man.

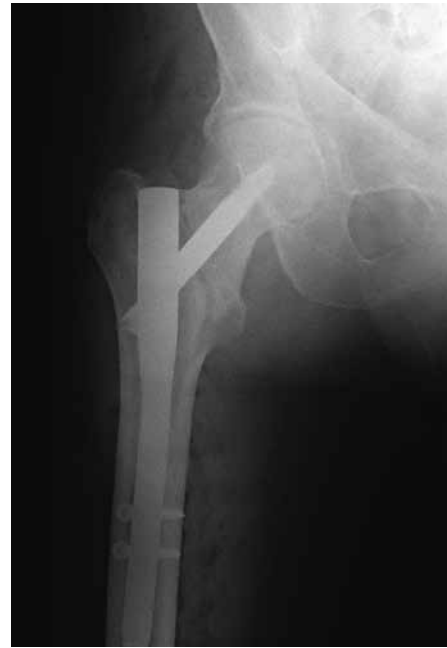

Fig. 4b. — Post-operative anteroposterior radiograph of the same patient treated with DLT nail.

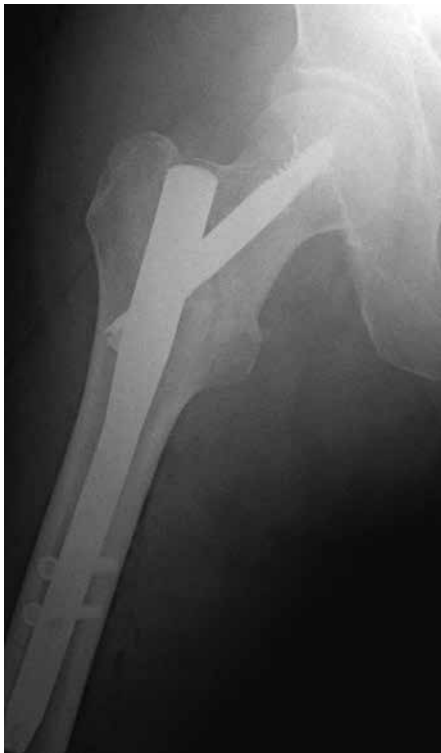

Fig. 4c. — Post-operative lateral radiograph of the same patient's right hip.

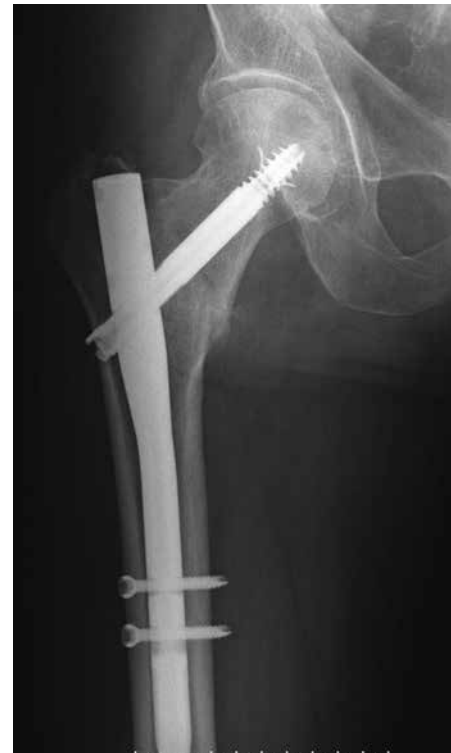

Fig. 4d. — Follow-up anteroposterior radiograph of the same patient's right hip at 3 months postoperatively demonstrating the united fracture with DLT nail.

can therefore be recommended that the lag screw of the DLT nail should be placed in the safe central part of the femoral neck both in AP and lateral views. Limiting weight-bearing postoperatively may additionally reduce the development of this complication especially in unstable fracture patterns in elderly patients. Future biomechanical investigations are needed to elucidate the exact pathophysiological mechanisms of the cut-out of the DLT nail and optimize the implant.

REFERENCES

- Bannister GC, Gibson AG, Ackroyd CE, Newman JH.** The fixation and prognosis of trochanteric fractures. A randomized prospective controlled trial. *Clin Orthop Relat Res* 1990 ; 254 : 242-246.
- Barton TM, Gleeson R, Topliss C, et al.** A comparison of the long gamma nail with the sliding hip screw for the treatment of AO/OTA 31-A2 fractures of the proximal part of the femur : a prospective randomized trial. *J Bone Joint Surg Am* 2010 ; 92 : 792-798.
- Baumgaertner MR, Curtin SL, Lindskog DM, Keggi JM.** The value of the tip-apex distance in predicting failure of fixation of peritrochanteric fractures of the hip. *J Bone Joint Surg Am* 1995 ; 77 : 1058-1064.
- Boonen S, Autier P, Barette M et al.** Functional outcome and quality of life following hip fracture in elderly women : a prospective controlled study. *Osteoporos Int* 2004 ; 15 : 87-94.
- Bridle SH, Patel AD, Bircher M, Calvert PT.** Fixation of intertrochanteric fractures of the femur. A randomised prospective comparison of the gamma nail and the dynamic hip screw. *J Bone Joint Surg Br* 1991 ; 73 : 330-334.
- Chirodian N, Arch B, Parker MJ.** Sliding hip screw fixation of trochanteric hip fractures : outcome of 1024 procedures. *Injury* 2005 ; 36 : 793-800.
- Cleveland M, Bosworth DM, Thompson FR.** Intertrochanteric fractures of the femur ; a survey of treatment in traction and by internal fixation. *J Bone Joint Surg Am* 1947 ; 29 : 1049-1067.
- Fogagnolo F, Kfuri M Jr, Paccola CA.** Intramedullary fixation of pertrochanteric hip fractures with the short AO-ASIF proximal femoral nail. *Arch Orthop Trauma Surg* 200 ; 124 : 31-37.
- Gadegone WM, Salphale YS.** Proximal femoral nail – an analysis of 100 cases of proximal femoral fractures with an average follow up of 1 year. *Int Orthop* 2007 ; 31 : 403-408.
- Geller JA, Saifi C, Morrison TA, Macaulay W.** Tip-apex distance of intramedullary devices as a predictor of cut-out failure in the treatment of peritrochanteric elderly hip fractures. *Int Orthop* 2010 ; 34 : 719-722.
- Harris WH.** Traumatic arthritis of the hip after dislocation and acetabular fractures : treatment by mold arthroplasty. An end-result study using a new method of result evaluation. *J Bone Joint Surg Am* 1969 ; 51 : 737-755.
- Herman A, Landau Y, Gutman G et al.** Radiological evaluation of intertrochanteric fracture fixation by the proximal femoral nail. *Injury* 2012 ; 43 : 856-863.
- Kawaguchi S, Sawada K, Nabeta Y.** Cutting-out of the lag screw after internal fixation with the Asiatic gamma nail. *Injury* 1998 ; 29 : 47-53.
- Kregor PJ, Obrebsky WT, Kreder HJ, Swintkowski MF.** Unstable pertrochanteric femoral fractures. *J Orthop Trauma* 2005 ; 19 : 63-66.
- Lenich A, Mayr E, Rüter A, Möckl Ch, Füchtmeier B.** First results with the trochanter fixation nail (TFN) : a report on 120 cases. *Arch Orthop Trauma Surg* 2006 ; 126 : 706-712.
- Lenich A, Vester H, Nerlich M et al.** Clinical comparison of the second and third generation of intramedullary devices for trochanteric fractures of the hip--Blade vs screw. *Injury* 2010 ; 41 : 1292-1296.
- Liu Y, Tao R, Liu F et al.** Mid-term outcomes after intramedullary fixation of peritrochanteric femoral fractures using the new proximal femoral nail antirotation (PFNA). *Injury* 2010 ; 41 : 810-817.
- Macheras GA, Koutsostathis SD, Galanakos S, Kateros K, Papadakis SA.** Does PFNA II avoid lateral cortex impingement for unstable peritrochanteric fractures? *Clin Orthop Relat Res* 2012 ; 470 : 3067-3076.
- Marsh JL, Slongo TF, Agel J et al.** Fracture and dislocation classification compendium – 2007 : Orthopaedic Trauma Association classification, database and outcomes committee. *J Orthop Trauma* 2007 ; 21 : S1-133.
- Pu JS, Liu L, Wang GL, Fang Y, Yang TF.** Results of the proximal femoral nail anti-rotation (PFNA) in elderly Chinese patients. *Int Orthop* 2009 ; 33 : 1441-1444.
- Radford PJ, Needoff M, Webb JK.** A prospective randomised comparison of the dynamic hip screw and the gamma locking nail. *J Bone Joint Surg Br* 1993 ; 75 : 789-793.
- Sommers MB, Roth C, Hall H et al.** A laboratory model to evaluate cutout resistance of implants for pertrochanteric fracture fixation. *J Orthop Trauma* 2004 ; 18 : 361-368.
- Tyllianakis M, Panagopoulos A, Papadopoulos A, Papisimos S, Mousafiris K.** Treatment of extracapsular hip fractures with the proximal femoral nail (PFN) : long term results in 45 patients. *Acta Orthop Belg* 2004 ; 70 : 444-454.