



## Comparison of Proximal Turndown of Central slip Combined with Suture of Lateral Bands Versus Free Tendon Grafting for Central Slip Reconstruction after an Open Finger Injury

Ying LI, Aizhong Ding, Zhimin HE, Feng XUE

*From the South institute of 6<sup>th</sup> People Hospital, shanghai China*

We randomized patients with open finger injury and central slip insertion defects into a proximal turndown group (final n = 28) and a palmaris longus tendon graft group (final n = 20). In the proximal turndown group, the dorsal central slip of the extensor tendon in the proximal phalanx was split, leaving it attached distally. We turned the strip from proximal to distal and fixed it using the distal joint capsule of the proximal interphalangeal joint as the distal insertion of reconstruction, and the extended central slips were then fixed to the middle phalanx. The dorsal traumatic central slip was stitched with lateral bands using 2-0 suture to form a new conjoint tendon. The injured central slip in the comparison group was sutured using autogenous palmaris longus tendon and fixed in drilled holes in the middle phalanx. Outcomes assessment was performed according to Dargan's criteria during postoperative follow-up. Motion range in the proximal turndown group was significantly greater than in the graft group ( $p < 0.05$ ). We observed no boutonniere deformity in both the proximal turndown and graft group.

**Keywords :** extensor tendon, central slip insertion defects, lateral bands suture, palmaris longus tendon graft, joint capsule.

### INTRODUCTION

Central slip defects of the extensor tendon are common injuries that require an early diagnosis and surgical intervention in the context of an open injury (4,11). The extensor tendon is superficial, and

damage to the extensor central slip causes intrinsic mechanical imbalance. Delayed treatment may lead to complications such as the boutonniere deformity (19). A number of methods, including palmaris longus tendon grafting (13) and mini bone anchors, have been used in the repair of the damaged central slip insertion, depending on the type of tendon injuries (3,16,21). In recent years, mini-anchors have been widely used in the repair of tendon injury and provided positive outcomes (8,14). In certain conditions, a direct repair is preferable since there is no tendon harvest, thus decreasing pain and discomfort to the patient. However, the direct repair is not always possible, for example if there is significant scarring.

The purpose of the present study was to compare the surgical outcomes of two techniques used for open injuries in the acute setting to repair a damaged extensor central slip the palmaris longus tendon grafting and a new technique, the proximal

- 
- Ying Li, MD.
  - Aizhong Ding, MD.
  - Zhimin He, MD.
  - Feng Xue, MD.

*South institute of 6<sup>th</sup> People Hospital, shanghai China.*

Correspondence : Feng Xue South institute of 6<sup>th</sup> People Hospital, Shanghai 200233, China

E-mail : nature524688@163.com; Fxgkxf@163.com;

Running line : Repair of Central slip Insertion

© 2014, Acta Orthopædica Belgica.

---

turndown of the central slip combined with suture of lateral bands.

## MATERIALS AND METHODS

From February 2009 to February 2010, 48 cases of central slip defect (0.6 to 1.2 cm, mean of 0.94 cm) of the extensor tendon underwent surgical treatment. All patients suffered from an open finger injury resulting from a trauma leaving an unclean tendon laceration, and all patients had some residual stump remaining at the original slip attachment. Patients were excluded in cases of complete laceration or rupture, so there was some tissue left at the distal end of the proximal interphalangeal joint capsule. They were randomized into a comparison group and a proximal turndown group by drawing lots. The central slip insertion defect in the graft group was repaired with palmaris longus tendon grafting, while the insertion defect in the proximal turndown group was reconstructed by the proximal turndown of the split central slip combined with lateral bands suture. However, because these injuries occurred after an accident, some patients were followed-up in another part of the country and were then lost to follow-up, leading to a disparity in the final number of patients between the two groups. There was no difference in the central slip defect between the two groups (proximal turndown:  $0.93 \pm 0.21$  vs. graft:  $0.94 \pm 0.20$  cm,  $p > 0.05$ ).

There were 28 patients (28 injured fingers) in the proximal turndown group, including 20 (males and 8 females), aged from 10 to 42 ((mean of 31 (years). All patients underwent surgery 1 to 6 (hours after injury. There were 12 cases of index fingers, seven middle fingers, six ring fingers and three little fingers. No extensor tendon avulsion fracture was observed during the preoperative X-ray examination.

The palmaris longus tendon graft group (comparison) consisted of 20 patients (20 injured fingers), including 15 males and 5 females, aged from 23 to 44 ((mean of 34 years). There were 11 index fingers, three middle fingers, four ring fingers and two little fingers. Patients from this group underwent surgery 0.5 to 6 hours after the injuries. No patient had an extensor tendon avulsion fracture, according to X-ray examinations.

### Surgical Procedures

Patients received an infiltration anesthesia in the roots of injured fingers. In the proximal turndown group, after debridement and exploration, we performed a proximal turndown of the dorsal residual proximal central slip of

the proximal phalanx, retaining the distal end of the proximal interphalangeal joint capsule as the distal insertion for reconstruction. We split the extensor tendon proximal to the trifurcation into the central and lateral slips and took a strip, leaving it attached proximally and turning it down from proximal to distal. We straightened the injured finger, polished the cortical bone of middle phalanx, and drilled 1-2 parallel holes for support in the distal joint capsule on the dorsal side using 1.5-mm K-wires. We fixed the inverted central slip in the middle phalanx using 1.5 mm poly-L-lactide bio-absorbable pins of appropriate length. The newly formed tendon insertion was strengthened by closing the defect in the adjacent lateral bands using 2-0 suture (Johnson & Johnson, New Brunswick, NJ, United States), preventing the new tendon insertion to slip from the pins (Fig. 1C and Fig. 2). We passively flexed the proximal interphalangeal joint to ensure that there was no gaping at the repair site, or undue stress on the reconstruction.

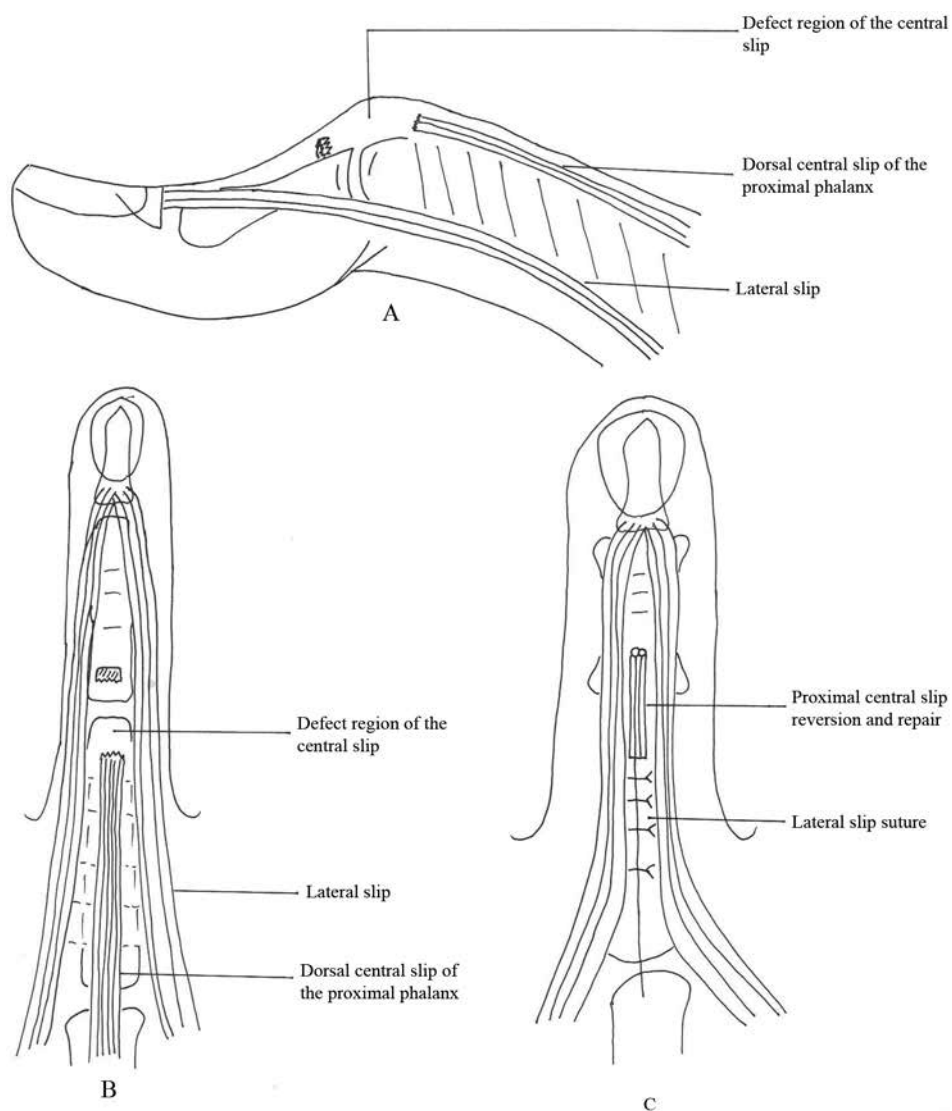
For the palmaris longus tendon grafting group, the proximal extensor tendon was exposed, the proximal interphalangeal joint was kept in dorsal extension, transfixed with a 1-mm Kirschner wire. The proximal extensor tendon was fully freed to ensure an adequate excursion. The palmaris longus tendon was harvested in corresponding length from the wrist to suture the central slip with 2-0 sutures (Johnson & Johnson, New Brunswick, NJ, United States), using Kessler's technique.

### Postoperative treatment

For the proximal turndown group, the injured fingers were immobilized, keeping the proximal interphalangeal joint in extension and the distal interphalangeal joint in hyperextension. After postoperative splinting for 4 weeks, the injured fingers gradually underwent functional exercises.

For the palmaris longus tendon grafting group, splinting was removed 4 weeks after surgery and the Kirschner wires were pulled out. The patients performed functional exercise through active flexion of the distal interphalangeal joints.

Injured finger's function was evaluated according to Dargan's criteria (5), by measuring and summing the angles of flexion and extension lags of metacarpophalangeal joint, proximal interphalangeal joint and distal interphalangeal joint, and the distance between fingertips to palm. Finger function was graded according to: 1) excellent: no extension lag, and fingertips went over palmar crease when the fingers was flexed; 2) good: extension lag was  $\leq 15^\circ$ , and the fingertips could come



**Fig. 1.** — Schematic representations of the central slip defect and repair procedure. A : sagittal view. B : coronal view. C : schematic representation of the repair

up to palmar crease ; 3) fair : extension lag was  $16^{\circ}$  to  $45^{\circ}$ , and the distance between fingertips and palmar crease was  $< 2$  cm ; and 4) poor : extension lag was  $> 45^{\circ}$ , and the distance between fingertips and palmar crease was  $> 2$  cm.

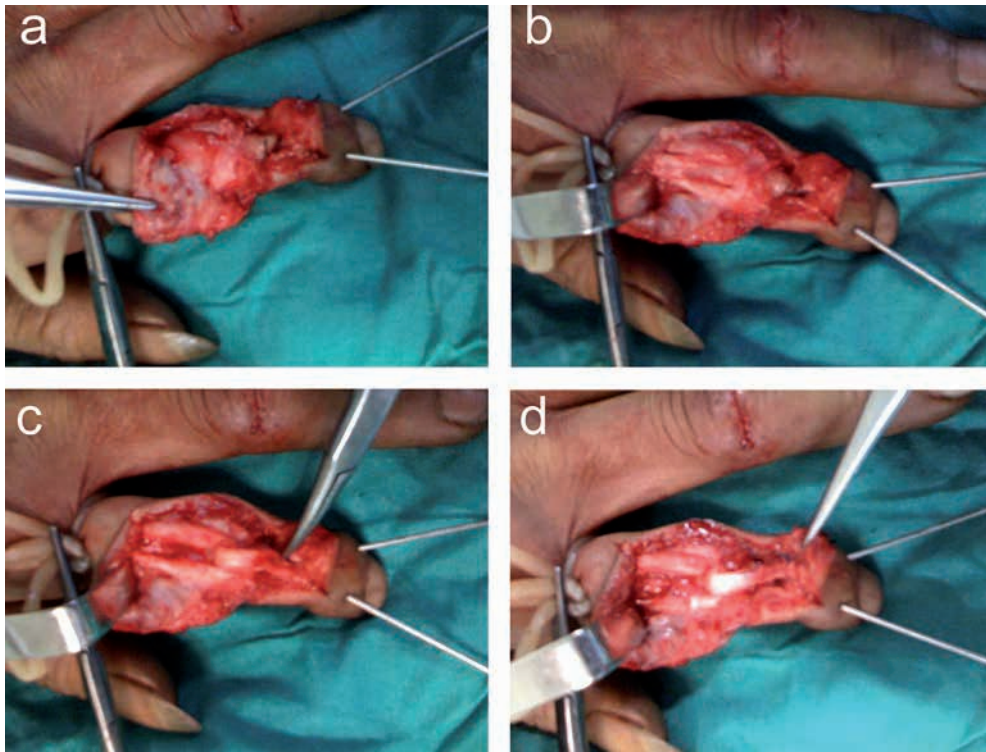
### Statistical analysis

The present study was an observational study, and no power analysis was performed, since no data was available for the proximal turndown group to base the power

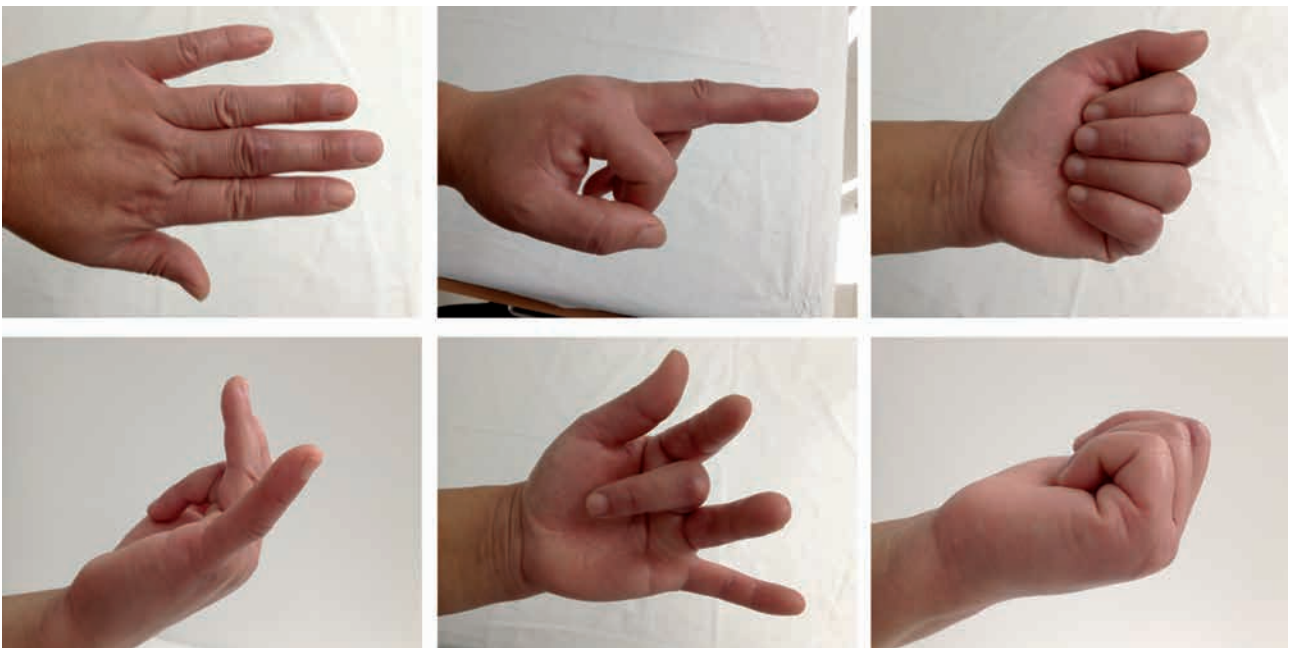
analysis. Data were presented as mean  $\pm$  standard deviation using descriptive statistics. Categorical variables in the two groups were tested using the Student's t-test. SPSS (SPSS Inc., Chicago, IL, USA) was used for all statistical analyses. A p-value  $< 0.05$  was considered statistically significant.

### RESULTS

Fingers in the 28 patients in the proximal turndown group were assessed after a mean of 10.5



**Fig. 2.** — Proximal turndown of the central slip combined with lateral bands suture to repair central slip insertion defect. A : The fracture line of middle phalanx and central slip insertion defect of extensor. B : The proximal end of central slip is being reversed to cover the defect area. C : The extended central slip with distal tendon is fixed. D : Finally, the lateral bands are sutured with the central slip to form a tendon combination.



**Fig. 3.** —

months after surgery. According to Dargan's criteria, 26 patients showed excellent results and two cases showed good results, indicating surgical success in all cases (100%). No boutonniere deformity was observed during follow-up (Table I).

Fingers in the 20 patients from the palmaris longus tendon grafting group were assessed after a mean of 12.2 months after surgery. According to Dargan's criteria, results were excellent in 10 cases, good in five cases, fair in four cases and poor in one case. The overall success rate was 70%. One case developed boutonniere deformity after surgery (Table I). There was a significant difference in the surgical outcomes assessed using Dargan's methods between the two techniques (proximal turndown vs. grafting,  $p < 0.05$  using Chi-square test, Table I).

In the palmaris longus tendon grafting group, mean proximal interphalangeal joint flexion after surgery was  $75^\circ$  and the mean tip-to-palm distance was 3.5 cm. In the proximal turndown group, mean proximal interphalangeal joint flexion after surgery was  $85^\circ$  and the mean tip-to-palm distance was 1.5 cm.

## DISCUSSION

A number of surgical approaches have been described for the reconstruction of the extensor central slip. A number of authors advocated the use of tendon grafts (10,18,20). However, these techniques require the harvesting of a tendon graft and require

a particular surgical care to allow full graft attachment. The use of lateral bands to restore the extensor function at the proximal interphalangeal joint was proposed by Matev in 1964 (7). Further modifications were used to prevent volar migration (12). However, these techniques led to variable long-term outcomes. A study using a distally-based flexor digitorum superficialis slip showed promising results (1). A biochemical study by Mercer et al. (8) compared the Swanson's approach with an approach consisting in simply closing the split in the extensor mechanism without bone reattachment. Their results show that both approaches preserved the function of the extensor mechanism. However, the use of bone anchors has been shown to be a good approach for the fixation of soft tissues to bones (3,14). Another biomechanical study compared the number of cross-stitches used in Becker repair: extensor tendon repair using one cross-stitches provided superior mechanical properties than the use of two or three cross-stitches (2). A study using an hemilateral band technique for the reconstruction of gap defects in the terminal slip of extensor tendons showed good surgical outcomes (15). However, none of these studies used the same surgical technique as the one used in the present study, preventing any direct comparison. However, we used some aspects of these techniques in order to reach an optimal surgical approach. Because of their high cost, we replaced bone anchors with bio-absorbable pins.

Table I. — Postoperative functional assessment of injured fingers according to Dargan's classification

	Proximal turndown group	Palmaris longus tendon grafting group	P-value
<b>Excellent</b>	26	10	< 0.0
<b>Good</b>	2	5	
<b>Fair</b>	0	4	
<b>Poor</b>	0	1	
<b>Total</b>	28	20	
<b>PIP joint flexion, mean</b>	$85^\circ$	$75^\circ$	< 0.0
<b>Tip-to-palm, mean</b>	1.5 cm	3.5 cm	< 0.0

PIP : proximal interphalangeal.

Categorical data were analyzed using the Chi-square test. Continuous variables were tested using the Student's t-test.

The main postoperative complication is the boutonniere deformity caused by tendon defects and tendon adhesions (11). Because central slip insertion defects disrupt the continuity of the extensor tendon, which is separated by only a small amount of loose tissue from bone and skin, the tendon is therefore susceptible to adhesions (11). In our surgical method of proximal turndown of central slip combined with lateral bands suture, the longitudinal tendon bundle is continuous with only one anastomosis, and there are solid absorbable pins at the central slip insertion for bone fixation. After combination of proximal residual central slip and lateral bands, the central slip can deliver longitudinal extensor force through the combined lateral bands. On the other hand, with the help of the central slip, the lateral bands attenuate the transverse tension, which effectively prevents the avulsion of combined lateral bands. Therefore, compared to tendon grafting, the proximal turndown of the central slip combined with lateral bands suture can effectively avoid secondary damage to the central slip. In addition, an early functional recovery through exercise of the injured fingers is more likely.

All patients received local anesthesia during the procedure; they were then able to flex and extend fingers actively on command to adequately adjust the tendon tension to the best status, avoiding postoperative extension or flexion limitations (6).

For a successful surgery, we suggest: 1) measuring the length and width of the split central slip (the split central slip spanned from the middle of the middle phalanx to the proximal end of the proximal phalanx, with a width of about 1 cm). 2) The combined lateral bands should hang over the dorsal side of the proximal interphalangeal joint and any transverse tension should be avoided. 3) When the lateral bands are combined and sutured with the central slip, the injured fingers were required to passively flex and extend. The extension should achieve, and the fingertips should reach the palm. If the fingers do not meet these criteria, inappropriate suture tension should be re-adjusted. 4) In order to avoid iatrogenic adhesions affecting tendon excursion, the lateral bands should not be sutured to other deep tissue, or the central slip should not be sutured with its original insertion or joint capsule. 5) To prevent

postoperative adhesions, attention should be paid to protect the loose connective tissue below the aponeurosis, and the integrity of the periosteum and joint capsule during sharp separation.

In fact, our technique has some similarities with Snow's (9). Snow described a method in which a portion of the uninjured central tendon that overlies the proximal phalanx is incised and flapped distally to fill the defect over the PIP joint. In the present study, we used an anterior transfer of the central slip combined with lateral bands suture. In addition, the fixation method is different, since we used bioabsorbable pins to fix the extended central slip to the middle phalanx.

Many previous studies used Strickland's criteria to assess digits' function after tendon repair (17). However, Dragan's criteria can also be used to reflect the surgical efficacy (5).

In conclusion, we reported a novel approach to repair and reconstruct traumatic central slip insertion defects following an open injury, using proximal turndown of the central slip combined with lateral bands suture. Compared to palmaris longus tendon grafting, this method improves the suture strength of the combined tendon bundle, leading to the functional recovery of the extensor, reducing postoperative complications and improving the surgical success rate.

## REFERENCES

1. **Ahmad F, Pickford M.** Reconstruction of the extensor central slip using a distally based flexor digitorum superficialis slip. *J Hand Surg Am* 2009 ; 34 : 930-932.
2. **Chung KC, Jun BJ, McGarry MH, Lee TQ.** The effect of the number of cross-stitches on the biomechanical properties of the modified becker extensor tendon repair. *J Hand Surg Am* 2012 ; 37 : 231-236.
3. **Cluett J, Milne AD, Yang D, Morris SF.** Repair of central slip avulsions using Mitek Micro Arc bone anchors. An in vitro biomechanical assessment. *J Hand Surg Br* 1999 ; 24 : 679-682.
4. **Elson RA.** Rupture of the central slip of the extensor hood of the finger. A test for early diagnosis. *J Bone Joint Surg Br* 1986 ; 68 : 229-231.
5. **Ip WY, Chow SP.** Results of dynamic splintage following extensor tendon repair. *J Hand Surg Br* 1997 ; 22 : 283-287.
6. **Lee SW, Chen H, Towles JD, Kamper DG.** Effect of finger posture on the tendon force distribution within the

- finger extensor mechanism. *J Biomech Eng* 2008 ; 130 : 051014.
7. **Matev I.** Transposition of the Lateral Slips of the Aponeurosis in Treatment of Long-Standing "Boutonniere Deformity" of the Fingers. *Br J Plast Surg* 1964 ; 17 : 281-286.
  8. **Mercer D, Fitzpatrick J, Firoozbakhsh K, Carvalho A, Moneim M.** Extensor tendon repair with and without central slip reattachment to bone: a biomechanical study. *J Hand Surg Am* 2009 ; 34 : 108-111.
  9. **Merrell G, Slade J** Dislocations and ligament injuries in the digits. In : S Wolfe, R Hotchkiss, W Pederson, S Kozin (Eds.), *Green's Operative Hand Surgery, 5<sup>th</sup> edition*. London : Churchill Livingstone, 2005 ; p. 308.
  10. **Nichols HM.** Repair of extensor-tendon insertions in the fingers. *J Bone Joint Surg Am* 1951 ; 33-A : 836-841.
  11. **Nugent N, O'Shaughnessy M.** Closed central slip injuries - a missed diagnosis ? *Ir Med J* 2012 ; 104 : 248-250.
  12. **Ohshio I, Ogino T, Minami A, Kato H.** Reconstruction of the central slip by the transverse retinacular ligament for boutonniere deformity. *J Hand Surg Br* 1990 ; 15 : 407-409.
  13. **Pulvertaft RG.** Tendon grafting for the isolated injury of flexor digitorum profundus. *Bull Hosp Jt Dis Orthop Inst* 1984 ; 44 : 424-434.
  14. **Rehak DC, Sotereanos DG, Bowman MW, Herndon JH.** The Mitek bone anchor: application to the hand, wrist and elbow. *J Hand Surg Am* 1994 ; 19 : 853-860.
  15. **Savvidou C, Thirkannad S.** Hemilateral band technique for reconstructing gap defects in the terminal slip of the extensor tendon. *Tech Hand Up Extrem Surg* 2011 ; 15 : 177-181.
  16. **Snow JW.** A method for reconstruction of the central slip of the extensor tendon of a finger. *Plast Reconstr Surg* 1976 ; 57 : 455-459.
  17. **Strickland JW, Glogovac SV.** Digital function following flexor tendon repair in Zone II: A comparison of immobilization and controlled passive motion techniques. *J Hand Surg Am* 1980 ; 5 : 537-543.
  18. **Suzuki K.** Reconstruction of post-traumatic boutonniere deformity. *Hand* 1973 ; 5 : 145-148.
  19. **Towfigh H, Gruber P.** Surgical treatment of the boutonniere deformity. *Oper Orthop Traumatol* 2005 ; 17 : 66-78.
  20. **Weeks PM.** The chronic boutonniere deformity: a method of repair. *Plast Reconstr Surg* 1967 ; 40 : 248-251.
  21. **Yoshino N, Watanabe N, Fujita N, Fukuda Y, Yamashita T, Fujiwara H.** Boutonniere deformity of the second toe after planter dislocation of proximal interphalangeal joint : a case report. *Arch Orthop Trauma Surg* 2009 ; 129 : 1527-1529.