



Treatment of mallet fracture using a percutaneous fixation technique with an 18-gauge needle

Eun young RHA, Min cheol LEE, Jung ho LEE, Suk ho MOON, Jong won RHIE, Deuk young OH

From Department of Plastic and Reconstructive Surgery, The Catholic University of Korea

The purpose of this paper is to introduce a simple and intuitive treatment method using an 18-gauge needle for mallet fractures that involve more than one-third of the articular surface.

We performed a retrospective review of 17 patients who underwent closed reduction using an 18-gauge needle with transfixation of Kirschner wire between March 2007 and October 2013. According to the Wehbe and Schneider classification, 15 cases were type IB, 1 was type IIB, and 1 was type IIC. The mean size of bony fragments at the time of injury was 53 percent of the articular surface of the distal phalanx. According to Crawford's criteria, 6 of 17 patients had an excellent result, 9 had a good result and 2 had fair results. Our method of percutaneous reduction using an 18-gauge needle with transfixation of Kirschner wire is minimally invasive and is useful for the fixation of mallet fractures.

Keywords : mallet fracture ; closed reduction ; needle.

to surgical intervention. Although, surgical correction is indicated for an intra-articular fracture involving more than 30% of the articular surface or a fracture with volar subluxation of the DIP joint to prevent complications such as DIP joint dysfunction, persistent pain, aesthetic disfigurement, premature osteoarthritis, stiffness or swan neck deformity, the standard treatment modality remains controversial (1,6,24,28,29). Moreover, in fractures with small phalangeal bone fragments, accurate reduction and stable fixation are challenging, and various surgical complications can develop (21).

We present a simple and minimally invasive method that uses an 18-gauge needle for percutaneous fixation of mallet fractures.

INTRODUCTION

A mallet fracture is a disruption of the terminal extensor mechanism due to bony avulsion of the distal phalanx base. Mallet fractures result from forced flexion of the extended distal interphalangeal joint (DIP) (7). This fracture commonly occurs as a result of work or domestic-related tasks and sports activities (20). To date, various treatment options have been reported, from conservative management

- Eun young Rha, MD, Clinical Fellow.
- Min-chel Lee, MD, Chief Resident.
- Jung ho Lee, MD, PhD, Assistant Professor.
- Suk ho Moon, MD, Clinical Assistant Professor.
- Jong won Rhie, MD, PhD, Professor.
- Deuk young Oh, MD, PhD, Associate Professor.

Department of Plastic and Reconstructive Surgery, The Catholic University of Korea.

Correspondence : Deuk Young Oh, Department of Plastic Surgery, Seoul St. Mary's hospital, The Catholic University of Korea, 505 Banpo-dong, Seocho-gu, Seoul, 137-701, Republic of Korea. E-mail : ohdeuk1234@hanmail.net

© 2015, Acta Orthopædica Belgica.

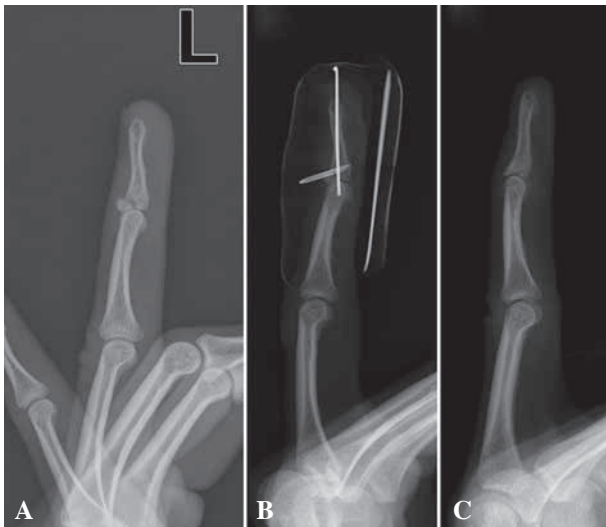


Fig. 1. — A 33-year-old male with a mallet fracture of the left ring finger. (A) Preoperative X-ray of the type IB mallet fracture. (B) The X-ray 1 week after surgery shows well-maintained reduction without displacement. (C) The X-ray 2 months after surgery shows complete bony consolidation.

PATIENTS AND METHODS

We performed a retrospective review of the medical records of patients who had undergone closed reduction for mallet fracture by using an 18-gauge needle and Kirschner wire at Seoul St. Mary's Hospital between March 2007 and October 2013. The indications for surgery in this study included a fracture that involved more than 30% of the joint surface and volar subluxation of the distal phalanx.

In total, 17 patients (12 males and five females) were included in this study, with ages ranging from 15 to 50 years with a mean age of 32.3 years. All patients had a fracture of one finger. The ring finger was the most commonly affected (ten cases) (Fig. 1A, 1B), followed by the middle finger (five cases) (Fig. 2A, 2B) and little finger (two cases). The causes of injury were sport (nine cases), door crushing (six cases) and fighting (two cases). The mean time between injury and surgery was 6.3 days.

We classified all mallet fractures according to the Wehbe and Schneider classification and recorded the size and displacement of fracture fragments as a percentage of the anteroposterior diameter of the base of the distal phalanx on a lateral radiograph (30).

The follow-up period ranged from 2 to 12 months. Complications and bony union were evaluated by a clini-

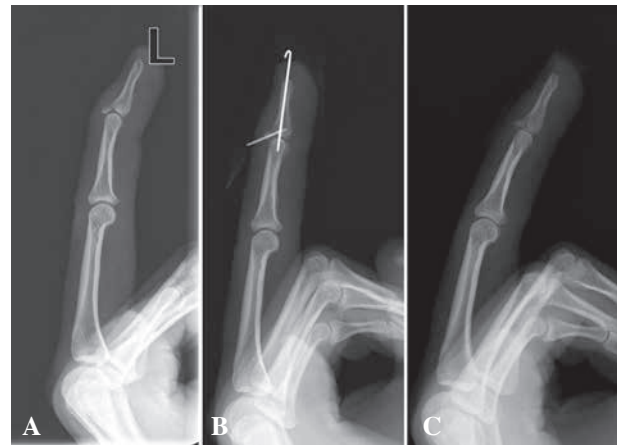


Fig. 2. — A 25 year-old-male with a mallet fracture of the left middle finger. (A) Preoperative X-ray of the type IB mallet fracture. (B) The X-ray immediately after surgery shows reduction state without displacement. (C) The X-ray 3 weeks after surgery shows well-maintained reduction after removal of the needle and Kirschner wire.

cal examination and weekly radiographs. Functional outcomes were evaluated using Crawford's criteria (5).

Under digital nerve block anaesthesia, an 18-gauge needle was introduced into the bony fragment while the DIP and proximal interphalangeal joint (PIP) were held in 20° flexion (Fig. 3A). Under lateral-view fluoroscopic imaging, we inserted the needle through the bony fragment from the dorsal to the palmar side, performing a reduction of the fracture fragment, while a malleable retractor or the reverse side of a knife handle was applied on the volar side of the DIP joint for counter-traction by using the opposite thumb and index finger (Fig. 3B). Then, a 0.9-mm Kirschner wire was inserted longitudinally for DIP joint fixation with extension of the distal phalanx (Fig. 3C, 3D). All procedures were performed under fluoroscopic imaging (Fig. 4). The needle and wire were cut short and the exposed opening of the needle was closed to prevent infection. At the end of the operation, an aluminium splint was applied.

RESULTS

According to the Wehbe and Schneider classification, 15 cases were type IB, one case was type IIB, and one was type IIC (Table I). The mean size of the bony fragment at the time of injury was 53 percent of the articular surface of the distal phalanx.

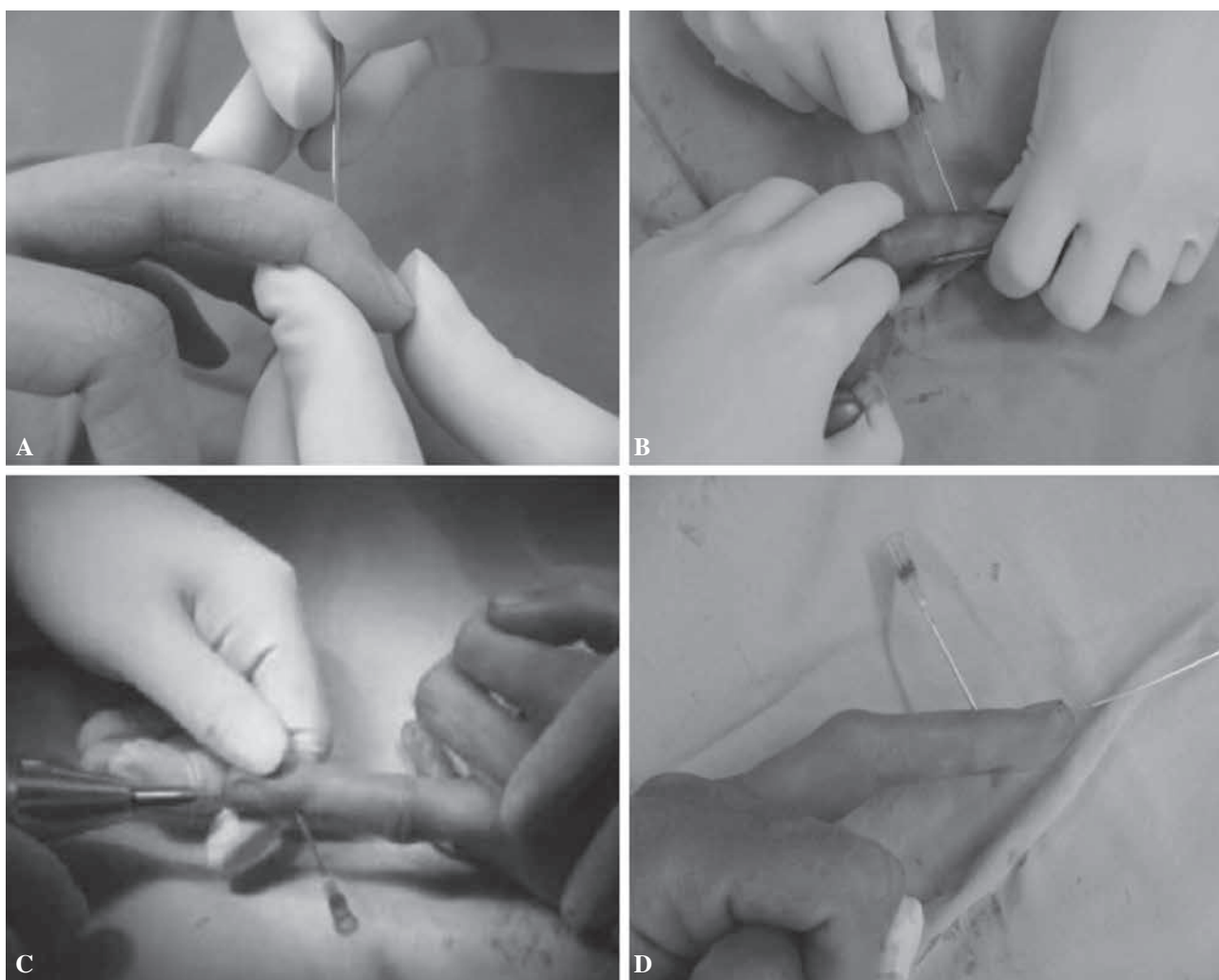


Fig. 3. — Operative technique. (A) Insertion of an 18-gauge needle and palpation of the bony fragment was performed with 20° flexion position of the DIP joint. (B) The 18-gauge needle was passed through the bony fragment while the DIP joint was pulled and extended for reduction. (C) A 0.9-mm Kirschner wire was driven from the volar side of the distal phalanx crossing the DIP joint to hold it in extension. (D) The final result.

The mean duration of maintenance of the 18-gauge needle and Kirschner wire was 22 days. After the needle and wire had been removed, active and passive exercise of the DIP joint was performed in all patients for 10 min per hour. The duration of splint application averaged 17.5 days (range, 12-23 days).

All fractures achieved complete bony consolidation (Fig. 1C, 2C). The time from injury to radiologic union averaged 32.2 days (range, 27-45 days). There were no cases of complications, such as comminution of the fracture fragment, nail deformity,

pin tract infection, cold intolerance, instability, or dislocation of the DIP joint during the long-term follow-up period of 15 months.

The mean extensor lag of the DIP joint at the time of injury was 16.7° (range, 5°-30°). The postoperative extensor lag improved by up to 5° in six patients, 8° in two patients and 10° in four patients. The remaining five patients achieved full extension postoperatively.

According to Crawford's criteria, six patients had excellent results, nine had good results, and two had fair results.

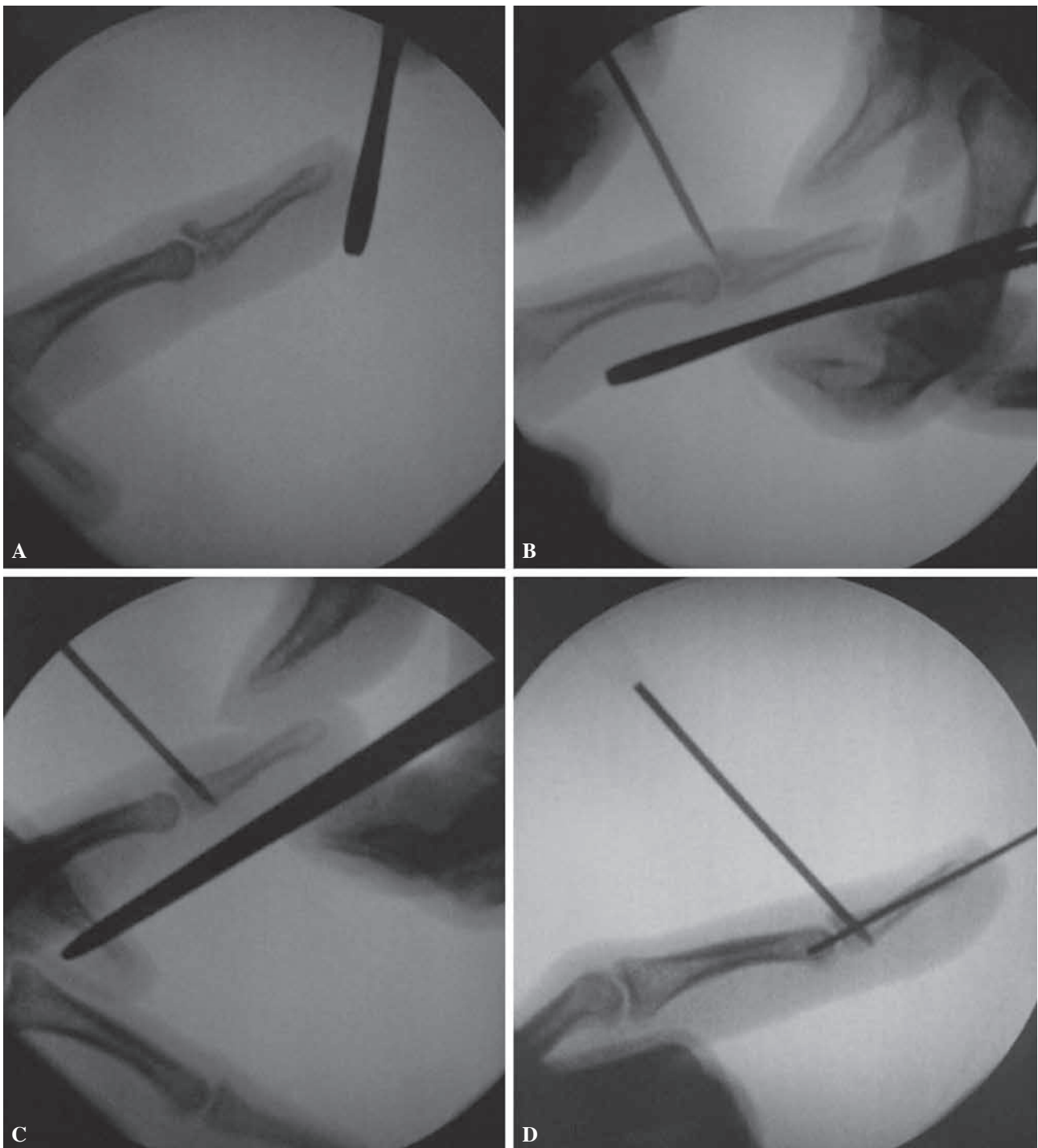


Fig. 4. — Operative technique and intraoperative fluoroscopic images.

(A) A bony fragment at the dorsal base of the distal phalanx. (B) Using an 18-gauge needle, the bony fragment was palpated. (C) After reduction of the fracture site, the 18-gauge needle was passed through the bony fragment. (D) The final result. Image was used to check for complete reduction of bony fragment.

Table I. — Summary of cases

Case	Sex	Age (yr)	Affected finger	Cause	Time from injury to surgery (days)	W-S class	Duration of needle and wire maintenance (days)	Preoperative extensor lag	Postoperative extensor lag	Outcome
1	F	18	Ring	Sports	5	I(B)	23	15°	8°	Excellent
2	M	22	Ring	Fight	5	I(B)	20	10°	5°	Good
3	M	25	Middle	Sports	4	I(B)	22	15°	5°	Good
4	M	33	Ring	Sports	9	I(B)	18	10°	5°	Good
5	M	15	Ring	Sports	5	I(B)	20	10°	0°	Good
6	M	28	Ring	Crushing	8	I(B)	21	5°	0°	Excellent
7	M	24	Middle	Sports	9	I(B)	22	15°	10°	Excellent
8	F	53	Ring	Crushing	7	I(B)	26	15°	10°	Fair
9	F	33	Ring	Crushing	3	I(B)	21	20°	0°	Good
10	M	50	Little	Crushing	60	II(C)	20	20°	10°	Fair
11	M	37	Ring	Fight	13	I(B)	24	20°	5°	Good
12	F	32	Little	Sports	8	I(B)	21	18°	5°	Good
13	M	37	Middle	Crushing	10	I(B)	25	20°	0°	Excellent
14	M	19	Ring	Sports	6	I(B)	24	24°	10°	Good
15	M	27	Middle	Sports	8	I(B)	23	25°	8°	Excellent
16	F	42	Ring	Sports	7	I(B)	24	17°	0°	Excellent
17	M	54	Middle	Crushing	4	II(B)	20	25°	5°	Good

M, male ; F, female ; W-S, Wehbe and Schneider.

DISCUSSION

Mallet fracture is a type of mallet finger deformity with isolated soft tissue injury or a bony avulsion that disrupts the extensor mechanism (4,7). Although surgical management is typically indicated in cases of open fracture, closed fracture can be treated with either surgical intervention or conservative management (14).

In most studies, conservative management consists of 6 to 8 weeks of full-time splinting in extension or slight hyperextension, followed by 2 to 4 weeks of splinting at night (2,22,23).

Wehbe and Schneider (30) suggested conservative treatment for most mallet fractures, regardless of the presence of joint subluxation or the size and amount of fracture displacement. Kalainov *et al* (14) also advocated DIP joint extension splinting for closed and displaced mallet fractures involving greater than one-third of the articular surface due to

good treatment outcomes and high patient satisfaction with finger function.

However, the majority of studies have recommended surgery when a mallet fracture involves more than one-third of the articular surface or is associated with DIP joint subluxation, to prevent early osteoarthritis, swan-neck deformity, and persistent DIP joint stiffness (1,2,4,29).

Surgical management can be performed using either open or closed techniques. Various open reduction and internal fixation techniques have been described, including the use of Kirschner wire fixation (9,26), tension-band wire fixation (3,6,13), pull-out wire fixation (6), figure-of-eight or loop wire fixation (3), and screws (17), or hook plate fixation (28). Open reduction techniques allow precise realignment and fixation under direct vision, but they are not free of complications, such as infection, nail deformity, implant failure, residual pain, dorsal skin breakdown, soft tissue injury and implant

failure because of invasiveness (3,16,25,27,28). Several closed reduction techniques using a percutaneous procedure have been reported to avoid the disadvantages of open techniques. These are performed by extension block pinning, which is the placement of a Kirschner wire through the bony fragment or extensor tendon, followed by pinning across the DIP joint. Percutaneous pinning by extension block was first described by Ishiguro *et al* (11), and modifications of this technique have been introduced to improve the accuracy of reduction and stability of fixation (8,10,18,19,31). However, indirect pinning can lead to fragment comminution, rotation of the fragment or the interposition of soft tissue or periosteum, together with damage to the cartilage of the DIP joint in cases of repeated drilling. Ultimately, it is impossible to accomplish an accurate reduction with small fragments in a non-visualised field (12,15).

As described above, although various surgical techniques – both open and closed – have been utilised to correct mallet fractures, there is no standard due to the limitations and variations of each method (3,6,8,9,10,11,12,13,15,16,17,18,19,25,26,27,28,31). Mallet fractures include small fragments that pose a challenge for accurate reduction and stable fixation since they result in a risk of comminution or rotation during the fixation procedure (21).

In this study, we performed a closed reduction by using a percutaneous fixation technique with an 18-gauge needle with small fragments from mallet fractures that involved more than one-third of the joint surface. We obtained satisfactory results, as measured by radiologic bony union and functional outcomes, with no specific complications.

The advantages of using an 18-gauge needle are convenient insertion and easy passage through the bony fragment by the sharp, pointed end of the needle. This method is faster and more accurate than percutaneous pinning by drilling because the insertion of the needle can be manipulated manually, with direct palpation of the bony fragment. Also, there is a low risk of further fragmentation and rotation of the fracture fragment because the needle can pass through the bone without rotation.

However, one-point fixation of a fracture fragment using a needle does not provide sufficient strength under DIP joint motion (Fig. 5). Therefore,

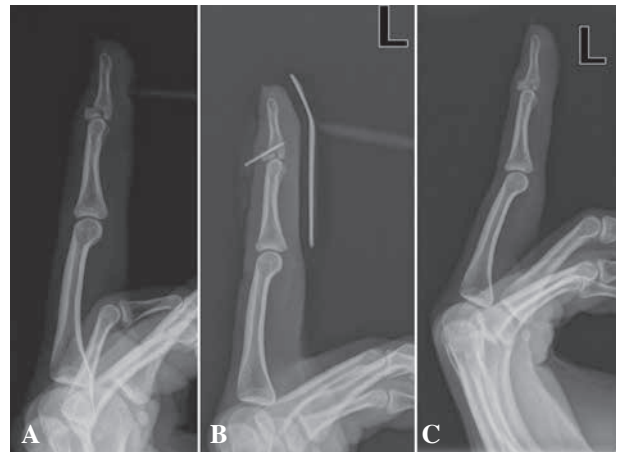

Fig. 5. — An 18-year-old female with a mallet fracture of the left ring finger.

(A) Preoperative X-ray of the type IB mallet fracture. (B) The X-ray 1 week after surgery show a slight gap at the fracture site. (C) The X-ray 5 weeks after surgery shows bony consolidation with minimal displacement.

we performed additional transfixion of the DIP joint by using a Kirschner wire to achieve greater stability of bony alignment. To prevent postoperative ankylosis of the DIP joint, we removed the needle and Kirschner wire on average postoperative day 21 and began passive and active exercises.

This study had several limitations. First, it was retrospective in design. Second, the study included only a small sample size. Third, prolonged maintenance of a needle within the bone is associated with potential complications, such as pin tract infection and bone and soft tissue injury, since the needle was not designed as a tool for bone fixation. Further research to develop a device that can replace the needle is thus needed.

Percutaneous pinning using an 18-gauge needle can overcome the invasiveness of open reduction and the inaccuracy of closed reduction with percutaneous pinning through direct insertion of the needle into the bony fragment. This method can also prevent fragmentation and rotation of the fracture fragment.

Our study indicates that percutaneous pinning with an 18-gauge needle is useful in the fixation of mallet fractures; use of this method could be extended if its safety is verified by additional research.

REFERENCES

1. **Bauze A, Bain GI.** Internal suture for mallet finger fracture. *J Hand Surg Br* 1999 ; 24 : 688-92.
2. **Bendre A A, Hartigan B J, Kalainov DM.** Mallet finger. *J Am Acad Orthop Surg* 2005 ; 13 : 336-44.
3. **Bischoff R, Buechler U, De Roche R, Jupiter J.** Clinical results of tension band fixation of avulsion fractures of the hand. *J Hand Surg Am* 1994 ; 19 : 1019-26.
4. **Bloom JM, Khouri JS, Hammert WC.** Current concepts in the evaluation and treatment of mallet finger injury. *Plast Reconstr Surg* 2013 ; 132 : 560e-66e.
5. **Crawford GP.** The molded polythene splint for mallet finger deformities. *J Hand Surg Am* 1984 ; 9 : 231-7.
6. **Damron TA, Engber WD.** Surgical treatment of mallet finger fractures by tension band technique. *Clin Orthop Relat Res* 1994 : 133-40.
7. **Doyle J.** Extensor tendons : acute injuries. In : Green DP, Hotchkiss RN, Pederson WC, eds. *Operative hand surgery*. 4th ed, Churchill Livingstone, Philadelphia, 1999, pp 1950-70.
8. **Fritz D, Arora R, Gabl M, Lutz M.** Modified Ishiguro extension block technique for fracture-dislocation of the distal interphalangeal joint. *Oper Orthop Traumatol* 2008 ; 20 : 38-43.
9. **Hamas RS, Horrell ED, Pierret GP.** Treatment of mallet finger due to intra-articular fracture of the distal phalanx. *J Hand Surg Am* 1978 ; 3 : 361-3.
10. **Hofmeister EP, Mazurek MT, Shin AY, Bishop AT.** Extension block pinning for large mallet fractures. *J Hand Surg Am* 2003 ; 28 : 453-9.
11. **Ishiguro T, Inoue K, Matsubayashi N, Ito Y, Hashizume N.** A new method of closed reduction for mallet fractures. *J Jpn Soc Surg Hand* 1988 ; 5 : 444-7.
12. **Jorgsholm P, Bjorkman A, Emmeluth C, Bjorkman-Burtscher IM.** Extension block pinning of mallet fractures. *Scand J Plast Reconstr Surg Hand Surg* 2010 ; 44 : 54-8.
13. **Jupiter JB, Sheppard JE.** Tension wire fixation of avulsion fractures in the hand. *Clin Orthop Relat Res* 1987 : 113-20.
14. **Kalainov DM, Hoepfner PE, Hartigan BJ, Carroll Ct, Genuario J.** Nonsurgical treatment of closed mallet finger fractures. *J Hand Surg Am* 2005 ; 30 : 580-6.
15. **Kang HJ, Lee SK.** Open accurate reduction for irreducible mallet fractures through a new pulp traction technique with primary tendon repair. *J Plast Surg Hand Surg* 2012 ; 46 : 438-43.
16. **King HJ, Shin SJ, Kang ES.** Complications of operative treatment for mallet fractures of the distal phalanx. *Journal of hand surgery (Edinburgh, Scotland)* 2001 ; 26 : 28-31.
17. **Kronlage SC, Faust D.** Open reduction and screw fixation of mallet fractures. *J Hand Surg Br* 2004 ; 29 : 135-8.
18. **Lee SK, Kim KJ, Yang DS, Moon KH, Choy WS.** Modified extension-block K-wire fixation technique for the treatment of bony mallet finger. *Orthopedics* 2010 ; 33 : 728.
19. **Mazurek MT, Hofmeister EP, Shin AY, Bishop AT.** Extension-block pinning for treatment of displaced mallet fractures. *Am J Orthop (Belle Mead NJ)* 2002 ; 31 : 652-4.
20. **McCue FC 3rd, Meister K.** Common sports hand injuries. An overview of aetiology, management and prevention. *Sports Med* 1993 ; 15 : 281-9.
21. **Miura T.** Extension Block Pinning Using a Small External Fixator for Mallet Finger Fractures. *J Hand Surg Am* 2013.
22. **Pike J, Mulpuri K, Metzger M, Ng G, Wells N, Goetz T.** Blinded, prospective, randomized clinical trial comparing volar, dorsal, and custom thermoplastic splinting in treatment of acute mallet finger. *J Hand Surg Am* 2010 ; 35 : 580-8.
23. **Richards SD, Kumar G, Booth S, Naqui SZ, Murali SR.** A model for the conservative management of mallet finger. *J Hand Surg Br* 2004 ; 29 : 61-3.
24. **Stack HG.** A modified splint for mallet finger. *J Hand Surg Br* 1986 ; 11 : 263.
25. **Stern PJ, Kastrup JJ.** Complications and prognosis of treatment of mallet finger. *J Hand Surg Am* 1988 ; 13 : 329-34.
26. **Takami H, Takahashi S, Ando M.** Operative treatment of mallet finger due to intra-articular fracture of the distal phalanx. *Arch Orthop Trauma Surg* 2000 ; 120 : 9-13.
27. **Tan V, Beredjiklian PK, Weiland AJ.** Intra-articular fractures of the hand : treatment by open reduction and internal fixation. *J Orthop Trauma* 2005 ; 19 : 518-23.
28. **Teoh LC, Lee JY.** Mallet fractures : a novel approach to internal fixation using a hook plate. *J Hand Surg Eur* 2007 ; 32 : 24-30.
29. **Warren RA, Kay NR, Ferguson DG.** Mallet finger : comparison between operative and conservative management in those cases failing to be cured by splintage. *J Hand Surg Br* 1988 ; 13 : 159-60.
30. **Wehbe MA, Schneider LH.** Mallet fractures. *J Bone Joint Surg Am* 1984 ; 66 : 658-69.
31. **Yamanaka K, Sasaki T.** Treatment of mallet fractures using compression fixation pins. *J Hand Surg Br* 1999 ; 24 : 358-60.