



Short-term results of surgical treatment with cephalomedullary nails for basicervical proximal femoral fractures

Levent TASYIKAN, Ender UGUTMEN, Selim SANEL, Mehmet Salih SOYLEMEZ, Korhan OZKAN, Can SOLAKOGLU

From Department of Orthopaedics and Traumatology, Istanbul Medeniyet University, Göztepe Training and Research Hospital and Maltepe University, Istanbul, Turkey

The treatment of basicervical femoral fractures remains controversial. The aim of this study was to examine the efficacy of intramedullary nail use in the surgical treatment of basicervical fractures. In total, 28 patients with basicervical fractures treated with proximal femoral nails were examined retrospectively. Fracture healing was observed in all patients, who were followed at least for 6 months. While the average radiological fracture healing timing was ~10.5 (8-14) weeks, clinical fracture healing occurred in 6 (5-9) weeks on average. Screw cut-out, avascular necrosis, femur fracture, and surgical wound infections did not occur in any patient. Severe collapse (> 10%) was not noted in any patient. The postoperative mean Harris hip score was 81.2 ± 21.3 . Osteosynthesis application with a proximal femoral nail in basicervical proximal femur fractures is a surgical treatment that can be performed with minimally invasive techniques without open surgery. This is a rapid, sound, and simple treatment method with low morbidity.

Keywords : hip ; survey ; knee arthroplasty ; alignment.

INTRODUCTION

Proximal femoral fractures have been studied in detail because intertrochanteric fractures are seen commonly in orthopaedic practice (17). Various classification systems have been developed, along with treatment algorithms (22,29). Additionally, different treatment models with different implants

have been suggested for various types of these fractures (1,25,27).

Proximal femoral fractures include intertrochanteric fractures (50%), femoral neck fractures (40%) (20), and basicervical fractures (1.8%) (26). There are differences in opinion as to whether basicervical fractures should be considered neck or intertrochanteric fractures. Some have argued that they are extracapsular, while others insist that they are intracapsular fractures (16,22,24,29). Blair *et al* (6)

-
- Korhan Ozkan.
 - Levent Tasyikan.
Department of Orthopaedics and Traumatology, Zonguldak Caycuma State Hospital, Adapazar, Sakarya, Turkey.
 - Ender Ugutmen.
 - Selim Sanel.
 - Can Solakoglu.
Department of Orthopaedics and Traumatology, Maltepe University, Faculty of Medicine, Maltepe/Istanbul, Asia, Turkey.
 - Mehmet Salih Soylemez.
Department of Orthopaedics and Traumatology, Bingöl State Hospital, Bingöl, Turkey.
 - Korhan Ozkan.
Department of Orthopaedics and Traumatology, Istanbul Medeniyet University, Faculty of Medicine, Istanbul, Turkey.

Correspondence : Mehmet Salih Soylemez, Saray Avenue, Hasan Basri Street, Floor 2, Orthopaedic ward. Bingöl, Turkey.
E-mail : slhsylmz@gmail.com

© 2015, Acta Orthopædica Belgica.

defines this fracture as a fracture at the joint area of the intertrochanteric site and the femoral neck, whereas Parker *et al* (24) consider fractures at the capsule adhesion line to be basicervical fractures. Basicervical fractures classified according to AO/OTA classification are considered proximal femur B2.1 type transcervical fractures (29).

Treatment of femoral fractures may change according to the general situation of the patient and the anatomical location of the fracture. However, because the classification of basicervical fractures is uncertain, different treatment methods using various implants have been used to date (10,16,19,21,26,28). The efficacy of intramedullary nails (IMNs) in the treatment of basicervical fractures, which have been shown to be biomechanically superior to DHS, and are used widely in surgical treatment of intertrochanteric fractures today (8,14,25), has been analysed in only one reported study (13).

In this study, patients who were treated with intramedullary nails (IMNs) in our clinic were examined retrospectively and the efficacy of IMN treatment in the surgical therapy of basicervical fractures was examined by analysing patients with basicervical fractures treated using this method.

PATIENTS AND METHODS

In total, 42 patients from two centres between January 2006 and January 2013, who had basicervical femur fractures treated with proximal femur nail (PROFIN), were analysed retrospectively. In anterior-posterior (AP) and lateral radiography, fractures that did not extend to the trochanteric site and were at the joint of the femur neck and intertrochanteric site were considered to be basicervical fractures (Fig. 1). As result of a first analysis by two observers, four patients who were diagnosed with transcervical collum femoris fractures (AO/OTA ; B2.2 and B2.3) and four patients who had trochanteric extensions were excluded from the study. In the second analysis, one patient who died in the first 6 months and five patients whose follow-up times were shorter than 6 months were also excluded. Thus, 28 patients were included in the study.

All patients underwent surgery using proximal femoral nails (PROFIN nails ; TST Ind., Istanbul, Turkey). PROFIN is a nail made of a titanium alloy that is fissured distally and the mediolateral curvature of which is 6°. The nail is of three designs with 10-, 11-, or 12-mm distal diameters. It has a 16-mm proximal diameter and is available in two lengths, 220 and 250 mm. PROFIN can be fixed with two 8.5-mm-diameter lag screws at the proximal end and with two 4.5-mm-

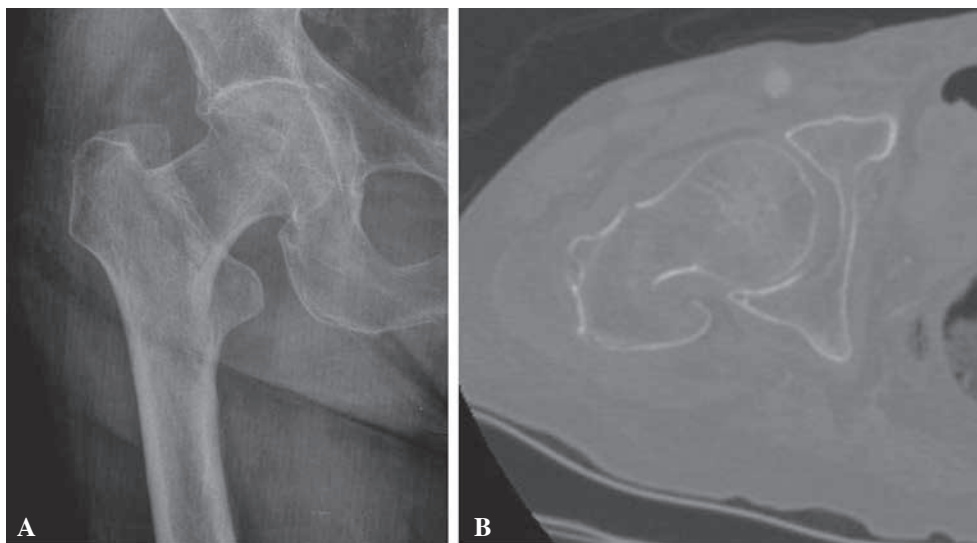


Fig. 1. — Male patient, aged 83. A : AP X-ray shows a basicervical fracture in the right hip that had occurred after a simple fall. B : Coronal computed tomography (CT) section of fracture.



Fig. 2. — Proximal femoral nail (PROFIN)

diameter screws, one dynamic and one static, at the distal end (Fig. 2).

The fracture line was reduced appropriately in accordance with the anatomy before the operation after all patients were prepared according to a standard procedure at the traction table. The operation was conducted in a minimally invasive manner with a 5-cm incision that extended to the trochanter major's tip proximally. Patients not having additional medical problems were mobilised with weight-bearing on postoperative day 1. In the postoperative period, patients were called for follow-up at the first, second, and sixth months, and annually subsequently (Fig. 3).

The Singh index (9) was analysed from the AP radiographs at the preoperative stage for all patients. The degree of reduction was decided upon from AP and lateral radiographs taken at the early postoperative stage. It was regarded as an "anatomical" reduction when the varus, valgus, or anteversion deviated from normal values by less than 5°, between 5 and 10° was considered an "acceptable" reduction, and greater than 10° was deemed a "bad" reduction (3). Not having pain during mobilisation was taken to indicate clinical fracture healing and noticing callus bridging at the fracture line as radiological

fracture healing. Screw cut-out, femur fracture, wound infection, and varus development as a result of collapse were considered to be complications. Taking into consideration the screw location at the very proximal end, developing collapse of less than 10% was considered a "slight collapse," and more than 10% as a "serious collapse" (21). Serious collapse was regarded as a complication. We used the Ficat classification (12) for the radiological classification of the presence of osteonecrosis. Clinical pain, walking capacity, activity, and joint ability were analysed using the Harris hip scoring (HHS) system (18). Independence of the patients during the period they were under their own care was analysed using the modified Barthel index (MBI) (15).

Non-parametric methods were used for the statistical analysis. Categorical variables are recorded as numbers and percentages, and continuous variables as means and standard deviations (SDs). When analysing differences between means of two groups, the Mann-Whitney U-test was used.

RESULTS

Of the patients, 11 (39.3%) were males and 17 (60.7%) females. Their mean age was 71.0 ± 14.3 (45-95). Eight of patients had hip fractures on the right side, while in 20, it was on the left side. Reasons for fractures in five patients were falls from heights, and in 23, falling within the house. When classified according to the Singh index, those with 5 or 6 points were regarded as 'good,' and the others as 'bad.' The mean age of the good group was 60.5 ± 14.5 versus 77.8 ± 8.4 in the bad group ($p = 0.007$; Table I).

The mean follow-up time was 29.2 ± 14.8 (6-72) months. The nail was fixed with the help of two screws proximally, but as a result of technical problems with the guide system in three patients, the distal hole could not be fixed. The nail was fixed from the distal through the dynamic hole with one screw in the remaining 25 patients. The reduction was deemed anatomical in 19 (67.8%) patients, acceptable in 6 (21.4%), and bad in 3 (10.7%). It was noticed that 15° varus developed in two of the three patients with bad reductions versus the other hip and anteversion was decreased by 12° in one patient.

Fracture healing occurred in all patients and no deformity was seen during the healing process. The radiological fracture healing time was 10.5 (8-14)

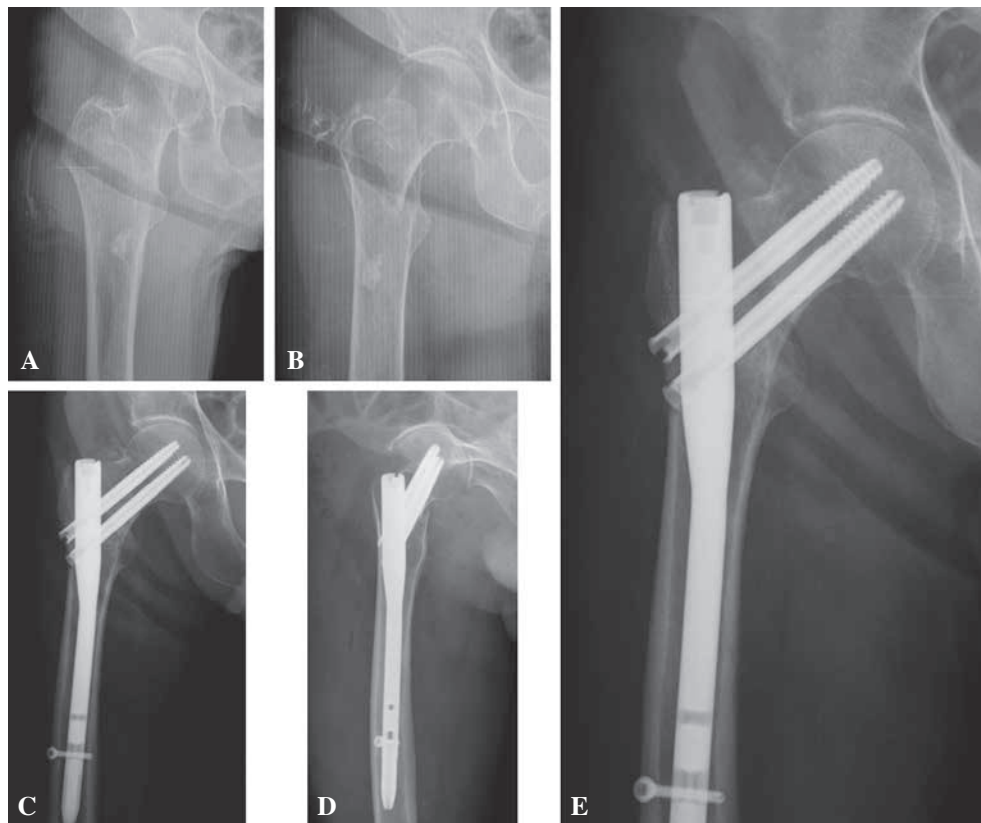


Fig. 3. — A 88-year-old female patient with a right basicervical femoral fracture : 24-month follow-up. Harris hip score = 100, modified Barthel index = 100. A-B : Preoperative X-rays. C-D : Early postoperative X-rays. E : Postoperative X-ray at 24-month follow-up.

Table I. — Singh index distribution

Singh index	Number	%
1	1	3.6
2	3	10.7
3	7	25.0
4	6	21.4
5	8	28.6
6	3	10.7
Total	28	100.0

weeks, on average, and the clinical healing time was 6 (5-9) weeks, on average. No screw cut-out, femur fracture, or surgical wound infection was detected in any patient. Collapse was not encountered in 3 (10.7%) patients, but in 25 (89.3%) patients, slight

(< 10%) collapse was seen. Serious collapse (> 10%) was not seen in any patient.

The mean Harris femur score of the patients was 81.2 ± 21.3 and the mean modified Barthel index was 81.1 ± 26.0 . The Harris hip score results were very good in 42.9% of patients, good in 25.0%, mild in 10.7%, and bad in 21.4% (Table II). According to the modified Barthel index, 50.0% of the patients were fully independent, 7.1% slightly dependent, 21.4% mildly dependent, 14.3% severely dependent, and 7.1% totally dependent (Table III).

The modified Barthel index and Harris hip scores were statistically significantly higher in the patients aged 64 and younger versus patients aged 65 and older ($p = 0.014$ and 0.007 , respectively). As the ages of the patients increased, the mean Bartel and Harris scores decreased. When the patients were categorised into two groups : those less than and

Table II. — Harris Hip Score distribution of the patients

Harris Hip Score	Number	%
very good	12	42.9
good	7	25.0
mild	3	10.7
bad	6	21.4
Total	28	100.0

Table III. — Modified Barthel index distribution

Modified Barthel Index	Number	%
Fully dependent	2	7.1
Severe dependent	4	14.3
Mild dependent	6	21.4
Slightly dependent	2	7.1
Fully independent	14	50.0
Total	28	100.0

more than 65 years of age, the mean value of the Harris hip score for those less than 65 years of age was 93.1 ± 16.2 , and for those more than 65 years of age was 75.6 ± 21.3 . The mean value of the MBI for those less than 65 years of age was 96.7 ± 10.0 , and for those more than 65 years of age was 73.7 ± 28.1 (Table IV). No significant association was found between reduction quality and MBI or HHS ($p = 0.51$ and 0.49 , respectively).

DISCUSSION

The treatment and definition of basicervical femoral fractures have been controversial. Moreover, there are few data about treatment, especially in comparison with other types of femur fracture. Basicervical fractures have been treated using Ender nails, DHS, Jewet nails, ASIF 130° angled blade plates, Knowles pins, external fixators, and hemiarthroplasty to date (7,10,16,19,21,28,26). However, as a result of the clinical and biomechanical studies published to date, it seems clear that the only treatment type demonstrated to be effective is DHS, and an antirotation screw to set the DHS to prevent rotation is beneficial for providing rotational control, but makes no additional contribution to fixation or stability (6,11).

Table IV. — Statistical analysis between age groups and means and standard deviations of the modified Barthel index and Harris hip score according to age

	Modified Barthel Index	Harris Hip Score
Age (year)	Mean \pm SD	Mean \pm SD
≤ 64	96.7 ± 10.0	93.1 ± 16.2
≥ 65	73.7 ± 28.1	75.6 ± 21.3
p value*	0.014	0.007

Few studies have researched the treatment of basicervical fractures. In the study by Kuokkanen *et al* (1991) (16), six surgical treatments were used in 38 patients with basicervical fractures and the results were compared. The authors emphasised that the rate of fracture healing in basicervical fractures was low, asserted that the use of hemiarthroplasty and Ender nails was unsuitable, and stated that the option of using cannulated screws was especially suitable for intracapsular fractures and that blade plates (ASIF, Jewet), despite being an old design, were the most suitable choice for the treatment of basicervical fractures. Saarenpaa *et al* (2002) (26) examined 1624 femur fractures over 8 years retrospectively and found 30 (1.8%) basicervical fractures. Of these 30 patients, 16 were treated as intracapsular fractures and 14 as extracapsular. The authors evaluated basicervical femoral fractures as a type of extracapsular fracture and concluded that the results were more successful when treated, that a hemiarthroplasty is not a good choice for the treatment of basicervical fractures, and that sliding hip screws were more stable than multiple cancellous screws. Su *et al* (2006) (28) evaluated 66 patients retrospectively and compared the long-term functional results of intertrochanteric fractures and basicervical fractures, the stability of fractures and the effectiveness of an antirotation screw used together with a DHS between the two groups. The authors determined that more collapse developed in the femoral neck during the recovery period in the group with basicervical fractures, and stated that this was the result of the basicervical fractures being more unstable than intertrochanteric fractures. They also remarked that the antirotation screw had no impact on the stability of fractures or the functional

results. Boghdady *et al* (2007) (7) operated on patients with basicervical fractures who had other comorbidities and patients who could not be operated on because of their poor condition using an AO external fixator under local anaesthesia. They reported that the results were good and that the external fixator can be a good treatment choice. Chen *et al* (2008) (10) examined the results of 200 patients with basicervical fractures retrospectively and stated that DHS was effective in the treatment of basicervical fractures. In a study of 42 patients, Massoud (2010) (21) stated that AO, B2.1, A1.1, A2.1, A2.2, and A2.3 fracture types were similarly unstable and for this reason, B2.1 (basicervical)-type fractures should be considered to be extracapsular fractures and the surgical treatment should be decided on accordingly. The author determined that a lag screw with DHS provided sufficient rigid fixation and that antirotation screws only prevented rotation.

Today, IMNs are used frequently in the surgical treatment of intertrochanteric fractures because it is less invasive, requires less blood transfusion, ensures mobilisation of patients in a shorter time, is superior to DHS biomechanically, and the operation duration is shorter (8,14,25). However, only one clinical study in which IMNs were used in the treatment of basicervical fractures has been reported. Hu *et al* (2013) (13) treated 30 patients with basicervical fractures with IMNs and published their results recently. All of the patients observed for at least 24 months developed bone union, 27 with no deformity, three with "slight" varus in the hip, and none with advanced varus or cut-out. The average Harris score was 86.5 (75-96); 11 patients had perfect, 15 had good, and four had bad results. The authors explained that IMN use in the treatment of basicervical fractures allowed early mobilisation by ensuring stable fixation and that the mid- and short-term results were excellent.

Because there was no avascular necrosis in the cases with basicervical fractures reported in the previous studies, it has been proposed that these fractures be treated as unstable intertrochanteric fractures, by regarding them as extracapsular (21). No avascular necrosis was detected in our study. It seems reasonable to use IMNs in the treatment of

basicervical fractures providing that there are successful results in unstable extracapsular intertrochanteric fractures using IMNs (4). It has been reported that sufficient stability can be ensured with only one screw with DHS in surgical treatment while an anti-rotation pin should be used to ensure rotational control (21). Because the femur head is fixed with two screws when using IMNs, rotation can be controlled readily when creating resistance against bending and axial loading forces (4). Although we achieved bad reductions in the early postoperative phase in three of our cases, the deformity did not proceed and bone unions were achieved in clinical observations. These three patients were continuing to live freely at the eighth month postoperatively. This demonstrates that sufficient stable fixation can be achieved using IMNs.

The early mobilisation of patients after the surgical treatment of intertrochanteric fractures is vital for returning them to their normal lives and to prevent pulmonary embolisms and other medical complications (2). Two surgical methods enabling this are hemiarthroplasty and IMNs. However, because the proposed method is to treat the basicervical fractures by considering them to be extracapsular fractures, hemiarthroplasty is not a treatment choice for these patients (16,26). All the patients in our study were mobilised on the day after surgery and weight bearing was allowed. Although radiological healing of the 28 patients was seen at 10.5 weeks, on average, clinical healing was achieved in 6 weeks. There was no protrusion of screws, no femur fractures, no screw cut-out, and no wound site infections, despite the patients being allowed to bear weight at an early stage.

Low bone density, unstable fractures, and insufficient reductions are the three most important factors in the development of cut-out (5). Basicervical fractures are unstable and studies of DHS have detected serious collapses at a rate of up to 75%, which can result in cut-out and protrusion on the femur head during the healing phase (28). Although the Singh index in 16 of our patients (57%) indicated 'bad,' no serious (> 10%) collapse was detected in our patients. Additionally, no case of cut-out or protrusion occurred. To avoid from a potential femoral diaphysis fracture and increase the operation time

nail was not locked freehand in patients whose distal lock screws could not be locked because of technical difficulties. The fracture healing of these three patients healed within a normal time period and no newly developed deformity was detected at the last follow-up. It is understood that if a stable anatomical reduction is achieved in an unstable intertrochanteric fracture treated with IMN, then distal locking is not essential (23). For this reason, not being able to lock the distal screw was not regarded as a complication.

The Harris hip score and the modified Barthel index of the patients were only assessed at the last follow-up. The mean Harris score was 81.2 ± 21.3 and the mean modified Barthel index was 81.1 ± 26.0 . In the statistical analyses, it was understood that these scoring systems, independent of other parameters, were age-dependent, so long as the patients were categorised as older and younger than 64 years.

In conclusion, the complications that develop after the surgical treatment of extracapsular fractures depend on the stability of the fracture, the quality of the bone, and the quality of the reduction. Basicervical fractures are considered extracapsular fractures. They are unstable extracapsular fractures and can show good results when treated with IMNs even if the bone quality is poor. The fixation of basicervical fractures can provide sufficient stability during the fracture healing period, when using IMNs. IMN use is less invasive than DHS. It allows early mobilisation of the patients and provides earlier fracture union clinically.

The most important limitation of our study was the small number of patients included. To obtain more comprehensive results regarding rarely seen complications, such as cut-out, femoral fractures, and postoperative results of IMN use in basicervical fractures, it is important to conduct further studies in a larger number of patients that include operated-on control groups and patients with unstable intertrochanteric fractures.

REFERENCES

1. Adams CI, Robinson CM, Court-Brown CM, McQueen MM. Prospective Randomized Controlled Trial of an Intramedullary Nail Versus Dynamic Screw and Plate for Intertrochanteric Fractures of the Femur. *J Orthop Trauma* 2000 ; 15 : 394-400.
2. Aharonoff GB, Koval KJ, Skovron ML, Zuckerman JD. Hip fractures in the elderly : predictors of one year mortality. *J Orthop Trauma* 1997 ; 11 : 162-165.
3. Akan K, Cift H, Ozkan K *et al.* Effect of Osteoporosis on Clinical Outcomes in Intertrochanteric HipFractures Treated with a Proximal Femoral Nail. *J Int Med Res* 2011 ; 39 : 857-865.
4. Banan H, Al-Sabti A, Jimulia T, Hart AJ. The treatment of unstable, extracapsular hip fractures with the AO/ASIF proximal femoral nail (PFN) – our first 60 cases. *Injury* 2002 ; 33 : 401-405.
5. Barrios C, Brostrom L.A, Stark A *et al.* Healing complications after internal fixation of trochanteric hip fractures : the prognostic value of osteoporosis. *J Orthop Trauma* 1993 ; 7 : 438.
6. Blair B, Koval KJ, Kummer F, Zuckerman JD. Basicervical fractures of the proximal femur. A biomechanical study of 3 internal fixation techniques. *Clin Orthop* 1994 ; 306 : 256-263.
7. Boghdady GW, Shalaby M. Safety and reliability of external fixation for basicervical and intertrochanteric fractures in high-risk elderly patients. *Strategies Trauma Limb Reconstr* 2007 ; 2 : 83-9.
8. Bridle SH, Patel AD, Bircher M, Calvert PT. Fixation of intertrochanteric fractures of the femur : a randomised prospective comparison of the Gamma nail and the dynamic hip screw. *J Bone Joint Surg Br* 1991 ; 73 : 330-4.
9. Browner BD, Jupiter JB, Levine AM, Trafton PG, Krettek C. *Skeletal trauma* (4th ed). Saunders Elsevier Press, Philadelphia 2009 : pp 1913-57
10. Chen CY, Chiu FY, Chen CM *et al.* Surgical treatment of basicervical fractures of femur : a prospective evaluation of 269 patients. *J Trauma* 2008 ; 64 : 427-9.
11. Deneka DA, Simonian PT, Stankewich CJ *et al.* Biomechanical comparison of internal fixation techniques for the treatment of unstable basicervical femoral neckfractures. *J Orthop Trauma* 1997 ; 11 : 337-43.
12. Ficat RP. Idiopathic bone necrosis of the femoral head. Early diagnosis and treatment. *J Bone Joint Surg Br* 1985 ; 67 : 3-9.
13. Hu SJ, Yu GR, Zhang SM. Surgical treatment of basicervical intertrochanteric fractures of the proximal femur with cephalomedullary hip nails. *Orthop Surg* 2013 ; 5 : 124-9.
14. Jones H.W, Johnston P, Parker M. Are short femoral nails superior to the sliding hip screw ? A meta-analysis of 24 studies involving 3,279 fractures. *Int Orthop* 2006 ; 30 : 69-78.
15. Kesmezacar H, Ogut T, Bilgili G *ve ark.* Treatment of intertrochanteric femur fractures in elderly patients : internal fixation or hemiarthroplasty. *Acta Orthop Traumatol Turc* 2005 ; 39 : 287-294.

16. **Kuokkanen HO.** Treatment options for basicervical fractures of the femoral neck : a clinical follow-up. *Acta Orthop Belg* 1991 ; 57 : 162-168.
17. **Laskin R.S, Gruber M.A, Zimmerman A.J.** Intertrochanteric fractures of the hip in the elderly : A retrospective analysis of 236 cases. *Clin Orthop Relat Res* 1979 ; 188-95.
18. **Lavini F, Renzi-Brivio L, Aulisa R et al.** The treatment of stable and unstable proximal femoral fractures with a new trochanteric nail : results of a multicentre study with the Veronail. *Strat Traum Limb Recon* 2008 ; 3 : 5-21.
19. **Levy RN, Siegel M, Sedlin ED, Siffert RS.** Complications of Ender-pin fixation in basicervical, intertrochanteric, and subtrochanteric fractures of the hip. *J Bone Joint Surg Am* 1983 ; 65 : 66-9.
20. **Lieberman JR.** AAOS Comprehensive Orthopaedic Review. *American academy of orthopaedic surgeons* 2009, pp 597-98.
21. **Massoud EI.** Fixation of basicervical and related fractures. *Int Orthop* 2010 ; 34 : 577-82.
22. **Muller ME, Nazarian S, Koch P, Schatzker J.** The Comprehensive Classification of Fractures of Long Bones. New York, NY : Springer-Verlag ; 1990 pp :116.
23. **Ozkan K, Unay K, Demircay C, Cakir M, Eceviz E.** Distal unlocked proximal femoral intramedullary nailing for intertrochanteric femur fractures. *International Orthopaedics (SICOT)* 2009 ; 33 : 1397-1400.
24. **Parker MJ, Pryor GA, Thorngren K-G.** Extramedullary fixation of extracapsular fractures. In : Parker MJ (ed) Handbook of hip fracture surgery. Butterworth-Heinemann, Oxford, 1997, pp 63-90.
25. **Parker MJ., Handoll HH.** Gamma and other cephalocondylic intramedullary nails versus extramedullary implants for extracapsular hip fractures. *Cochrane Database Syst Rev* 2008 ; 16. CD000093.
26. **Saarenpaa I, Partanen J, Jalovaara P.** Basicervical fracture – a rare type of hip fracture. *Arch Orthop Trauma Surg* 2002 ; 122 : 69-72.
27. **Simmermacher R.K.J, Ljungqvist J, Bail H, Hockertz T, Vochteloo AJH et al.** The new Proximal femoral antirotation (PFNA) in daily practice : Results of a multicentre clinical study. *Injury* 2008 ; 39 : 932-939.
28. **Su BW, Heyworth BE, Protopsaltis TS, Lipton CB, Sinicropi SM et al.** Basicervical versus intertrochanteric fractures : an analysis of radiographic and functional outcomes. *Orthopedics* 2006 ; 29 : 919-25.
29. **The Orthopedic Trauma Association Classification of Fractures.** *J Orthop Trauma* 1996 ; 10 (Suppl 1) : 34.