



The reliability and validity of the Unified Classification System of periprosthetic femoral fractures after hip arthroplasty

Jie-Feng HUANG, Jun-Jie CHEN, Jian-Jian SHEN, Wen-Xi DU, Fu-Cun LIU, Pei-Jian TONG

From Department of Orthopedics, The First Affiliated Hospital of Zhejiang Chinese Medical University, Hangzhou, China

The Unified Classification System has expanded and updated the Vancouver Classification System and applied treatment principles to all periprosthetic fractures. This study assessed the reliability and validity of the Unified Classification System for femur fractures after hip arthroplasty. Thirty-eight radiographs were finally evaluated by 6 observers, 3 consultants and 3 trainees. Each observer read the radiographs on 2 separate occasions, independently, at least 2 weeks apart. Interobserver and intraobserver agreement and validity were analyzed, using weighted κ statistics. The mean κ value for interobserver agreement was found to be 0.849 (0.838-0.871) for consultants (almost perfect agreement) and 0.761 (0.707-0.836) for the trainees (substantial agreement). Intraobserver κ values ranged from 0.740 to 0.903, showing substantial to almost perfect agreement. Validity analysis of 23 type B cases revealed 79.710% agreement within B1, B2, and B3 subgroups with a mean κ value of 0.694 (0.670-0.741) (substantial agreement).

Keywords: arthroplasty; femoral periprosthetic fracture; Unified Classification System; reliability; validity.

INTRODUCTION

Periprosthetic femoral fracture after total hip arthroplasty (THA) is an increasing clinical problem (1,3,6,7,9,12,17,19,21,24). They were identified as the third most frequent reason for revision follow-

ing primary THA, after aseptic loosening and sepsis (9,18). Periprosthetic fractures are difficult to manage and may have a poor outcome. The treatment of periprosthetic fractures of the femur after THA remains a surgical challenge (3,6,11,16,17,19). There are many variables that need to be considered with each fracture, including fracture site and pattern, implant stability and the surrounding bone quality, complex with the more general factors such as patient's age and functional demands (3,16,19).

Various classifications have been described, some of which depend on the site of the fracture (14,20), and others on the pattern of the fracture or relationship to the stability of the implant (2,5,13,14,20,22). These historical classification

Jie-Feng Huang and Jun-Jie Chen are co-first authors.

- Jie-Feng Huang¹.
- Jun-Jie Chen¹.
- Jian-Jian Shen².
- Wen-Xi Du¹.
- Fu-Cun Liu¹.
- Pei-Jian Tong¹, MD.

¹Department of Orthopedics, The First Affiliated Hospital of Zhejiang Chinese Medical University, Hangzhou, China.

²Department of Orthopaedics, Affiliated Cixi Hospital of Wenzhou Medical College, Cixi, China.

Correspondence: Pei-Jian Tong, Department of Orthopedics, The First Affiliated Hospital of Zhejiang Chinese Medical University, 54 Youdian Road, Shangcheng District, Hangzhou, 310006, China. E-mail: tpj637963@163.com

© 2016, Acta Orthopædica Belgica.

Table I. — The Unified Classification System (UCS) : femur

Type	Subtype	Fracture description	Treatment
Type A		Fracture in trochanteric region	
	AG	Fracture of the greater trochanter	Conservative or cable wires
	AL	Fracture of the lesser trochanter	Conservative or cable wires
Type B		Fracture around stem or just below it	
	B1	Well-fixed stem	ORIF
	B2	Loose stem with good proximal bone stock	Revision THA
	B3	Loose stem with poor-quality bone stock	Revision THA
Type C		Fracture occurring well below the tip of the stem	ORIF
Type D		Fracture of the femoral shaft between well-fixed hip and knee replacements (Type C for each)	ORIF
Type E		Both the femur and acetabulum fractures after THA	Logical individual treatment
Type F		Does not apply to the femur	

ORIF : open reduction and internal fixation ; THA : total hip arthroplasty.

systems (2,5,13,14,20,22) for periprosthetic fractures of the femur have been superseded by the Vancouver Classification System (10) which has become universally accepted. The reliability and validity of the Vancouver Classification System of periprosthetic femoral fractures after hip replacement had been confirmed (3,19,21). In 2014, Duncan and Haddad (9) introduced the Unified Classification System in order to expand and update the Vancouver Classification System and apply treatment principles to all periprosthetic fractures. When applied to the femur, the Unified Classification System incorporates the previous Vancouver Classification System but is expanded to include two new fracture pattern, type D and E (9,24) (Table I).

Type A fractures are located at the lesser trochanter (AL) and at the greater trochanter (AG). Type B fractures are located around or just below a well-fixed stem (B1) (Fig. 1), around or just below a loose stem with adequate bone stock (B2) (Fig. 2), around or just below a loose stem with poor proximal bone stock (B3) (Fig. 3). Type C fractures are significantly distal to the stem. Type D is a fracture of the femoral after hip and knee arthroplasty (Type C for each joint). Type E is both a fracture of the acetabulum and femur after hip arthroplasty (Fig. 4). Type F fracture pattern applies only to the acetabulum after hemi-arthroplasty of the hip.

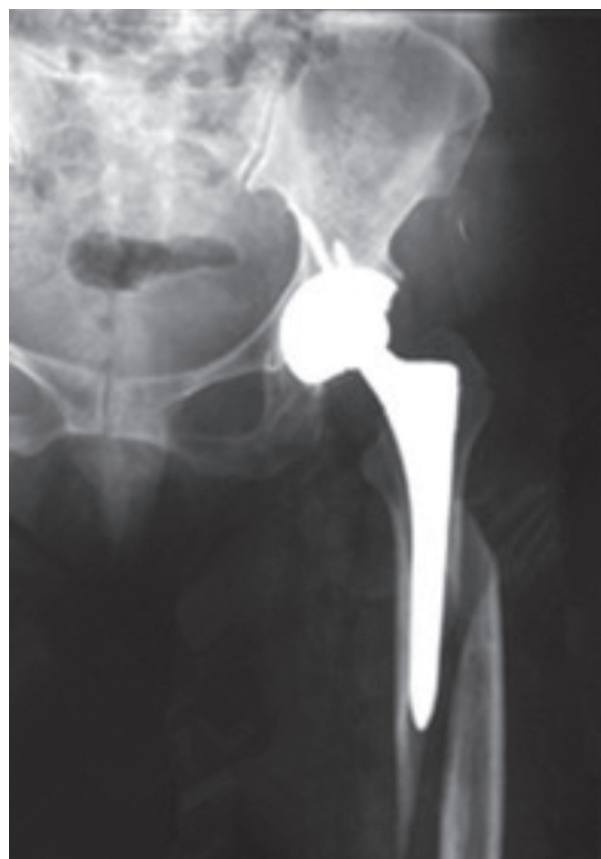

Fig. 1. — Anteroposterior radiograph of the left hip and proximal femur showing a B1 type periprosthetic fracture. The stem is well-fixed.

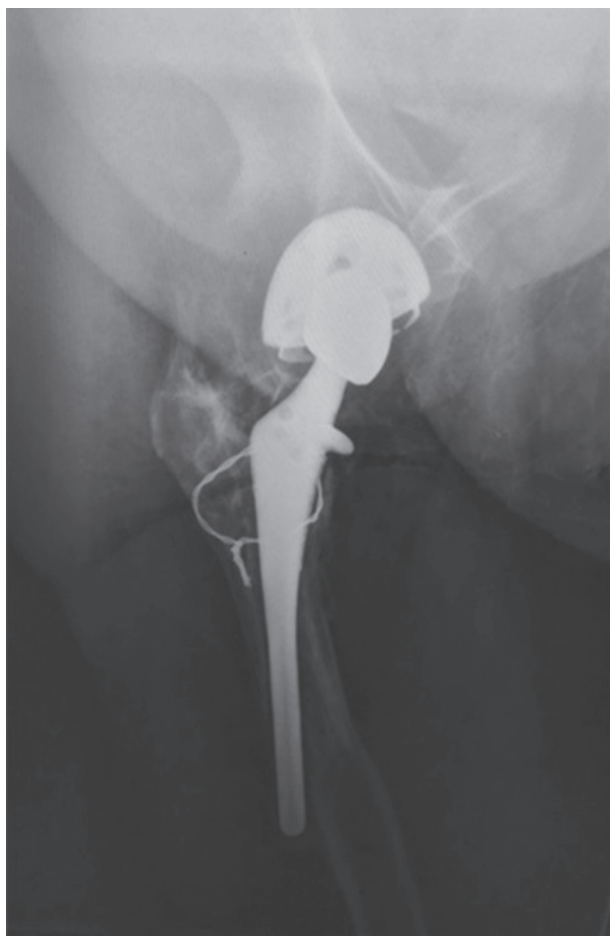

Fig. 2. — Lateral radiograph of the left hip and proximal femur showing a B2 type periprosthetic fracture. The stem is loose but there is adequate bone stock.

For any classification system to be useful, it should not only guide treatment and help in the decision-making process, but also be reliable and valid. The objective of this study is to independently assess the interobserver and intraobserver reliability and validity of the Unified Classification System, in our hospital.

MATERIALS AND METHODS

The study was approved by IRB (Institutional Review Board) of the hospital. We retrospectively analyzed a cohort of 41 consecutive patients who had sustained a periprosthetic fracture of the hip between January 2000 and October 2014. Each subtype applied to the femur of the Unified Classification System was represented at least

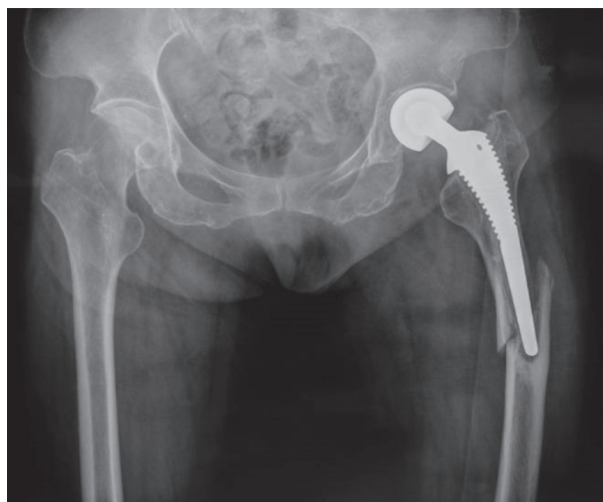

Fig. 3. — Anteroposterior radiograph of the pelvis showing a B3 type periprosthetic fracture. The stem is loose but there is deficient bone stock in the proximal femur.

once. The full extent of the fracture and prosthesis needed to be clearly visible on the available radiograph in at least 2 planes for inclusion in the study. Suitability for inclusion was ultimately judged by the first author (J.F. Huang), who was independent of all observers and not involved in the judgment process. Only patients with a pre-operative radiological diagnosis and complete operative documentation of the type of fracture were included. Cases were excluded if any of the following were present: migration or fracture of an old nonunited trochanteric osteotomy; revision Exeter component (impaction cancellous allograft), and fracture of the femoral prosthesis. Three cases were excluded. Thirty-eight patients were tested in our study. There were 15 men and 23 women with a mean age of 75.7 years (56.4 to 89.2).

The study was done in 2 parts. Part 1 of the study involved the analysis of interobserver and intraobserver reliability of the Unified Classification System. Six observers were involved in this study, including 3 consultants and 3 trainee surgeons (registrar). All participants reviewed the Unified Classification System before the study. Radiographs of all 38 patients were classified by all 6 participants independently, on 2 separate occasions, at least 2 weeks apart. Part 2 of the study assessed of validity of the classification by comparing the subgroup classification of type B fractures with the intraoperative findings, as retrieved from the operative notes. The senior consultant's classification results were used for validation purpose and were compared with the intraoperative findings.

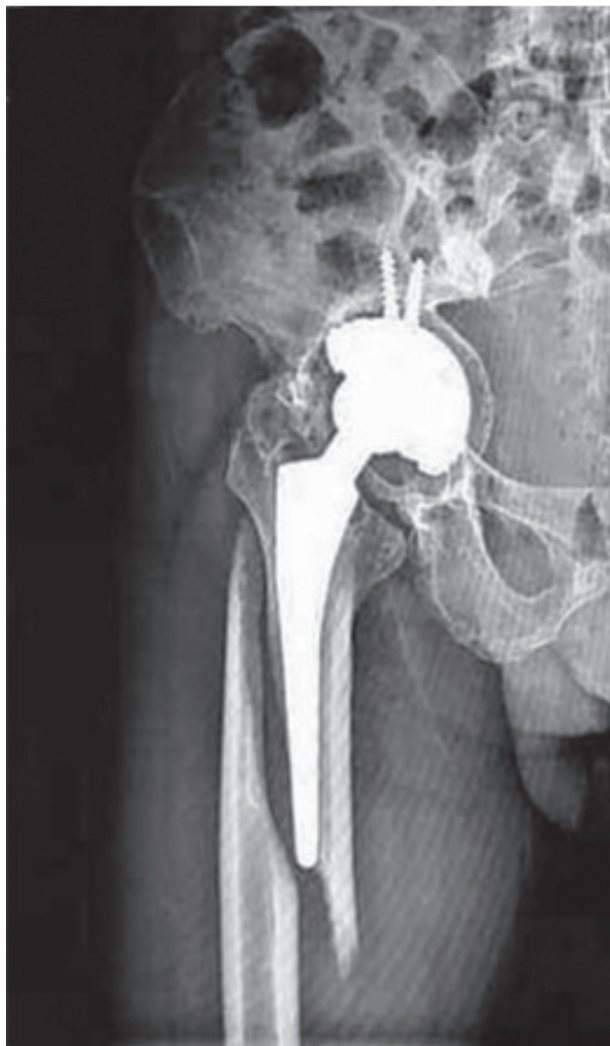

Fig. 4. — Anteroposterior radiograph of the right hip and proximal femur showing a type E periprosthetic fracture of the proximal femur with an associated fracture of the acetabulum.

All data were analyzed using the weighted Kappa statistic to measure the level of agreement for 2 observers, using the Landis and Koch (15) criteria for interpretation. Values of 0.00 to 0.20 indicate slight agreement ; 0.21 to 0.40, fair agreement ; 0.41 to 0.60, moderate agreement ; 0.61 to 0.80, substantial agreement. Values of more than 0.80 represent almost perfect agreement (15).

RESULTS

Thirty-eight cases were finally included in this study. Interobserver agreement was separately ac-

cessed for the first reading among all the possible pairs of consultants and trainees (Table II). The mean κ value was 0.849 (0.838-0.871) for consultants (almost perfect agreement) and 0.761 (0.707-0.836) for the trainees (substantial agreement), more so among the consultants than the trainees. Intraobserver κ values ranged from 0.740 to 0.903, showing substantial to almost perfect agreement. The mean κ value was found to be 0.891 for consultants and 0.783 for trainee surgeons.

Validity analysis involved 23 type B cases and, when compared with the operative findings, showed 79.710% agreement within the B1, B2, and B3 subgroups, with a mean κ value of 0.694 (0.670-0.741) (substantial agreement) and a standard error of 0.121 (Table III).

DISCUSSION

Periprosthetic fractures are difficult to manage and may have a poor outcome. Historically, the treatment of periprosthetic femoral fractures has been associated with a high frequency of complications and reoperations (12,17). The treatment of periprosthetic fractures of the femoral after THA remains a surgical challenge (3,6,11,16,17,19). Consequently, a robust, reliable classification which can establish the principles of management for surgical treatment of periprosthetic fractures is needed. Several authors (2,5,13,14,20,22) have written about the need for a standardized classification and an adequate treatment algorithm for late femoral periprosthetic fractures. Parrish *et al* (1964) (20) classified periprosthetic fractures in relation to their location, as : trochanteric ; proximal ; middle ; or distal third fractures. Johansson *et al* (1981) (14) classified fractures in relation to the implant as proximal to the tip of the stem ; extending beyond the tip of the stem ; or entirely beyond the tip. Bethea *et al* (1982) (2) expanded on these classifications to incorporate position and pattern : type A occurring distal to the tip of the stem ; type B as spiral fractures around the stem ; and type C as comminuted fractures around the stem. Cooke *et al* (1988) (5) described four types of periprosthetic fracture and emphasized the need for early revision in the comminuted type 1 fracture, while the type 2 transverse fracture around the stem

Table II. — Interobserver Reliability of the Unified Classification System : femur

Groups	κ Value	% Agreement
Consultant A-B	0.838	86.842%
Consultant A-C	0.871	89.474%
Consultant B-C	0.838	86.842%
Mean κ value 0.849 (95% confidence interval, 0.802-0.896)		
Trainee A-B	0.836	86.842%
Trainee A-C	0.707	76.316%
Trainee B-C	0.740	78.947%
Mean κ value 0.761 (95% confidence interval, 0.595-0.928)		

Table III. — The validity assessment for type B fracture

Groups	κ Value
Consultant A-Intraoperative	0.741
Consultant B-Intraoperative	0.670
Consultant C-Intraoperative	0.670
Mean κ value 0.694 (95% confidence interval, 0.592-0.796)	

could be managed either conservatively or by revision. They proposed that fractures at or distal to the tip of the stem (type 3 and 4 respectively) required internal fixation. Jensen *et al* (1988) (13) emphasized the importance of implant stability at the time of injury as a predictor for revision of the prosthesis. Fractures were classified as type 1 when located around the proximal two-thirds of the femoral component, type 2 when the fracture extended proximal and distally from the stem tip, and type 3 when the fracture extended distal to the tip of the stem. Roffman *et al* (1989) (22) described on the basis of the predicted stability of the implant of ipsilateral femur fractures after THA.

These historical classification systems (2,5,13,14, 20,22) for periprosthetic fractures of the femur have been superseded by the Vancouver Classification System (Duncan *et al.* 1995) (10) which has become universally accepted. The reliability and validity of the Vancouver Classification System of periprosthetic femoral fractures after hip replacement had been confirmed (3,19,21). In 2014, Duncan and Haddad (9) introduced the Unified Classification System. Its purpose is threefold: to expand and update the Vancouver Classification System by the

addition of three subtypes which are increasing in prevalence; to apply these groupings and treatment principles to all periprosthetic fractures regardless of the bone that is broken and the joint involved; and lastly, to propose a common language so that we may communicate with clarity and simplicity, regardless of our native tongue, preferred dialect, and subspecialty limb or joint of interest (8). When applied to the femur, the Unified Classification System incorporates the previous Vancouver Classification System but is expanded to include two new fracture pattern, type D and E (9,24).

The reliability and validity of the Unified Classification System for periprosthetic fracture of the pelvis and femur around a total hip replacement have been assessed by Vioreanu *et al* in 2014 (24). They tested the inter- and intra-observer agreement for the Unified Classification System as applied to the pelvis and femur using 20 examples of periprosthetic fracture in 17 patients. When applied to the femur, interobserver reliability showed κ values of 0.805 for consultants, 0.732 for trainees (24). Our study reconfirmed the finding of the prior study with comparable result and showed intraobserver and interobserver agreement.

The study has shown that the Unified Classification System for periprosthetic femoral fracture is reliable. Intraobserver and interobserver agreement was judged to be substantial to almost perfect by κ analysis.

In this study, the validity assessment for type B fracture subgroups showed an observed agreement of 79.710% with a κ value of 0.694, indicating substantial agreement. However, like 3 prior stud-

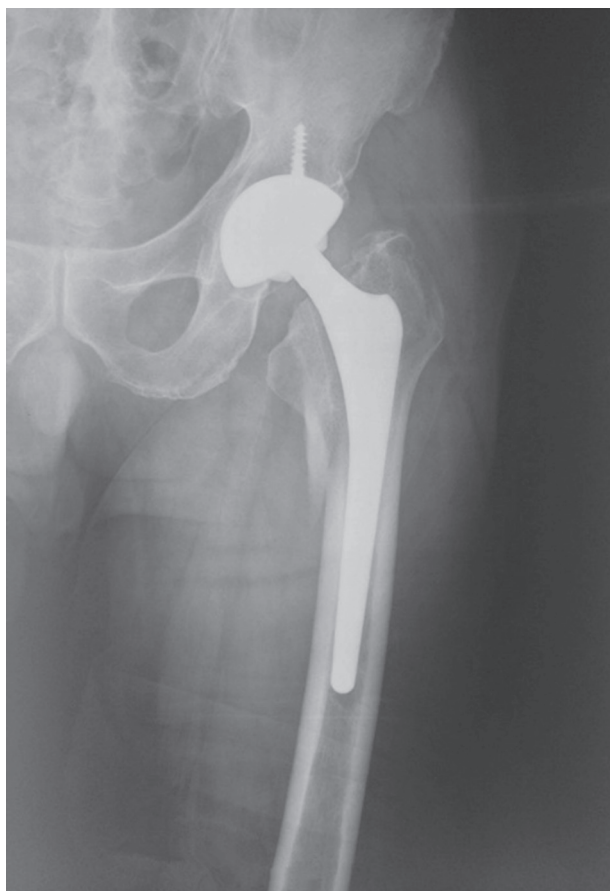


Fig. 5. — Anteroposterior radiograph of the left hip and proximal femur showing a pseudo A type periprosthetic fracture, but it's really a B2 type periprosthetic fracture. Fractures of the lesser trochanter as well as the greater trochanter, the stem is loose but there is adequate bone stock.

ies (3,19,21), this one also failed to achieved perfect agreement. This indicates that implant stability can be difficult to determine from radiographs alone. This finding has an important bearing on the consequences, as choosing the wrong treatment can lead to early failure. For example, Van Houwelingen *et al* (2011) (23) and Capello *et al* (2014) (4) reported pseudo A(LT) periprosthetic fracture : it's really a B2 (Fig. 5). The new fracture pattern was not described in the original Vancouver Classification System and the Unified Classification System.

The goal of any classification system is ultimately to improve patient outcome. To be able to accomplish this goal, the classification must guide treatment, be reliable, and valid. The Unified

Classification System of periprosthetic fractures for femur has been shown to be reliable and valid in this study, but remains need to be refined in the future.

REFERENCES

1. **Baba T, Homma Y, Momomura R *et al*.** New classification focusing on implant designs useful for setting therapeutic strategy for periprosthetic femoral fractures. *Int Orthop* 2014 ; Aug 5.
2. **Bethea JS 3rd, DeAndrade JR, Fleming LL *et al*.** Proximal femoral fractures following total hip arthroplasty. *Clin Orthop Relat Res* 1982 ; 170 : 95-106.
3. **Brady OH, Garbuz DS, Masri BA, Duncan CP.** The reliability and validity of the Vancouver classification of femoral fractures after hip replacement. *J Arthroplasty* 2000 ; 15 : 59-62.
4. **Capello WN, D'Antonio JA, Naughton M.** Periprosthetic fractures around a cementless hydroxyapatite-coated implant. *Clin Orthop Relat Res* 2014 ; 472 : 604-610.
5. **Cooke PH, Newman JH.** Fractures of the femur in relation to cemented hip prostheses. *J Bone Joint Surg Br* 1988 ; 70 : 386-389.
6. **Corten K, Vanrykel F, Bellemans J *et al*.** An algorithm for the surgical treatment of periprosthetic fractures of the femur around a well-fixed femoral component. *J Bone Joint Surg Br* 2009 ; 91 : 1424-1430.
7. **Drexler M, Dwyer T, Chakraverty R *et al*.** The outcome of modified extended trochanteric osteotomy in revision THA for Vancouver B2/B3 periprosthetic fractures of the femur. *J Arthroplasty* 2014 ; 29 : 1598-1604.
8. **Duncan CP.** Periprosthetic fractures associated with joint replacement : our Tower of Babel ? *Bone Joint J* 2014 ; 96-B : 711-712.
9. **Duncan CP, Haddad FS.** The unified classification system (UCS) : improving our understanding of periprosthetic fractures. *Bone Joint J* 2014 ; 96-B : 713-716.
10. **Duncan CP, Masri BA.** Fractures of the femur after hip replacement. *Instr Course Lect* 1995 ; 44 : 293-304.
11. **Dzaja I, Lyons MC, McCalden RW *et al*.** Revision hip arthroplasty using a modular revision hip system in cases of severe bone loss. *J Arthroplasty* 2014 ; 29 : 1594-1597.
12. **Froberg L, Troelsen A, Brix M.** Periprosthetic Vancouver type B1 and C1 fractures treated by locking-plate osteosynthesis. *Acta Orthop* 2012 ; 83 : 648-652.
13. **Jensen JS, Barfod G, Hansen D *et al*.** Femoral shaft fracture after hip arthroplasty. *Acta Orthop Scand* 1988 ; 59 : 9-13.
14. **Johansson JE, McBroom R, Barrington TW, Hunter GA.** Fracture of the ipsilateral femur in patients with total hip replacement. *J Bone Joint Surg Am* 1981 ; 63 : 1435-1442.
15. **Landis JR, Koch GC.** The measurement of observe agreement for categorical data. *Biometrics* 1977 ; 33 : 159-174.

16. **Learmonth ID.** The management of periprosthetic fractures around the femoral stem. *J Bone Joint Surg Br* 2004 ; 86 :13-19.
17. **Lindahl H, Malchau H, Herberts P, Garellick G.** Periprosthetic femoral fractures classification and demographics of 1049 periprosthetic femoral fractures from the Swedish National Hip Arthroplasty Register. *J Arthroplasty* 2005 ; 20 : 857-865.
18. **Malchau H, Herberts P, Eisler T et al.** The Swedish total hip replacement register. *J Bone Joint Surg Am* 2002 ; 84-A Suppl 2 : 2-20.
19. **Naqvi GA, Baig SA, Awan N.** Interobserver and intra-observer reliability and validity of the Vancouver classification system of periprosthetic femoral fractures after hip arthroplasty. *J Arthroplasty* 2012 ; 27 : 1047-1050.
20. **Parrish TF, Jones JR.** Fracture of the femur following prosthetic arthroplasty of the hip : report of nine cases. *J Bone Joint Surg Am* 1964 ; 46 : 241-248.
21. **Rayan F, Dodd M, Haddad FS.** European validation of the Vancouver classification of periprosthetic proximal femoral fractures. *J Bone Joint Surg Br* 2008 ; 90 : 1576-1579.
22. **Roffman M, Mendes DG.** Fracture of the femur after total hip arthroplasty. *Orthopedics* 1989 ; 12 : 1067-1070.
23. **Van Houwelingen AP, Duncan CP.** The pseudo A (LT) periprosthetic fracture : it's really a B2. *Orthopedics* 2011 ; 34 : e479-481.
24. **Vioreanu MH, Parry MC, Haddad FS, Duncan CP.** Field testing the unified classification system for periprosthetic fractures of the pelvis and femur around a total hip replacement : an international collaboration. *Bone Joint J* 2014 ; 96-B : 1472-1477.