

CASE REPORT

PAROSTEAL OSTEOSARCOMA OF THE HUMERUS

F. STEENBRUGGE, B. POFFYN, D. UYTENDAELE, R. VERDONK, K. VERSTRAETE*

The authors report the case of a 50-year-old man who presented with nontraumatic swelling of the left upper arm. The diagnosis of parosteal osteosarcoma of the humerus was made after diagnostic workup. A long diaphyseal segment of the humerus containing the tumor was resected with a healthy margin of soft tissues and was irradiated extracorporeally with a single dose of 30 Gray. The bony segment was then reimplanted after removal of the tumor using plate and screw fixation. Loosening of the proximal screws after one year required additional fixation and autologous cancellous bone grafting. The patient has a nearly three-year-follow-up and there are no signs of tumor recurrence or metastasis. The proximal osteotomy has healed nicely; the distal fixation osteotomy exhibits delayed healing. The pathogenesis of parosteal osteosarcoma is discussed.

Keywords : parosteal osteosarcoma ; extracorporeal irradiation ; irradiated autograft.

Mots-clés : ostéosarcome parostéal ; irradiation extracorporelle ; autogreffe irradiée.

CASE PRESENTATION

About 2 months before presentation a 50-year-old man had noticed diffuse swelling and progressive loss of motion of the left shoulder and upper arm. There was no history of trauma. Physical examination revealed a large, firm mass at the anterolateral aspect of the left upper arm. Circulation, sensation, and function of the left hand were normal.

Radiologic examination of the left humerus and shoulder (fig. 1) disclosed a large calcified mass of heterogeneous density encircling the humerus. A

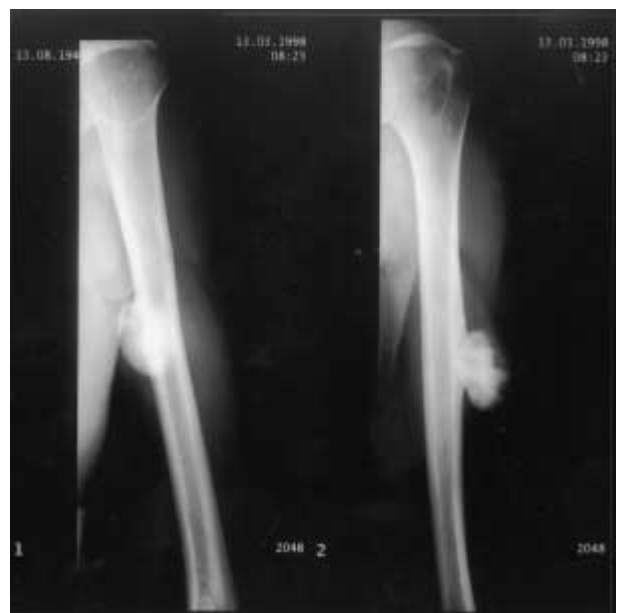

Fig. 1. — Anteroposterior xray of the left shoulder and humerus showing a large, homogeneous, sharp and irregularly delineated, densely calcified mass abutting the humerus.

Tc- methylene diphosphonate (MDP) scintigram (fig. 2) showed markedly increased tracer uptake in the mass. Cortical destruction and infiltration of adjacent structures by the juxtacortical humeral mass were observed on CT (fig. 3).

Department of Orthopedic Surgery and *Department of Radiology, Ghent University Hospital, B-9000 Gent, Belgium
Correspondence and reprints : F. Steenbrugge, Dept. of Orthopedic Surgery and Trauma, UZ-Gent, De Pintelaan 185, B-9000 Gent, Belgium.

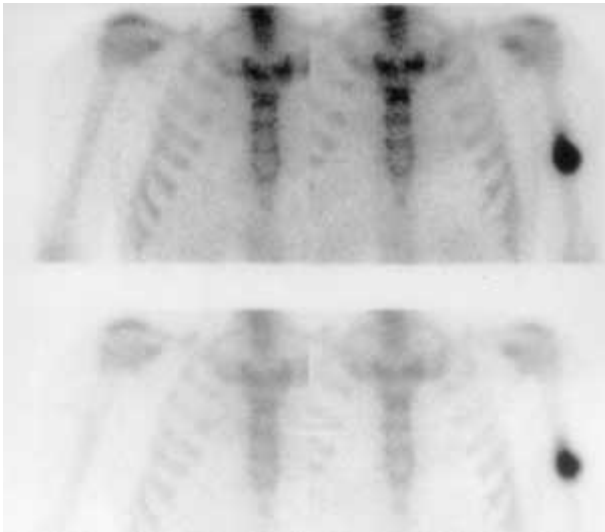


Fig. 2. — Tc-methylene diphosphonate (MDP) scintigram of the chest and upper extremities discloses markedly increased tracer uptake in the mass at the left humerus.

The extent of the tumor was delineated by MR examination. The proton density T2/T1-weighted, contrast T1 ;Gd - DTPA images (fig. 4) showed that the mass was connected by a small stem to the ventral aspect of the humerus. The lesion extended to the endosteum. There was invasion of the cortex and of the brachialis muscle. The tumor was 2.5 × 3 cm in diameter. At its base it measured 10 cm in length. The neurovascular structures were not involved. No tumor nodules were seen in the bone marrow. The imaging findings were diagnostic of a parosteal osteosarcoma. The laboratory investigations were normal.

A long diaphyseal segment of the humerus containing the tumor was resected, along with the insertion of the brachialis muscle. The biceps, triceps and deltoid muscles were free of tumor invasion. The resected humerus was irradiated extracorporeally with a dose of 30,000 rads (30 Gray) (13) and then reimplanted after removal of the tumor using plate and screw fixation (fig. 5). Transport and irradiation took about one hour, during which time the remaining bone was prepared for repair. The pathology report confirmed the diagnosis of parosteal osteosarcoma. There were no complications. Immediate postoperative rehabilitation consisted of pendulum exercises. One

year postoperatively there were no signs of tumor recurrence or metastasis. The range of motion of the shoulder showed active abduction and elevation of 70°. The elbow had an extension lag of 30° and full pronation and supination. The xray showed loosening of the proximal screws and an additional fixation was performed together with autologous cancellous grafts. At two-years follow-up there were no signs of tumor recurrence or metastasis. Nonunion seemed to have developed at the distal fixation site (fig. 6). The range of motion of the shoulder was satisfactory, and there were only minor pain complaints. The patient now has nearly three-years follow-up and there are still no signs of tumor recurrence or metastasis. The proximal osteotomy has healed up nicely. The latest xrays now show good callus formation at the distal osteotomy (fig. 7). The range of motion of the shoulder is satisfactory and clinical examination confirmed a solid fusion of the distal fixation site. In the event of plate failure and breakage, revision surgery with plate and screw fixation of the humerus and autologous bone grafts might offer a solution. A fibular graft can provide a massive bone graft. Intramedullary fixation with a rigid nail or filling of the medullary cavity with flexible nails or K-wires is a valid alternative.

DISCUSSION

Four percent of all osteosarcomas are surface or juxtacortical in location and have generally been subdivided into three types : parosteal, periosteal and high-grade surface osteosarcomas. Although some pathologists considered all juxtacortical osteosarcomas as a single category, others have described different clinical, radiologic, and pathologic findings of the individual subtypes that could potentially change surgical and chemotherapeutic management of these tumors. Parosteal osteosarcomas can be divided in grades 1 and 2 and a dedifferentiated variant (secondary grade 3) (9). Parosteal osteosarcoma is a rare, slow-growing, malignant, bone-forming neoplasm that arises from the surface of long bones. It has a better prognosis than conventional central osteosarcomas and other subperiosteal osteosarcomas (3, 11).

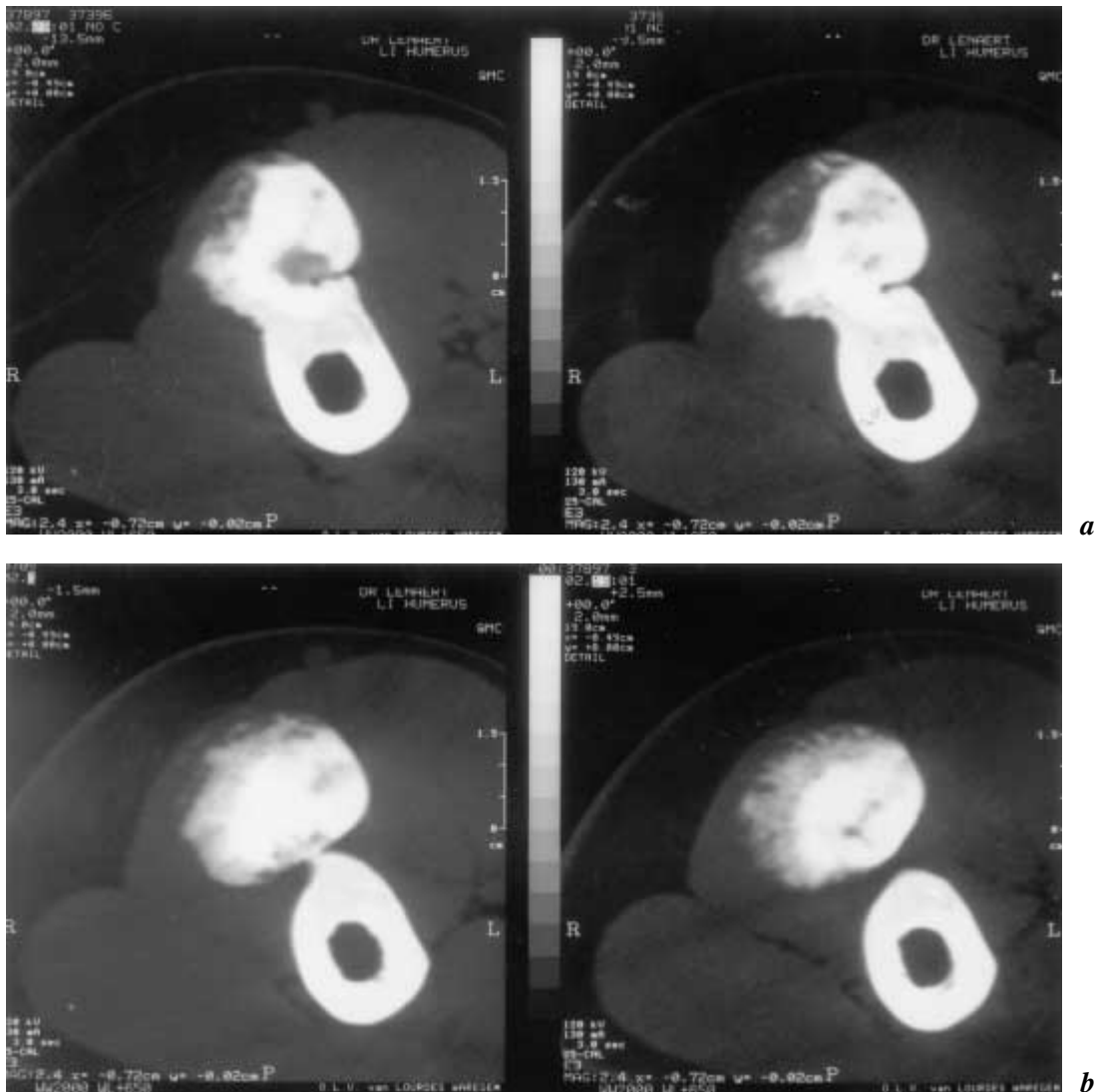


Fig. 3 (a, b). — CT-scan of the left humerus. Extension towards the cortex and infiltration of the soft tissues by the juxtacortical mass are visible (a). It also shows the connection between the mass and the humerus by a small stem (b).

Patients are generally affected in the second to fifth decades of life. They usually have gradual onset of pain, swelling, and a palpable mass (3, 11). The indolent behavior of the tumor delays the diagnosis. Parosteal osteosarcomas were considered by some investigators to always be completely low-grade lesions. In some studies however, it has been claimed that 22-64% of parosteal osteosarcomas may contain components with degrees of anaplasia. This has led to some controversy as to how to distinguish parosteal osteosarcoma from high-grade surface osteosarcoma. Mirra reported on 3 cases of

24 in a series where slow-growing, grade 1 lesions transformed into explosively growing, high-grade 3 osteosarcomas. In 2 of the 3 cases, death from disseminated metastases occurred within two years of diagnosis (6, 9).

As illustrated in this case, the tumor may attain an enormous size before the patient seeks medical advice (11, 13). Radiologic and histologic misdiagnosis as benign osteochondroma (11) may result in inadequate surgical resection of the tumor.

The lesion most often arises from the metaphysis of a tubular bone, occasionally from the epiphysis,

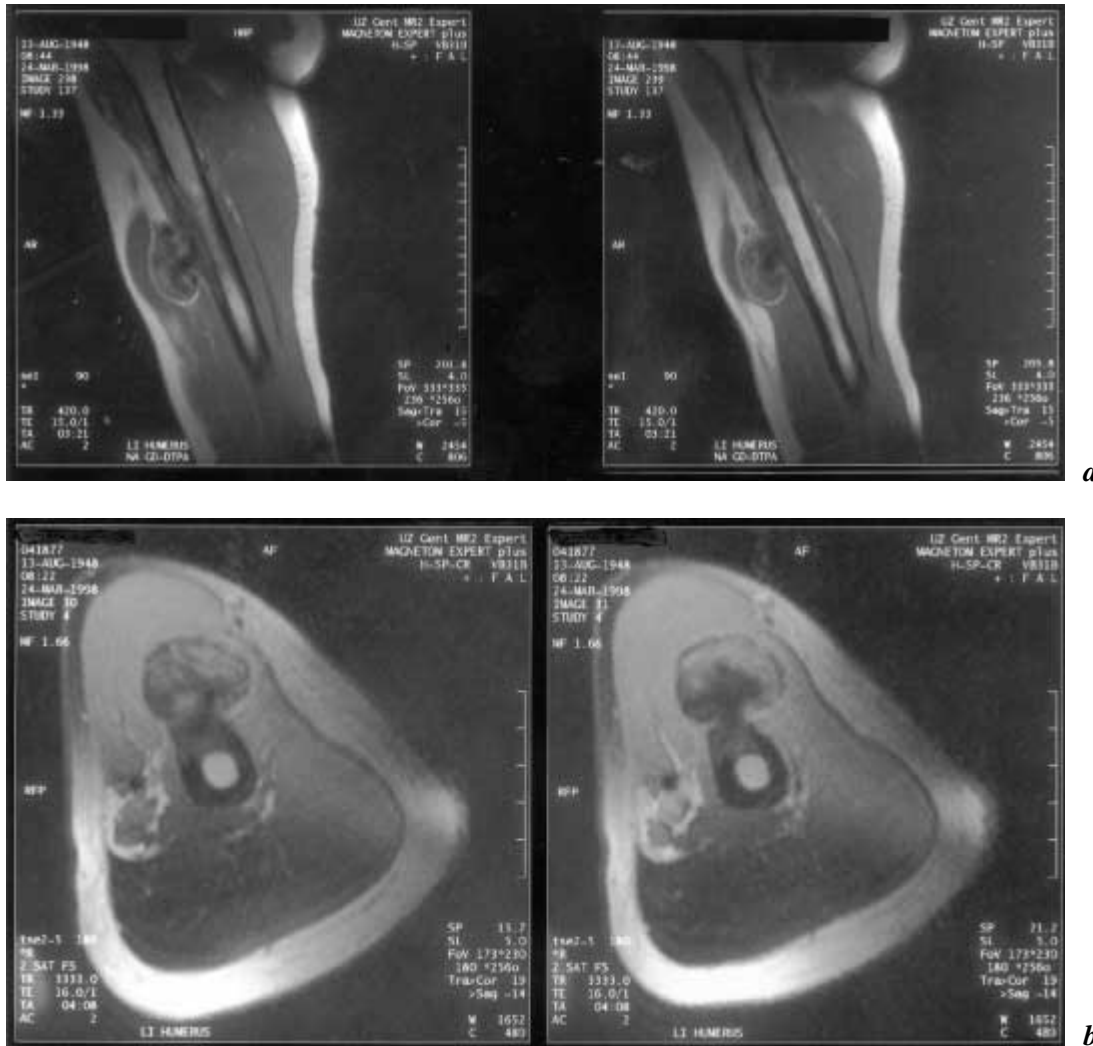


Fig. 4 (a, b). — Sagittal contrast-enhanced T1-weighted (a) and axial proton-density weighted (b) MR-images of the left upper arm. The tumoral mass is connected by a small stem to the ventral aspect of the humerus. The lesion extends to the endosteum. There is invasion of the cortex and of the brachialis muscle. The tumor is 2.5 × 3 cm in diameter and measures 10 cm at its base. The neurovascular structures are not involved. There are no tumor nodules apparent in the bone marrow.

and rarely from the diaphysis (11, 13). The most common location is the posterior aspect of the distal femur, followed by the proximal humerus, the tibia, fibula and ulna (11). This malignant neoplasm grows circumferentially along the cortex of the involved bone, eventually enveloping the bone shaft. Cortical destruction and neoplastic invasion of the medullary cavity are uncommon except in cases with prior treatment or a long history of growth. On radiographs, early parosteal osteosarcomas are radiodense, lobulated, or oval masses

with a broad-based attachment to the external cortex. A thin, radiolucent cleavage plane between the tumor and the underlying bone is a characteristic but not a constant finding (7, 11, 12). Progressive growth of the tumor may obliterate this plane. This tumor ossifies from the base of the lesion to its periphery in contrast to myositis ossificans, which initially ossifies from the periphery (3, 11, 13). The differential diagnosis of a less advanced case of parosteal osteosarcoma includes subperiosteal osteosarcoma, osteochondroma, myositis

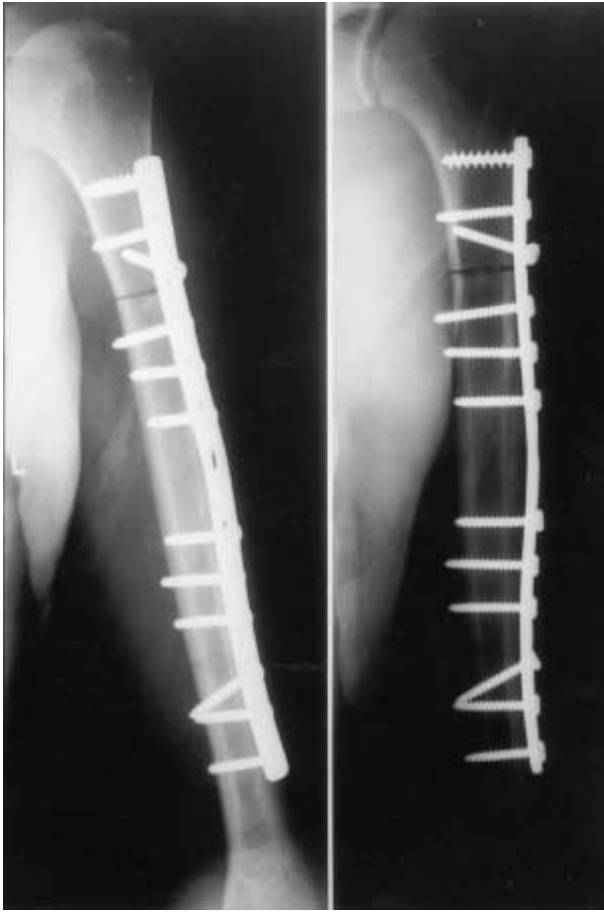


Fig. 5. — Anteroposterior xray of the left humerus after resection of the tumor, extracorporeal irradiation of the resected diaphyseal part and reimplantation using plate and screw fixation.

ossificans, central osteosarcoma, extraosseous osteosarcoma, ossifying or calcifying hematoma, and exuberant callus (7, 13). Plain radiography is often diagnostic. CT and MR studies assist in delineating the extent of the process and in preoperative planning. Treatment options are surgical resection leaving the humerus in continuity or segmental resection using allografts (1, 2). The margins can be defined as intracapsular, marginal, wide or radical. An intracapsular margin is defined as one in which the capsule of the lesion is entered and some portion of the dissection is done within the lesion. A marginal margin is one in which the plane of dissection passes within the reactive zone lying between the capsule of the lesion and the surrounding normal tissue. A wide margin is one in

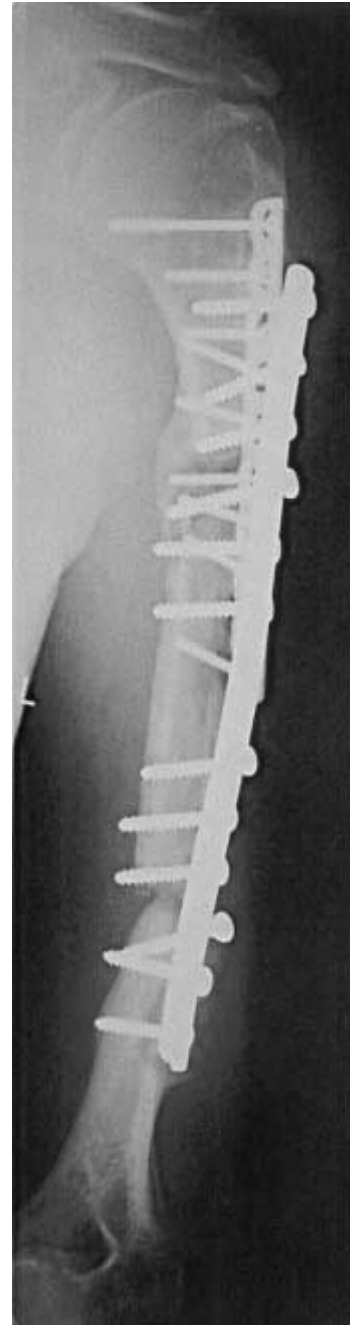

Fig. 6. — Anteroposterior xray of the left humerus at two years of follow-up. It shows the additional osteosynthesis at the proximal site after loosening had occurred. Good callus formation has developed there. The distal fixation site is ununited.

which normal non-reactive tissue forms the boundary zones of the specimen that is removed. A radical margin is tumor-free and contains tissue that is

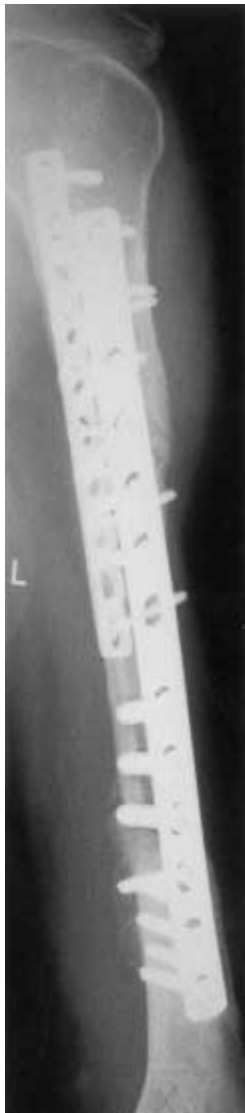


Fig. 7. — Anteroposterior xray of the humerus at nearly three years of follow-up. The distal fixation site finally shows callus formation.

non-reactive or normal tissue that includes the entire bone or muscle groups, or both, involved by the lesion. Enneking concluded in his study that for low-grade parosteal osteosarcomas of the long bones, intracapsular removal, whether through diagnostic or surgical error, carries an almost universal risk of recurrence (2). Marginal resection carries a significant risk of recurrence, approximately 50%. However, the risk of recurrence after a purposeful localized marginal margin is substan-

tially lower than a more extensive marginal resection obtained because of diagnostic or surgical error. A wide procedure, whether resection or amputation, carries a negligible risk of recurrence. A radical procedure, while practically risk-free, is not necessary for successful treatment. The treatment of choice remains wide 'en bloc' resection with a margin of healthy tissue. Amputation should be reserved for those lesions that appear unresectable by any other method, are recurrent, or are grade 3. After resective procedures, short of amputation, the patient should have periodic examinations throughout his lifetime for potential recurrence; as many as 41 years may elapse between therapy and first recurrence (9).

Reconstruction of the lesion can be done using an allograft and fixation materials, a non-vascularized fibular graft, a vascularized fibular graft or, as in this case, an irradiated autograft. Chemotherapy and irradiation have no place in the treatment of parosteal osteosarcomas; irradiation can always turn the lesion more malignant. The technique of extracorporeal irradiation and reimplantation has been used for several years in our department (13). It offers the advantage of anatomic matching margins when reimplanting the resected bone, it avoids the problem of early and late loosening or breakage of a massive prosthesis and it also obviates some of the problems of allografting, such as the rejection of a graft. There are potential complications, which include skin necrosis, infection, and partial resorption of the massive, dead autograft. However, these are no worse than those produced by allografting, while function is largely satisfactory in most cases (13). The surgical approach is similar to any other approach used for treating these conditions. During surgery, the resected bony segment is cleared of any attached soft tissues. It is then sent away in a sterile packing for extracorporeal irradiation with a single dose of 30 Gray. This takes about one hour, during which time the remaining bone is prepared for reimplantation of the removed segment. The latter is then reimplanted after removal of the tumor, using plate and screw fixation, although this technique can also be applied with prosthetic implants if a joint is involved. There can be a marked discrepancy

between the clinical and radiographic findings on follow-up. These sometimes show a grotesque image produced by necrosis and remodelling. The loosening of the osteosynthesis at the proximal site was in this case probably due to this phase of necrosis and remodelling. The risk of developing nonunion at the distal fixation site might have been reduced by using autologous cancellous grafts at the time of the initial surgery. Because the function of the arm is satisfactory and final xrays show callus formation, no further surgery is planned at this moment.

CONCLUSION

Segmental resection, extracorporeal irradiation and reimplantation provided an interesting alternative to allografting or even prosthetic replacement in this case. There are minor pain problems and the radiographic appearances in this case are somewhat poor. Nevertheless the functional outcome after nearly three years is satisfactory.

REFERENCES

1. Campanacci M., Picci P., Gherlinzoni F., Guerra A., Bertoni F., Neff J. Parosteal osteosarcoma. *J. Bone Joint Surg.*, 1984, 66-B, 313-321.
2. Enneking W., Springfield D., Gross M. The surgical treatment of parosteal osteosarcoma in long bones. *J. Bone Joint Surg.*, 1985, 67-A, 125-135.
3. Hudson T. M., Springfield D. S., Benjamin M., Bertoni F., Present D. A. Computed tomography of parosteal osteosarcoma. *Am. J. Radiology*, 1985, 144, 961-965.
4. Jelinek J. S., Murphey M. D., Kransdorf M. J., Shmooker B. M., Malawer M. M., Hur R. C. Parosteal osteosarcoma : Value of MR imaging and CT in the prediction of histologic grade. *Radiology*, 1996, 201, 837-842.
5. Kenan S., Abdelwahab I. F., Klein M. J., Hermann G., Lewis M. M. Parosteal osteosarcoma involving the left radius : Case report 835. *Skeletal Radiol.*, 1994, 23, 229-231.
6. Lemaire R., Mommens J. P. Potentialités évolutives du sarcome osseux juxta-cortical. *Acta Orthop. Belgica*, 1979, 45, 173-185.
7. Lindell M. M., Shirkhoda A., Raymond A. K., Murray J. A., Harle T. S. Parosteal osteosarcoma : Radiologic-pathologic correlation with emphasis on CT. *Am. J. Radiology*, 1987, 148, 323-328.

8. Matsumoto K., Okabe H., Asano Y. Parosteal (juxtacortical) chondrosarcoma of the humerus associated with regional lymph node metastasis. A case report. *Clin. Orthop.*, 1993, 290, 168-173.
9. Mirra J. M., Picci P., Gold R. Parosteal sarcomas : Bone Tumors, Clinical, Radiologic and Pathologic Correlations, Vol. 2, Lea and Febiger, 1989, pp. 1686-1725.
10. Resnick D., Kyriakos M., Greenway G. D. Tumors and tumor-like lesions of bone : Imaging and pathology of specific lesions : Resnick D., Niwayama G., eds. *Diagnosis of Bone and Joint Disorders*, Philadelphia : Saunders, 1988, pp. 3648-3677.
11. Schajowicz F., McGuire M. H., Araujo E. S., Muscolo D. L., Gitelis S. Osteosarcomas arising on the surfaces of long bones. *J. Bone Joint Surg.*, 1988, 70-A, 555-564.
12. Smith J., Ahuja S. C., Huvos A. G., Bullough P. G. Parosteal (juxtacortical) osteogenic osteosarcoma : a roentgenological study of 30 patients. *J. Can. Assoc. Radiol.*, 1978, 29, 167-175.
13. Uyttendaele D., De Schrijver A., Claessens H., Roels H., Berkvens P. Limb conservation in primary bone tumors by resection, extracorporeal irradiation and reimplantation. *J. Bone Joint Surg.*, 1988, 70-B, 348-353.
14. Van Ongeval C., Lateur L., Baert A. L. Parosteal osteosarcoma. *Belg. Tijdschr. Radiol.*, 1993, 76, 173-175.

SAMENVATTING

F. STEENBRUGGE, B. POFFYN, D. UYTENDAELE, R. VERDONK, K. VERSTRAETE. Parosteaal osteosarcoma van de humerus : een gevalsbeschrijving.

De auteurs beschrijven het verhaal van een 50-jarige man die zich aanbood met een niet-traumatische zwelling van de linker bovenarm. De diagnose van een parosteaal osteosarcoma werd gesteld na de investigaties. Het diafysair segment van de humerus dat de tumor bevatte werd gereceerd met een brede marge van gezond weefsel en extracorporeel bestraald met een éénmalige dosis van 30 Gray. Het segment werd dan gereïmplanteerd na verwijderen van de tumor met behulp van plaat- en vijsfixatie. Falen van de proximale vijsfixatie na één jaar noodzaakte een revisie-ingreep met autologe cancellouse botgreffes en een bijkomende plaat. De patient heeft nu bijna drie jaar opvolging en er zijn nog steeds geen tekens van tumorrecurrentie of metastasen. De proximale fixatie van de plaat lijkt geheeld te zijn. De distale fixatie van de plaat toont enkelijk tekens van callusvorming. De pathogenese van een parosteaal osteosarcoma wordt besproken.

RÉSUMÉ

F. STEENBRUGGE, B. POFFYN, D. UYTENDAELE, R. VERDONK, K. VERSTRAETE. Ostéosarcome parostéal de l'humérus : présentation d'un cas.

Les auteurs rapportent le cas d'un homme de 50 ans qui s'est présenté avec une tuméfaction d'origine non traumatique du bras gauche. Le diagnostic d'ostéosarcome parostéal a été posé après mise au point. Le segment diaphysaire de l'humérus portant la tumeur a été résecté et soumis à une irradiation extracorporelle avec une dose

unique de 30 Gray. Le segment a été réimplanté après résection de la tumeur et fixé par plaque vissée. Un an plus tard, une reprise de l'ostéosynthèse proximale avec apport d'os spongieux autologue et mise en place d'une plaque supplémentaire s'est avérée nécessaire. Le patient a maintenant presque trois ans de recul. Il n'y a aucun signe de récurrence tumorale ou de métastases. L'ostéotomie proximale est consolidée. L'ostéotomie distale a évolué très lentement vers la consolidation, et montre finalement un cal unitif. La pathogénie de l'ostéosarcome parostéal est discutée.