



Efficacy of the Wallis interspinous implant for primary lumbar disc herniation : a prospective randomised controlled trial

Honglin GU*, Yunbing CHANG*, Shixing ZENG, Yonghong GAO, Shiqiang ZHAN, Qiuqian ZHENG

From the Department of Orthopedics, Guangdong Academy of Medical Sciences, Guangdong General Hospital, Guangzhou, P.R. China

Purpose : To investigate the efficacy of the Wallis implant after lumbar discectomy compared with discectomy alone for primary lumbar disc herniation. Seventy-seven patients with primary lumbar disc herniation were randomly assigned to undergo either posterior lumbar discectomy with (n=40, Wallis group) or without (n=37, control group) Wallis implantation. The primary outcomes were visual analogue scale score, Japanese Orthopedics Association score, and Oswestry Disability Index. The secondary outcomes were intervertebral disc height, range of motion of the operated segments, complications, and operating time.

The primary outcomes at 1 week after treatment ($P>0.05$) were not different between groups. The Wallis group had better scores at 12 months ($P<0.05$) and the last follow-up visit ($P<0.05$), higher disc height ($P<0.001$), and significantly longer operating time ($P=0.006$) than the control group.

Combined treatment appears beneficial for pain relief and lumbar function improvement by maintaining intervertebral disc height and limiting the range of motion of the spine compared with lumbar discectomy alone. However, its actual clinical benefit remains controversial because of the longer operating time and the relatively small difference in the visual analogue scale score and Oswestry Disability Index between the groups.

Keywords : lumbar disc herniation ; interspinous dynamic stabilization ; Wallis implant ; discectomy.

** The authors contributed equally to this manuscript. No benefits or funds were received in support of this study. The authors report no conflict of interest.*

INTRODUCTION

Lumbar disc herniation (LDH) is the most common cause of low back or radicular leg pain in working adults (6). Partial discectomy or total discectomy with or without fusion is the most commonly used surgical procedure for LDH, but has several limitations. Although disc degeneration is a natural, temporal consequence of LDH (16), discectomy results in subsequent lumbar disc degeneration such

- Honglin Gu (Orthopedic Surgeon).
- Yunbing Chang, M.D. (Professor).
- Shixing Zeng (Associate Professor).
- Yonghong Gao (Supervising Nurse).
- Shiqiang Zhan (Professor)

Department of Orthopedics, Guangdong Academy of Medical Science, Guangdong General Hospital, Guangzhou, P.R. China.

- Qiuqian Zheng (Professor).

Department of Orthopaedics, Guangdong Academy of Medical Sciences, Guangdong General Hospital – 106 Zhongshan Road II, Guangzhou, 510080, P.R. China.

Correspondence : Shiqiang Zhan, Department of Orthopedics, Guangdong Academy of Medical Sciences, Guangdong General Hospital, 106 Zhongshan Road II, Guangzhou, 510080, P.R. China. Telephone : (8620) 83827812 ; (86) 13503080806. E-mail : sygkspine@gmail.com.

Qiuqian Zheng, Department of Orthopaedics, Guangdong Academy of Medical Sciences, Guangdong General Hospital, 106 Zhongshan Road II, Guangzhou, 510080, P.R. China. Telephone : (8620) 83827812 ; (86) 13802740561. E-mail : zqj650@126.com.

- © 2017, Acta Orthopædica Belgica.

as intervertebral disc height loss and segmental instability, leading to failed back surgery syndrome or recurrent LDH (27). Lumbar fusion may have satisfactory intermediate-term results, but has side effects such as pseudarthrosis, bone-graft morbidity, pedicle screw-related complications, and adjacent segment degeneration (ASD) (8,10). To prevent postoperative complications, recent attempts focus on the maintenance of normal load transmission across the degenerated disc region and encourage spine movement. Thus, a number of dynamic implants have been invented and tested for the treatment of LDH.

The Wallis interspinous dynamic stabilization implant was designed to stiffen unstable treated degenerative lumbar segments while maintaining motion (23). The current Wallis implant consists of an interspinous blocker made of polyetheretherketone to restrict extension. Two Dacron tapes are wound around the spinous processes to fix the implant and restrict flexion (23). The implant unloads the facet joints, restores foraminal height, preserves motion in the operated lumbar segment with sufficient stability, and allows young patients to engage in daily physical activities (12,23). Magnetic resonance imaging (MRI) demonstrated the implant's capacity to induce rehydration of the degenerated nucleus pulposus (21), and possibly decrease the incidence of recurrent LDH (5).

Previous clinical trials and biomechanical studies confirmed the long-term safety and efficacy of the Wallis implant (22,29). Prospective control trials performed by Senegas, et al. and Korovessis, et al. have demonstrated better clinical outcomes for preventing recurrent LDH and the fusion of cephalad adjacent unfused vertebra (10,12). However, to the best of our knowledge, this is the first prospective study that aimed to determine whether lumbar discectomy combined with Wallis implant fixation is more effective than discectomy alone for the treatment of primary LDH.

PATIENTS AND METHODS

Patients

Between July 2008 and July 2011, we recruited patients with primary LDH who fulfilled the

inclusion criteria and provided written informed consent at our orthopaedics department. The diagnosis of LDH was based on an adaptation of the following diagnostic criteria created by McCulloch (17): (1) Dominating symptom of leg pain that follows a typical sciatic or femoral nerve distribution; (2) Paresthesia localized in a dermatomal distribution; (3) Straight-leg raising test is positive and reduced by 50% of normal in symptomatic leg and/or unaffected leg; (4) Presence of two of the 4 neurologic signs (wasting, motor weakness, diminished sensory appreciation, or diminution of reflex activity); and (5) Positive contrast study corresponding to the clinical level.

The inclusion criteria were as follows :

- (1) Age, 18-70 years old
- (2) Low back pain or sciatica
- (3) Disc herniation or spinal stenosis caused by herniation at the responsible level
- (4) No symptomatic improvement after 6–10 weeks of non-surgical treatment

Exclusion criteria were as follows :

- (1) Previous operations of lumbar
- (2) Congenital spinal deformity
- (3) Lumbar fracture
- (4) Infection including preoperative lumbar discitis or systemic infection
- (5) Autoimmune diseases
- (6) Serious osteoporosis confirmed by dual-energy X-ray absorptiometry (T score <-1.0)
- (7) Morbid obesity (body mass index > 40 kg/m²; National Institutes of Health Clinical Guidelines on body mass index)
- (8) L5/S1 herniation

Ethics statement and trial protocol registry

The study was approved by the Research Ethics Committee of Guangdong General Hospital, Guangdong Academy of Medical Sciences, P.R. China (No.GDREC2012040H). All human participants provided written informed consent and all clinical investigations were conducted according to the principles of the Declaration of Helsinki. The trial protocol was registered in Clinical trial.gov

(Name of the registry : Wallis Interspinous Dynamic Stability System for Lumbar Disc Herniation : a Prospective Study ; Registration number : NCT01824 108 ; URL : <http://clinicaltrials.gov/ct2/show/NCT01824108?term=wallis&rank=1>). The authors confirm that all on-going and related trials for this intervention have been registered accordingly.

Study design

The patients were randomly assigned to either the Wallis group or the control group by a computer-generated master randomisation list using 1 : 1 allocation. A nurse who did not participate in the diagnosis, treatment, or data analysis conducted the randomisation at a central registry. The patients in the Wallis group underwent lumbar discectomy combined with Wallis implant insertion, while the patients in the control group underwent lumbar discectomy alone. Double blind and double dummy techniques were not used because of the nature of the treatments. Treatment was discontinued if any of the exclusion criteria were applicable, or as per patient's request.

Sample size estimation

The sample size calculation was based on the published postoperative ODI of the Wallis group and control group (21). A sample size of at least 34 patients was required for each group to give 90% power for a type I error of 5% (two-sided), desiring effect size of 0.81. To adjust for a 10% loss to follow-up, we planned to include at least 76 patients (38 patients for each group).

Surgical technique

The operations were performed by the same team of orthopaedic surgeons. Lamina and herniated disc fragment removal as well as nerve root decompression were initially accomplished through a unilateral transflaval approach. In an attempt to lower the recurrence rate, a box-shaped incision was created with a scalpel in the annulus fibrosus, followed by removal of all free fragments in the disc space while leaving the annulus fibrosus in place

(28). For patients in the control group, the wound was then closed with a suction drain.

The Wallis implant was placed after discectomy. The surgical technique used was described earlier by Korovessis [for details see (12)] .

Postoperative care

The patients were encouraged to begin walking with a lumbar orthosis on the second postoperative day. Isometric exercises were prescribed to maintain the muscle tone of the trunk. The lumbar orthosis was removed after 3 weeks and patients were instructed to undergo rehabilitation to train the lower back muscles. Follow up was conducted at our rehabilitation unit at 6 and 12 months, and every 12 months thereafter.

Outcome measurement

The primary outcomes were the visual analogue scale (VAS) score, Japanese Orthopedics Association (JOA) score, and the Oswestry Disability Index (ODI). VAS was used to assess the back and leg pain, and lumbar function was evaluated using the ODI and JOA questionnaires. An independent assessor gathered the questionnaires 2 days before the operation as well as during the postoperative evaluations scheduled at 1 week, 6 and 12 months, and every 12 months after the first year.

The secondary outcomes of interest were as follows : (1) Intervertebral disc height (DH) of the operated segments (the average of the anterior and posterior disc heights) ; (2) Range of motion (ROM) of the operated segments (measured on flexion-extension radiographs using Cobb method) ; (12). (3) Postoperative complications such as dural lacerations, deep infections, recurrent LDH, lumbar kyphosis, and spinous process fractures (5,12,14,21,25) ; and (4) operating time.

Plain radiographs, including anteroposterior standing and lateral standing views of the lumbar spine, were taken for evaluation of the secondary outcomes. The flexion and extension views of the lumbar spine were taken at each follow-up examination except at 1 week after treatment because of activity restriction in the early stage.

Lumbar function was determined by measuring intervertebral DH and ROM of the operated segments. To identify recurrent LDH or disc degeneration, magnetic resonance imaging (MRI) was also performed 2 days before the operation and every 12 months after the first postoperative year. The fellows and research nurses recorded the operating time for each patient and the complications at each follow-up moment. Preoperative and postoperative data were compared.

Statistical analysis

The statistical analyses were performed using the SPSS statistical software (version 15.0 ; SPSS, Inc., Chicago, Illinois, USA, 2006). The categorical data were described as absolute numbers and analysed using the chi-square test (exact probability test). The numeric data were described as mean±standard error (SE). The T test was used to analyse age, average follow-up period, operating time, and preoperative clinical and radiographic parameters. After adjusting for sex distribution and operating time, multivariate analysis of variance was used

to show the changes of each parameter in a group and the differences in a parameter between the two groups. All statistical tests were two-sided, and a significant difference was considered when $P < 0.05$.

RESULTS

Enrolment

Between July 2008 and July 2011, 80 patients with primary LDH were admitted in our hospital and screened for study eligibility. One patient was excluded due to discitis, while 2 patients refused to participate in the study. Seventy-seven participants were randomised to the 2 treatment groups. Forty patients underwent Wallis implant insertion following lumbar discectomy, while 37 patients were treated with lumbar discectomy alone (Fig. 1).

Table I illustrates the demographic data and baseline evaluation of patients included in the study. There were no significant differences in the age, sex, operated segments, average follow-up

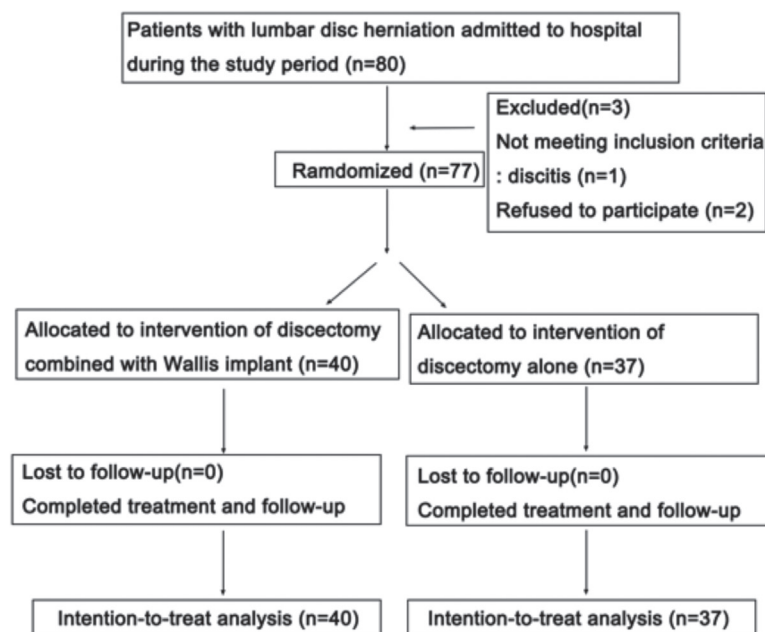


Fig. 1. — CONSORT flow diagram of the trial

Table I. — Demographic data and baseline evaluation of the patients

Characteristic		Wallis group (n=40)	Control group (n=37)	P
Age (year) (mean± SE)		41.98±1.62	38.89±1.68	0.191
Gender	Male	18	24	0.080
	Female	22	13	
Operated segments	L3/4	3	1	0.343
	L4/5	37	36	
Time of surgery (min) (mean± SE)		78.40±2.11	69.67±2.29	0.006
Follow-up time (months) (mean± SE)		24.55±0.93	24.02±0.83	0.676
VAS (mean± SE)		79.50±2.01	77.84±2.09	0.557
JOA (mean± SE)		8.05±0.50	8.70±0.52	0.337
ODI (mean± SE)		68.02±2.60	65.84±2.36	0.893
DH of the operated segment (mm) (mean± SE)		11.21±0.31	11.04±0.32	0.364
ROM of the operated segment (degree) (mean± SE)		25.65±1.59	26.17±1.66	0.953

time, preoperative VAS score, JOA score, and ODI as well as DH and ROM of the operated segments between the groups. However, the duration of the operation was significantly longer in the Wallis than in the control group ($P = 0.006$).

Clinical outcomes

The baseline VAS scores were 79.50 ± 2.01 in the Wallis group and 77.84 ± 2.09 in the control group ($P=0.557$). In the Wallis group, this pain index significantly decreased after treatment (17.25 ± 1.18 at 1 week, 9.38 ± 1.37 at 12 months, and 8.38 ± 1.27 at the last follow-up visit ; $P < 0.001$). Pain also improved immediately with lumbar discectomy alone (VAS score : 18.24 ± 1.23 at 1 week, 16.62 ± 1.43 at 12 months, and 12.70 ± 1.32 at the last follow-up visit ; $P < 0.001$). There was no statistical difference between the two groups in the VAS score after the first postoperative week ($P=0.572$), while statistically significant differences were found at 12 months and at the last follow-up visit ($P=0.001$ and $P=0.020$, respectively) (Fig. 2).

The baseline JOA scores were 8.05 ± 0.50 in the Wallis group and 8.70 ± 0.52 in the control group ($P=0.337$). In patients in the Wallis group, this lumbar function index significantly improved after treatment (22.53 ± 0.54 at 1 week, 25.55 ± 0.53 at 12 months, and 25.58 ± 0.48 at the last follow-up

visit ; $P < 0.001$). Lumbar function also improved significantly in the control group (22.92 ± 0.56 at 1 week, 23.57 ± 0.55 at 12 months, and 23.68 ± 0.50 at the last follow-up visit ; $P < 0.001$). There was no statistical difference between the two groups after the first postoperative week ($P=0.763$), while statistically significant differences were found at 12 months and at the last follow-up visit ($P=0.018$ and $P = 0.008$, respectively) (Fig. 3).

The preoperative ODI was 68.02 ± 2.60 in the Wallis group and 65.84 ± 2.36 in the control group ($P=0.893$). This disability index significantly decreased in the Wallis group (20.91 ± 2.19 at 1 week, 12.18 ± 1.96 at 12 months, and 11.78 ± 1.94 at the last follow-up ; $P < 0.001$). A decrease in the disability index was also found in the control group (23.07 ± 2.28 at 1 week, 19.44 ± 2.04 at 12 months, and 18.91 ± 2.01 at the last follow-up visit ; $P < 0.001$). There was no statistical difference between the groups after the first postoperative week ($P=0.243$), while statistically significant differences were found at 12 months and at the last follow-up visit ($P = 0.011$ and $P = 0.012$, respectively) (Fig. 4).

Radiographic outcomes

The baseline DH of the operated segment was 11.21 ± 0.31 mm in the Wallis group and 11.04 ± 0.32 mm in the control group ($P = 0.364$). In the Wallis

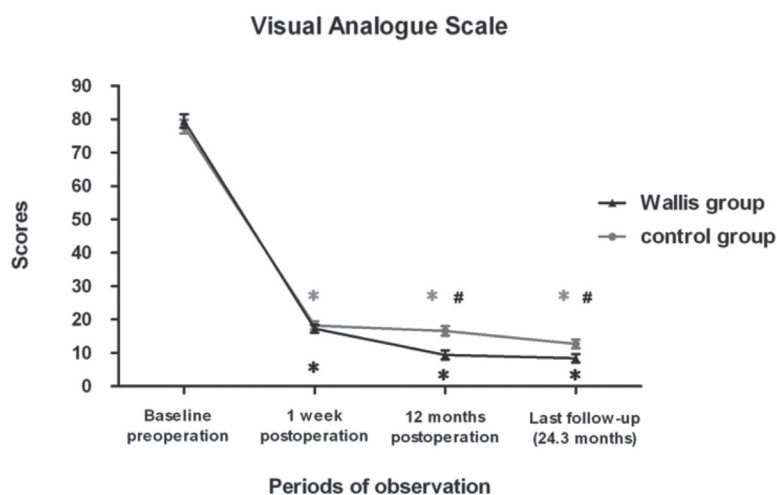


Fig. 2. — VAS score changes at the last follow-up visit. * $P < 0.05$ comparing with baseline ; # $P < 0.05$ for comparisons between the Wallis group and control group

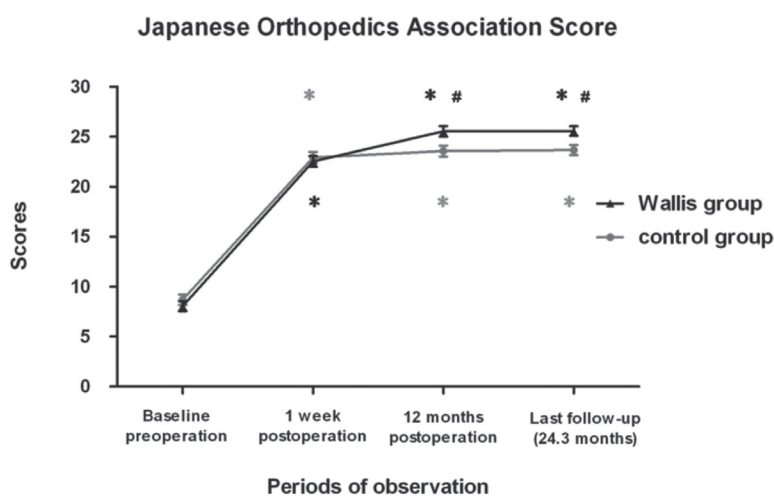


Fig. 3. — JOA score changes at the last follow-up visit. * $P < 0.05$ comparing with baseline ; # $P < 0.05$ for comparisons between the Wallis group and the Control group

group, the DH improved significantly after the first postoperative week (12.90 ± 0.29 mm, $P < 0.001$), but did not change at 12 months (11.36 ± 0.31 mm, $P = 1.0$) and at the last follow-up visit (11.31 ± 0.30 mm, $P = 1.0$) compared with the preoperative data. In the control group, the DH did not change after the first postoperative week (11.34 ± 0.30 mm, $P = 0.310$), but it decreased significantly at 12 months and at the

last follow-up visit (9.56 ± 0.32 mm and 9.29 ± 0.32 mm, respectively ; $P < 0.001$). The Wallis group had higher DH than the control group at each follow-up visit ($P < 0.001$, $P < 0.001$, $P < 0.001$, respectively) (Fig. 5).

The baseline ROM of the operated segment was $25.65^\circ \pm 1.59^\circ$ in the Wallis group and $26.17^\circ \pm 1.66^\circ$ in the control group ($P = 0.953$). In the Wallis

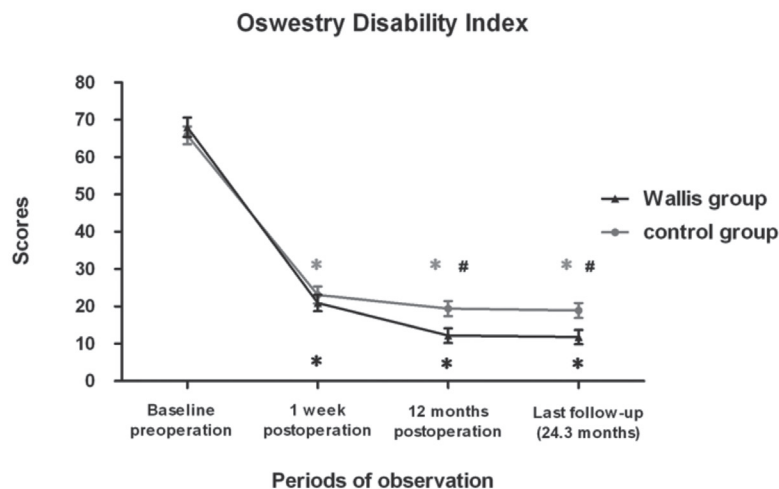


Fig. 4. — ODI changes at the last follow-up visit. * $P < 0.05$ comparing with baseline; # $P < 0.05$ for comparisons between the Wallis group and the control group

group, the ROM decreased significantly after treatment (22.34 ± 1.58 at 12 months and 22.27 ± 1.59 at the last follow-up visit; $P < 0.001$), while there was no change in the control group (26.25 ± 1.65 at 12 months, $P = 0.320$ and 26.31 ± 1.65 at the last follow-up visit, $P = 0.162$). However, no significant difference was found in the ROM between the two groups at 12 months and at the last follow-up visit ($P = 0.203$, $P = 0.180$, respectively) (Fig. 6).

Complications

Two patients in the Wallis group and one patient in the control group accidentally developed intraoperative dural violation that was immediately sutured without further problems. One patient in the control group developed recurrent intervertebral disc herniation at the L4/5 segment that required revision operation by lumbar fusion at the 18th postoperative month. There were no cases of infection, lumbar kyphosis, fractured spinous processes, or failure of the Dacron ligaments.

DISCUSSION

This prospective controlled study aimed to compare the clinical and radiological outcomes

between discectomy with and without Wallis implants for the treatment of primary LDH. Discectomy with Wallis implants resulted in better pain relief (VAS scores) and improvement in lumbar function (JOA score and ODI) than lumbar discectomy alone, at 12 months and at the last follow-up visit. However, the differences between the two groups were 7.24 and 4.32 for the VAS score, and 7.26 and 7.13 for the ODI at 12 months and the last follow-up visit, respectively. These are smaller than the reported minimal clinically important differences (MCID, 1.2 to 2.2 on a 10-point VAS scale and 8.2 to 12.8 ODI) (4,18) that are recognized as a critical threshold for measuring treatment effectiveness and represent the smallest change that is important to patients. Therefore, the clinical difference in the VAS score and ODI between the groups at 12 months and the last follow-up visit remains open to interpretation. Nevertheless, the MCID have variable thresholds based on the calculation technique and should not be considered an indicator of treatment success (18). Further studies are needed to confirm our findings.

The radiological outcomes also indicated that the Wallis implant had the advantage of distracting and restoring the DH and limiting the ROM of operated segments compared with discectomy alone. Nevertheless, studies suggest decreasing relative

advantage from the surgery over time. Most patients' conditions deteriorate with decreasing DH at the operated segments (3) and a series of degenerative conditions, including intervertebral foramina stenosis, lateral recess stenosis, and ligamentum flavum hypertrophy, which lead to poor clinical outcome and exacerbation of symptoms (1). The postoperative damage to the functional spinal unit also alters the distribution of mechanical loading of the spine. The asymmetric loading of the posterior annulus increased with the increased range of motion and decreased stiffness of the operated segments (13).

Excessive spinal loading creates a toxic environment for the intervertebral disc cells, leads to failure of the healing process (15), and increases the risk of failed back surgery syndrome. Previous prospective clinical trials revealed that although discectomy reduces pain and improves function in the short term (19), it does not have a better long-term effect than non-surgical management (2). Thus, alternative techniques may be required to for LDH correction while maintaining spinal stability. Lumbar fusion is one option for preventing postoperative low-back pain and recurrent LDH (20). However, it alters

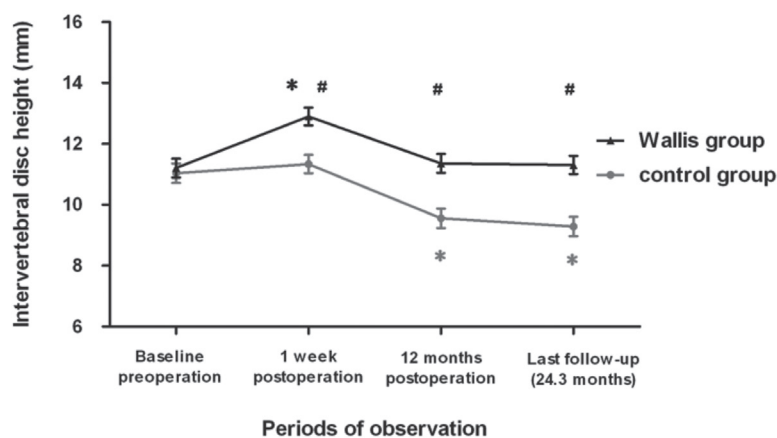


Fig. 5. — Changes in intervertebral disc height (mm) of the operated segments from preoperatively to postoperatively and the last follow-up visit. * $P < 0.05$ comparing with baseline ; # $P < 0.05$ for comparisons between the Wallis group and control group

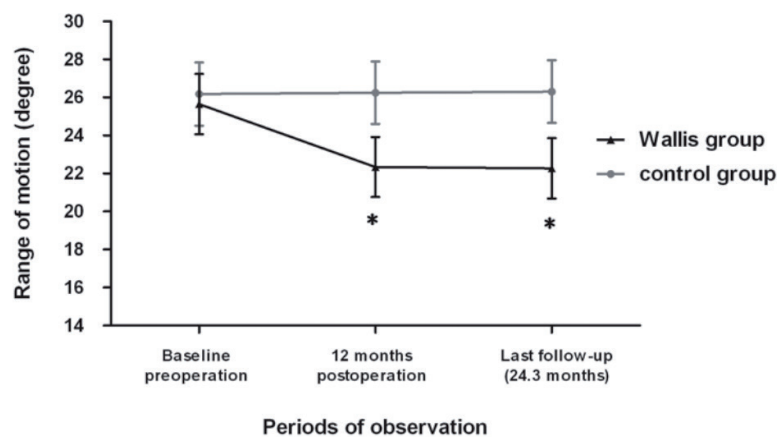


Fig. 6. — Changes in the range of motion (degree) of the operated segments from baseline to postoperatively and the last follow-up visit. * $P < 0.05$ comparing with baseline

the biomechanics of the fused levels and increases motion at other unfused segments as a compensation effect resulting in ASD (9).

Posterior dynamic stabilization was designed to increase the rigidity of the intervertebral system and limit the amplitude of mobility to inhibit the irreversible course of the degenerative lesions (21). It also normalizes the segment motion and offloads the posterior annulus and facet joints, with the goal of healing the least severe lesions, reversing intervertebral disc degeneration, and preventing failed back surgery syndrome. Senegas et al. has proved that the system could be used safely and effectively for the treatment of primary LDH (22). Previous prospective control trials have shown that the Wallis implant achieved more significant resolution of residual low-back pain than lumbar discectomy alone for the treatment of recurrent LDH (21). Sobottke et al. stated that the foraminal height, width, cross-sectional area, and intervertebral angle, as well as the anterior and posterior DH significantly changed after implantation (25). Siddiqui et al. believe that the Wallis implant increases the spinal canal cross-sectional area (24). A biomechanical study showed that the Wallis implant limited the range of motion by 35% and increased the stiffness of the segment by 150%, meanwhile reduced the load on the disc and the facet joint system by as much as 50% for a blocker 12 mm in thickness (21). We demonstrated that the Wallis implant significantly increased the DH of the operated segments immediately after treatment and restored it to baseline levels at the final follow-up. The Wallis group had higher DH than the control group at each follow-up visit. An in vitro study revealed significant correlation between the increased DH and diminished disc protrusion via ligamentotaxis and thinning of the ligamentum flavum (7). This can be extrapolated to the Wallis implant (25), which may be valuable in decompressing the nerve root and reducing the residual low back and leg pain. Meanwhile, the stability of the spine was maintained in the Wallis group, as evidenced by the decreased ROM at the 2-year postoperative follow-up visit.

Several issues need to be considered for the application of the Wallis interspinous dynamic stability system in LDH treatment. First, compli-

cations such as dural laceration, deep infection, or recurrent LDH (5,12,21), as well as kyphotic deformation and spinous process fracture (14,25) have been reported. A slight segmental kyphosis generated by the interspinous implant could be beneficial when nerve roots or other posterior structures need decompression. However, if the kyphosis becomes too large, it could have adverse effects on the overall alignment and loading of the adjacent levels (11). Therefore, we used an image intensifier before final fixation to verify the correct height and spacer placement and avoid the kyphotic deformation (22). Thus far, the complications in our Wallis group patients were limited to dural violation (two cases) without adverse consequences. Further follow-up might be required to monitor for long-term complications. Secondly, whether the Wallis implant has the ability to lower the incidence of recurrent LDH remains controversial. Senegas et al. stated that the Wallis implant was capable of inducing disc rehydration as confirmed by MRI (21), and therefore, lowers the incidence of recurrent LDH. However, Floman et al. demonstrated a 13% recurrence rate even with the Wallis implant (5). In our study, only one patient who was in the control group developed recurrent LDH. Additionally, patients with the L5/S1 herniation were excluded from our study because of the frequent absence of an adequate spinous process of the sacrum and the distinct biomechanical behaviour of L5/S1 segment (26). Lastly, the time of surgery was significantly longer in the Wallis group than in control group. Although the sex distribution may differ from the data, there was no significant difference ($P=0.08$) between the two groups. Multivariate analysis of variance was used to analyse the differences in each parameter between the two groups while adjusting for sex and the duration of surgery. The results before and after adjustment were similar, which indicates that sex distribution and the duration of surgery have little impact on the outcome.

There are several limitations in the study. First, the relatively small sample size and follow-up duration (approximately 24 months) may affect the clinical significance of the findings. Second, this is a single-centre experience and the results may not be generalizable. Additionally, blinding was only

performed for the statisticians who analysed the data.

In conclusion, lumbar discectomy combined with the Wallis interspinous dynamic stability system is safe and effective for the treatment of primary LDH. It may be beneficial for better pain relief and lumbar functional improvement while maintaining disc height. However, its clinical benefits remain unresolved because of a longer operating time and the relatively small difference in the VAS score and ODI between the groups. The indications, long-term effects, and complications of the Wallis system and its effect on adjacent segment degeneration need to be specified by further prospective controlled studies.

REFERENCES

1. **Atlas SJ, Keller RB, Chang Y, Deyo RA, Singer DE.** Surgical and nonsurgical management of sciatica secondary to a lumbar disc herniation : five-year outcomes from the Maine Lumbar Spine Study. *Spine (Phila Pa 1976)* 2001 ; 26 : 1179-1187.
2. **Atlas SJ, Keller RB, Wu YA, Deyo RA, Singer DE.** Long-term outcomes of surgical and nonsurgical management of sciatica secondary to a lumbar disc herniation : 10 year results from the maine lumbar spine study. *Spine (Phila Pa 1976)* 2005 ; 30 : 927-935.
3. **Brinckmann P, Horst M.** The influence of vertebral body fracture, intradiscal injection, and partial discectomy on the radial bulge and height of human lumbar discs. *Spine (Phila Pa 1976)* 1985 ; 10 : 138-145.
4. **Copay AG, Glassman SD, Subach BR, et al.** Minimum clinically important difference in lumbar spine surgery patients : a choice of methods using the Oswestry Disability Index, Medical Outcomes Study questionnaire Short Form 36, and pain scales. *Spine J* 2008 ; 8 : 968-974.
5. **Floman Y, Millgram MA, Smorgick Y, Rand N, Ashkenazi E.** Failure of the Wallis interspinous implant to lower the incidence of recurrent lumbar disc herniations in patients undergoing primary disc excision. *J Spinal Disord Tech* 2007 ; 20 : 337-341.
6. **Frymoyer JW.** Back pain and sciatica. *N Engl J Med* 1988 ; 318 : 291-300.
7. **Fujiwara A, An HS, Lim TH, Haughton VM.** Morphologic changes in the lumbar intervertebral foramen due to flexion-extension, lateral bending, and axial rotation : an in vitro anatomic and biomechanical study. *Spine* 2001 ; 26 : 876-882.
8. **Ghiselli G, Wang JC, Bhatia NN, Hsu WK, Dawson EG.** Adjacent segment degeneration in the lumbar spine. *J Bone Joint Surg Am* 2004 ; 86-A : 1497-1503.
9. **Huang RC, Wright TM, Panjabi MM, Lipman JD.** Biomechanics of nonfusion implants. *Orthop Clin North Am* 2005 ; 36 : 271-280.
10. **Jutte PC, Castelein RM.** Complications of pedicle screws in lumbar and lumbosacral fusions in 105 consecutive primary operations. *Eur Spine J* 2002 ; 11 : 594-598.
11. **Kettler A, Drumm J, Heuer F, et al.** Can a modified interspinous spacer prevent instability in axial rotation and lateral bending? A biomechanical in vitro study resulting in a new idea. *Clin Biomech (Bristol, Avon)* 2008 ; 23 : 242-247.
12. **Korovessis P, Repantis T, Zacharatos S, Zafiroopoulos A.** Does Wallis implant reduce adjacent segment degeneration above lumbosacral instrumented fusion? *Eur Spine J* 2009 ; 18 : 830-840.
13. **Kuroki H, Goel VK, Holekamp SA, et al.** Contributions of flexion-extension cyclic loads to the lumbar spinal segment stability following different discectomy procedures. *Spine (Phila Pa 1976)* 2004 ; 29 : 39-46.
14. **Lafage V, Gangnet N, Senegas J, Lavaste F, Skalli W.** New interspinous implant evaluation using an in vitro biomechanical study combined with a finite-element analysis. *Spine (Phila Pa 1976)* 2007 ; 32 : 1706-1713.
15. **Lotz JC, Chin JR.** Intervertebral disc cell death is dependent on the magnitude and duration of spinal loading. *Spine (Phila Pa 1976)* 2000 ; 25 : 1477-1483.
16. **Masui T, Yukawa Y, Nakamura S, et al.** Natural history of patients with lumbar disc herniation observed by magnetic resonance imaging for minimum 7 years. *J Spinal Disord Tech* 2005 ; 18 : 121-126.
17. **Moschetti W, Pearson AM, Abdu WA.** Treatment of lumbar disc herniation : An evidence based review. *Semin Spine Surg* 2009 ; 21 : 223-229.
18. **Parker SL, Mendenhall SK, Shau DN, et al.** Minimum clinically important difference in pain, disability, and quality of life after neural decompression and fusion for same-level recurrent lumbar stenosis : understanding clinical versus statistical significance. *J Neurosurg Spine* 2012 ; 16 : 471-478.
19. **Peul WC, van HH, van HW, et al.** Surgery versus prolonged conservative treatment for sciatica. *N Engl J Med* 2007 ; 356 : 2245-2256.
20. **Satoh I, Yonenobu K, Hosono N, et al.** Indication of posterior lumbar interbody fusion for lumbar disc herniation. *J Spinal Disord Tech* 2006 ; 19 : 104-108.
21. **Senegas J.** Mechanical supplementation by non-rigid fixation in degenerative intervertebral lumbar segments : the Wallis system. *Eur Spine J* 2002 ; 11 Suppl 2 : S164-S169.
22. **Senegas J, Vital JM, Pointillart V, Mangione P.** Clinical evaluation of a lumbar interspinous dynamic stabilization device (the Wallis system) with a 13-year mean follow-up. *Neurosurg Rev* 2009 ; 32 : 335-341, 341-342.
23. **Senegas J, Vital JM, Pointillart V, Mangione P.** Long-term actuarial survivorship analysis of an interspinous stabilization system. *Eur Spine J* 2007 ; 16 : 1279-1287.

24. **Siddiqui M, Nicol M, Karadimas E, Smith F, Wardlaw D.** The positional magnetic resonance imaging changes in the lumbar spine following insertion of a novel interspinous process distraction device. *Spine (Phila Pa 1976)* 2005 ; 30 : 2677-2682.
25. **Sobottke R, Schluter-Brust K, Kaulhausen T, et al.** Interspinous implants (X Stop, Wallis, Diam) for the treatment of LSS : is there a correlation between radiological parameters and clinical outcome? *Eur Spine J* 2009 ; 18 : 1494-1503.
26. **Tamburrelli FC, Proietti L, Logroscino CA.** Critical analysis of lumbar interspinous devices failures : a retrospective study. *Eur Spine J* 2011 ; 20 Suppl 1 : S27-S35.
27. **Watters II, McGirt MJ.** An evidence-based review of the literature on the consequences of conservative versus aggressive discectomy for the treatment of primary disc herniation with radiculopathy. *The Spine Journal* 2009 ; 9 : 240-257.
28. **Wera GD, Dean CL, Ahn UM, et al.** Reherniation and failure after lumbar discectomy : a comparison of fragment excision alone versus subtotal discectomy. *J Spinal Disord Tech* 2008 ; 21 : 316-319.
29. **Yue JJ, Timm JP, Panjabi MM, Jaramillo-de TJ.** Clinical application of the Panjabi neutral zone hypothesis : the Stabilimax NZ posterior lumbar dynamic stabilization system. *Neurosurg Focus* 2007 ; 22 : E12.