

TRANSIENT OSTEOPOROSIS

E. CRESPO¹, D. SALA¹, R. CRESPO², A. SILVESTRE¹

Transient osteoporosis (TO) is an uncommon entity whose principal characteristic is to be a self-limited syndrome. Diagnosis is made upon clinical presentation and xray evidence of diffuse osteopenia around the affected joint followed by spontaneous healing after several months. When recurrent episodes occur at different times and locations it is called regional migratory osteoporosis. Magnetic resonance imaging and technetium-99 bone scan may be helpful in diagnosis during the early phase. Good results may be achieved with nonsteroidal antiinflammatory medication, protected weight bearing and physical therapy.

Keywords : transient osteoporosis.

Mots-clés : ostéoporose transitoire.

INTRODUCTION

Transient osteoporosis (TO) is a rare, self-limited syndrome, characterized by sudden onset of joint pain followed by local osteopenia after several weeks, with spontaneous healing. A large number of patients with TO have recurrence affecting other joints; the term regional migratory osteoporosis (RMO) has been applied to these cases. In 1959, Curtiss and Kinkaid (11) first reported the syndrome in three pregnant women with painful hips during the last trimester; a few years later Duncan *et al.* (14) described a similar disorder affecting several joints at different times, calling the condition migratory osteolysis. Later on, in 1968, Lequesne (36) described localized transient

osteoporosis as a monoarticular disease without recurrence. Other synonyms used in the literature include transient demineralization, migratory osteolysis, reflex sympathetic dystrophy of the hip, and transient bone marrow edema (22).

The very low incidence and nonspecific roentgenographic and clinical findings make TO a poorly recognized syndrome. Several hypotheses have been proposed regarding the etiology, which is however still unknown.

EPIDEMIOLOGY

TO usually affects healthy middle-aged men, with most patients being between 40 and 60 years old (range : 24-75 years) (33). In women, it occurs almost exclusively during the third trimester of pregnancy (mean gestational age at onset : 32 weeks) or in the early postpartum period, and tends to be commonly seen in primigravidas (33, 54, 55). In a few cases, it may be bilateral or recur with a second pregnancy (2, 51). It is more frequent in men than in women in a proportion of 3 to 1 (50). The condition is rare in children (4, 41). Our experience with three cases, two men (35 and 44 years old) and one nonpregnant woman (32 years old) shows that TO may also affect nonpregnant women.

¹ Department of Orthopedics and Trauma Surgery. University Clinic Hospital. Valencia, Spain.

² Department of Trauma and Orthopedic Surgery. Hospital La Mancha Centro, Alcázar de San Juan. Spain.

Correspondence and reprints : Eusebio Crespo Romero, Hospital Clínico – Servicio de Traumatología, Av. Blasco Ibañez nº 17, CP : 46010, Valencia - Spain. E-Mail : ecrespo@comv.es.

Except for pregnancy, there are no other known predisposing factors. The risk of acquiring transient osteoporosis is however much higher in patients with osteogenesis imperfecta than in the general population. This relationship was first reported by Hunder and Kelly in 1967 (28), and 20 cases have now been documented in the literature (31, 43, 58).

ETIOLOGY

The etiology of this syndrome is still unknown. In their first description, Curtiss and Kincaid (11) proposed a neurogenic hypothesis, in which possible intermittent compression of the mother's obturator nerve by the child's head might be the cause of the disease. However, this could not be experimentally reproduced in dogs (11). Electromyographic (EMG) findings have been normal in TO cases (31), but EMG has documented denervation patterns coincident in location and time with RMO attacks (37, 39).

Another interpretation is that osteopenia follows the disuse caused by the patient's functional impairment; however, this does not seem plausible as demineralization takes place in a very limited joint area without affecting the rest of the extremity. Besides, complete recovery of bone density has been documented although the involved extremity was nonweight bearing (27).

Other authors consider TO as a nontraumatic type of reflex sympathetic dystrophy (35), since clinical, radiological, and scintigraphic appearances of both pathologies are similar. However, TO lacks vascular and cutaneous changes characteristic of reflex sympathetic dystrophy (33).

Viral infection has also been suggested as a possible etiology, because it could stimulate osteoclastic resorption and demineralization, generating stress fractures and pain with weight bearing (8). Paran *et al.* (45) described two cases of TO with a positive fluorescent antinuclear antibody test, anti-cardiolipin antibodies, and a history of heavy smoking. They suggested local ischemia as a possible etiology of TO, induced by antiphospholipid antibodies and increased by smoking. However this theory has not been confirmed by further studies.

Pregnancy and lactation are stressing factors on maternal calcium homeostasis. In pregnancy, maternal placental transfer of calcium and physiological hypercalciuria produces calcium losses, compensated by increasing $1,25(\text{OH})_2\text{D}_3$ levels that enhance gastrointestinal calcium absorption (21, 52), but some studies have proved a transient decrease in bone mass during pregnancy (13, 19). Transfer of calcium from serum into breast milk contributes to calcium losses during lactation, producing bone loss in the initial 6 months, and recovering during the 2 years after lactation (53). Women who have risk factors for osteoporosis or events that may have impaired their ability to attain peak bone mass are most at risk for developing transient osteoporosis in pregnancy (54). In pregnant women other theories include damage to the joint as a result of venous stasis of pregnancy and damage to the lumbosacral cord as it passes across the pelvic brim (5, 48, 50). All these theories do not explain cases seen in men and nonpregnant women.

A transient ischemic event, which produces limited cell death involving only the hematopoietic and fatty elements, is thought to be the cause of TO (15, 23, 28). Histology shows intertrabecular edema, inflammatory infiltrates, fat necrosis, bone resorption and new bone formation (27, 33, 44, 46). TO of the hip has been proposed as an early reversible phase of avascular osteonecrosis (AVN) (26), but with a diffuse pathway distinct from the normal focal pattern of AVN. There may be a spectrum of ischemia, a diffuse zone with more limited insult resulting in TO, and more severe and prolonged ischemia in a more restricted zone could result in AVN. A relationship between these two pathologies has however not been proved. Clinical, imaging and histopathologic differences, including the gross appearance, distribution of repair tissue, and viability of bone trabeculae in the affected region (59), have proved they are different disorders (22).

CLINICAL PRESENTATION

The patient usually complains of sudden or progressive pain in the affected joint causing limp, without any previous trauma. Pain, with mechani-

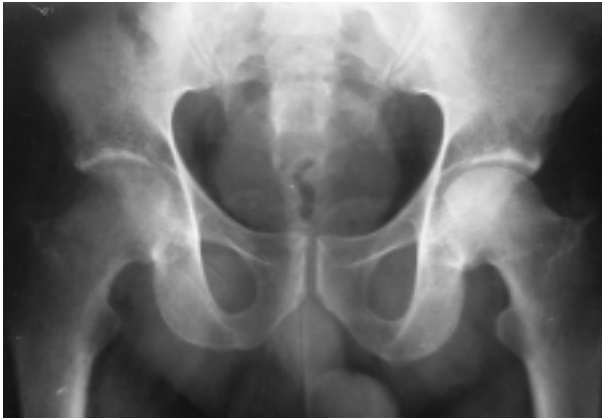

Fig. 1. — Anteroposterior xray of both hips in a 35-year-old male patient demonstrating severe osteopenia of the right femoral head and neck. This was the first episode of an RMO.

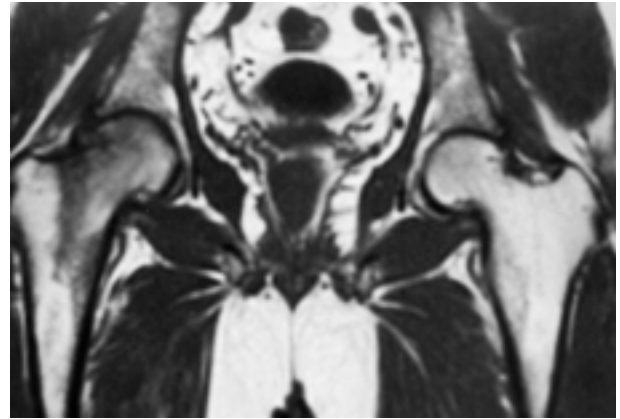


Fig. 2. — T1-weighted image in MR reveals diffuse and homogeneous low signal intensity throughout the right femoral head and neck, not affecting the acetabular and trochanteric regions (same patient as fig. 1).

cal features, increases while walking and standing, often improving with rest. Only in some cases may night pain be present. The range of joint motion is slightly diminished, and it is painful in the last degrees (22).

Schapira has identified three phases throughout the process (51) : an initial phase characterized by intense pain with functional impairment, lasting approximately one month ; during the next one or two months, symptoms remain unchanged and marked osteopenia appears on xray ; later on spontaneous regression takes place, with improvement in bone density. This period lasts about four months. Two of our patients suffered episodes that lasted between six and eight months, but the third one had a four-month limited episode.

The hip is the most frequently affected joint, followed by knee, foot and ankle (33). TO may present one episode affecting only one joint, or recurrent episodes that may involve two to seven joints, either successively or with overlapping. This clinical course is called RMO and represents between 10% and 40% of the cases (24, 33). The time interval between recurrences may be short or as long as two or more years (1, 3, 14). Occasionally, several joints may be affected simultaneously (33, 38).

Our cases showed three different clinical presentations. One presented a typical RMO that started

at the right hip ; consecutively and progressively the migratory episodes affected the right knee, the ankles and the feet ; the patient had to use crutches for almost 24 months. The second case had an RMO with two episodes ; the first one affected the right hip, and eight years later the right knee was involved. The third case was a TO of the hip without recurrences. Laboratory study is usually normal ; a slightly increased erythrocyte sedimentation rate is rarely noted (3).

IMAGING

Radiography

In TO, radiographic bone density is normal until four to eight weeks have elapsed since the onset of clinical symptoms. Later on, a periarticular diffuse osteopenia can be seen, that in the hip rarely affects the pelvic bone and greater trochanter. A decrease in cancellous bone density takes place that may be so severe as to make the normal bony architecture almost disappear ; in subchondral bone, the density decrease is less important (figs. 1, 3). Joint space remains normal, which differs from the advanced stages of AVN (27, 35, 48). Bone remineralization takes place spontaneously after a six to eight-month period.

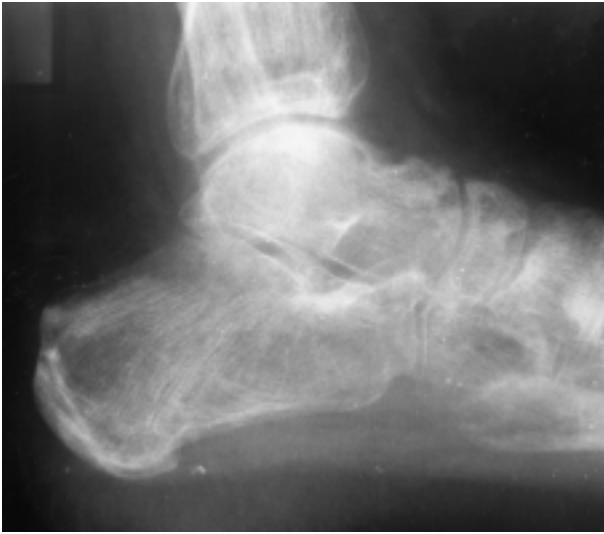

Fig. 3. — Osteopenia and cortical thinning of the ankle and foot. Articular spaces are preserved (same patient as figs. 1 and 2, in a subsequent episode of RMO).

Radionuclide Bone-Scanning

A diffuse and homogeneous increase of radionuclide uptake is seen in the affected joint a few days after the onset of the symptoms, even before xray changes (fig. 4). When symptoms diminish a gradual decrease in radionuclide uptake is detected on scintigraphy (7, 20). Even though this technique is positive early and has high sensitivity, its specificity is low (47).

Magnetic Resonance Imaging

Bloem in 1988 gave the first description of MRI changes observed in TO of the hip (6). They can be detected as soon as with bone scans (48 hours), and regression of the abnormalities can be seen along with symptom improvement, about 6 to 8 months later (12). An ill-defined area of decreased signal intensity is seen on T1-weighted images, with an area of increased signal intensity on T2-weighted images ; these diffuse signal abnormalities have been attributed to bone marrow edema (58). In addition, an effusion is usually present. In the hip, these changes mainly affect the head, neck and intertrochanteric region (fig. 2) (12, 22).

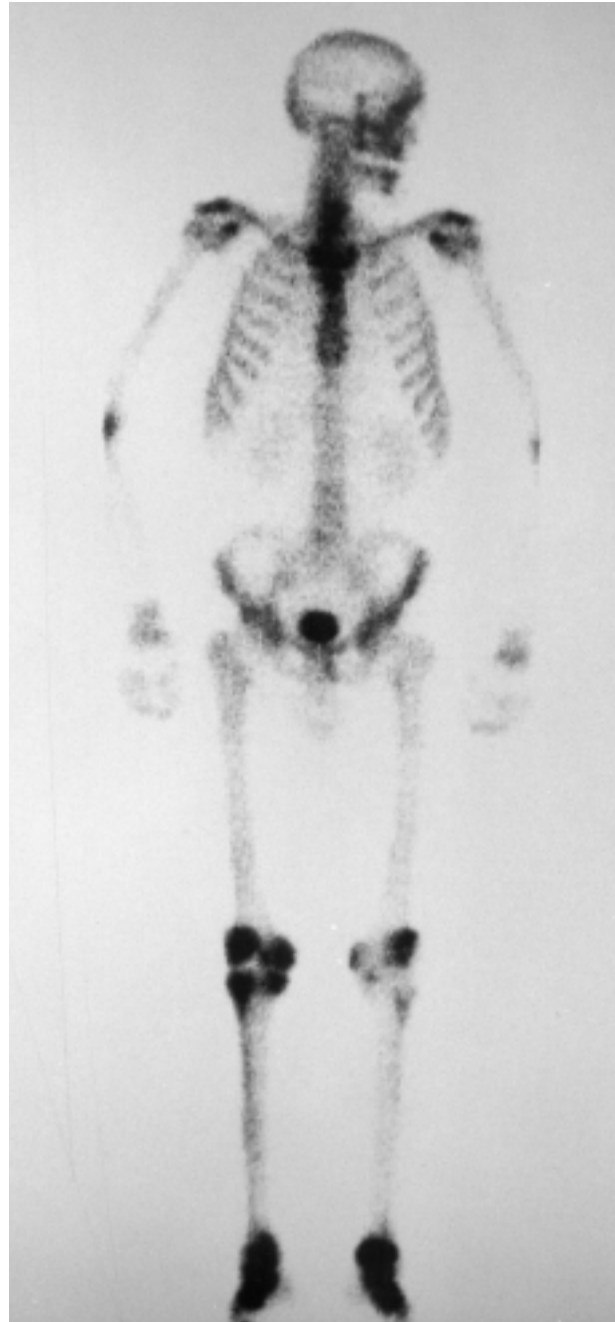

Fig. 4. — Radionuclide bone-scanning shows diffuse, homogeneous uptake of the isotope over the right knee and the feet (same patient as fig. 3).

In the knee, changes are more frequent in the lateral condyle (49) ; however, in one case we found diffuse edema also in the medial condyle. Tarsal bones are commonly affected, but rarely metatarsal

bones (10). In our MRO case TO affected both ankle and foot (fig. 3).

DIFFERENTIAL DIAGNOSIS

Differential diagnosis must include crystal-induced arthropathy, rheumatoid arthritis, osteoarthritis and infectious arthritis (1, 34, 36). Other diagnoses, such as primary bone tumor, metastases, tuberculosis of bone, osteomyelitis, multiple myeloma and metabolic bone disease should also be considered. TO may be differentiated from all of them through normal laboratory studies and characteristic imaging.

The differential diagnosis must also be made with reflex sympathetic dystrophy (RSD). In RSD there is frequently a history of trauma or operation. Cardinal symptoms are diffuse burning pain in the affected region, sensory disturbances of hypo- or hyperesthesia, trophic changes of discoloration, swelling and thickening, alterations in skin temperature, autonomic regulation and motor disturbances (16, 56). Common sites are small bones and soft tissues of the hand and foot. Bone scintigraphy and MRI give a different pattern showing alterations in bone and in soft tissues (24).

In the early phase, AVN should be excluded, since the therapeutic approach is different. AVN is a progressive condition that leads to joint destruction, requiring specific surgical treatment (8, 9). In the early stages the two conditions are difficult to differentiate, but clinically in AVN, the pain is often present at rest, the limp and the antalgic gait are typically late findings, and the functional disability is proportional to the pain level (22). The radiographic appearance of AVN rarely shows diffuse osteopenia, and the classic appearance of AVN is a mottled radiolucent area surrounded by an area of sclerosis. But plain radiography is not useful in early differential diagnosis, as xray in TO is affected only four to eight weeks after the onset (22). Scintigraphy is an important screening adjunct before radiographic changes are seen. In AVN scintigraphy may be similar to TO, although increased uptake is usually less intense and more limited to the femoral head. If a cold spot appears over the femoral head anterosuperior region, it is

almost pathognomonic for AVN, and is never seen in TO (22, 43). The most useful tool to differentiate TO from AVN is magnetic resonance imaging (MRI): in AVN, a focal, nonhomogeneous, segmental and well-demarcated lesion in the anterosuperior subchondral region of the femoral head is the classic appearance. T2-weighted images may demonstrate the so-called double-line sign, which is pathognomonic for avascular necrosis. There are few reports in the literature of AVN that initially presented with MRI findings typical of bone-marrow edema (22), so there is no strong MRI finding to support the existence of a relationship between TO and AVN (32). A long and self-limited clinical course, in some cases recurrence in other joints, and later the imaging picture allow the differential diagnosis of TO and AVN.

TREATMENT AND COMPLICATIONS

Many conservative treatments have been used, such as oral steroid therapy, intraarticular steroid injection, calcitonin and sympathetic blocks (34, 35), but none has been noted to change the natural course of the disease. Owing to the similarity between TO of the hip and AVN in initial phases, and the importance of early treatment in osteonecrosis, some authors recommend hip core decompression in every case or in cases with persistent pain (25, 40, 47).

Hofmann *et al.* (26), in a prospective study of 43 TO's of the hip treated with core decompression, achieved immediate relief of pain after surgery in all patients. The average duration of symptoms was dramatically reduced by core decompression from 6 months with conservative treatment down to 2 months, without perioperative complications. Therefore, they recommended core decompression in patients with painful TO of the hip.

The problem consists in the process etiology. If it is considered as an early phase of an AVN, operative treatment may avoid subsequent AVN evolution. If they are different entities, and TO has a self-limited evolution, this procedure seems unnecessarily aggressive (32). Another justification for surgical treatment is that it may improve and reduce symptoms (26). It may be useful in patients with

severe pain, but not all the patients have severe pain or a long enough evolution to justify the operation. This was the case for one of our patients, who suffered moderate hip pain for three months. Besides, at the time of diagnosis, no one knows the clinical evolution, and in RMO surgical treatment of an affected hip may not prevent future episodes in other joints.

To make a correct differential diagnosis between TO of hip and AVN in the early stages, is most important to decide on the treatment, in addition to evaluating the clinical intensity. In TO we recommend a more conservative approach, including symptomatic therapy, protected weight bearing and repeated MRI's every three months.

TO during pregnancy deserves special mention. Traumatic fractures of the femoral neck and stress fractures have been infrequently reported in patients with TO, and all have been in pregnant women (17, 18, 29). This is the most serious complication of the condition. TO during pregnancy has to be treated nonoperatively with strict recommendations to restrict weight bearing until there is radiographic evidence of reconstitution of the bone mass (22). A pathological fracture has to be surgically treated postpartum (17, 18, 29).

REFERENCES

1. Arnstein R. A. Regional osteoporosis. *Orthop. Clin. N. Am.*, 1972, 3, 585.
2. Axt-Fliedner R., Schneider G., Seil R., Friedrich M., Mink D., Schmidt W. Transient bilateral osteoporosis of the hip in pregnancy. A case report and review of the literature. *Gynecol. Obstet. Invest.*, 2001, 51, 138-140.
3. Banas M. P., Kaplan F. S., Fallon M. D., Haddad J. G. Regional migratory osteoporosis. A case report and review of the literature. *Clin. Orthop.*, 1990, 250, 303-309.
4. Beaulieu J. G., Razzano C. D., Levine R. B. Transient osteoporosis of the hip in pregnancy. Review of the literature and a case report. *Clin. Orthop.*, 1976, 115, 165-168.
5. Ben-David Y., Bornstein J., Sorokin Y. Transient osteoporosis of the hip during pregnancy. A case report. *J. Reprod. Med.*, 1991, 36, 672-675.
6. Bloem J. L. Transient osteoporosis of the hip : MR imaging. *Radiology*, 1988, 167, 753-755.
7. Bray S. T., Partain C. L., Teates C. D., Guilford W. B., Williamson B. R. McLaughlin R. C. The value of the bone scan in idiopathic regional migratory osteoporosis. *J. Nucl. Med.*, 1979, 20, 1268-1271.
8. Brown T. D., Pedersen D. R., Baker K. J. Brand R. A. Mechanical consequences of core drilling and bone-grafting on osteonecrosis of femoral head. *J. Bone Joint Surg.*, 1993, 75-A, 1358-1367.
9. Buckley P. D., Gearen P. E., Petty R. W. Structural bone-grafting for early atraumatic avascular necrosis of the femoral head. *J. Bone Joint Surg.*, 1991, 73-A, 1357-1364.
10. Calvo E., Alvarez L., Fernández-Yruegas D. Vallejo C. Transient osteoporosis of the foot. Bone marrow edema in 4 cases studied with MRI. *Acta Orthop. Scand.*, 1997, 68, 577-580.
11. Curtis P. H. Jr., Kincaid W. E. Transitory demineralization of the hip in pregnancy. A report of three cases. *J. Bone Joint Surg.*, 1959, 41-A, 1327-1333.
12. Daniel W. W., Sanders P. C. Alarcon G. S. The early diagnosis of transient osteoporosis by magnetic resonance imaging. A case report. *J. Bone Joint Surg.*, 1992, 74-A, 1262-1264.
13. Drinkwater B. L., Chestnut C. H. Bone density changes during pregnancy and lactation in active women : A longitudinal study. *Bone Min.*, 1991, 14, 153-160.
14. Duncan H., Frame B., Frost H. M., Arnstein A.R. Migratory osteolysis of the lower extremities. *Ann. Intern. Med.*, 1967, 66, 1165-1173.
15. Dustan C. R., Evans R. A. Somers N. M. Bone death in transient regional osteoporosis. *Bone*, 1992, 13, 161-165.
16. Fialka V. The diagnosis of reflex sympathetic dystrophy. *Eur. J. Phys. Med. Rehab.*, 1992, 2, 40-44.
17. Fingerth R. J. Successful operative treatment of a displaced subcapital fracture of the hip in transient osteoporosis of pregnancy. A case report and review of the literature. *J. Bone Joint Surg.*, 1995, 77-A, 127-131.
18. Fokter S. K., Vengust V. Displaced subcapital fracture of the hip in transient osteoporosis of pregnancy. *Int. Orthop.*, 1997, 21, 201-203.
19. Gallacher S. J., Farser W. D., Owens D. J. Changes in calcitropic hormones and biochemical markers of bone turnover in normal human pregnancy. *Eur. J. Endocrinol.*, 1994, 131, 369-374.
20. Gaucher A., Colomb J. M., Naoun A., Faure G., Netter P. The diagnostic value of 99m Tc-diphosphonate bone imaging in transient osteoporosis of the hip. *J. Rheumat.*, 1979, 6, 574-583.
21. Gertner J., Coustand D., Kliger A. Pregnancy as a state of physiologic absorptive hypercalciuria. *Am. J. Med.*, 1986, 81, 451-456.
22. Guerra J. J., Steinberg M. E. Distinguishing transient osteoporosis from avascular necrosis of the hip. *J. Bone Joint. Surg.*, 1995, 77-A, 616-624.
23. Hayes C. W., Conway W. F. Daniel W. W. MR imaging of bone marrow edema pattern : Transient osteoporosis, transient bone marrow edema syndrome, or osteonecrosis. *Radiographics*, 1993, 13, 1001-1011.

24. Hofmann S. Bone-marrow edema in transient osteoporosis, reflex sympathetic dystrophy and osteonecrosis. In : Efort Instructional Course Lectures. Jakob R. P., Fulford P., Horan F., eds. London : The British Editorial Society of Bone and Joint Surgery, 1999, pp. 138-151.
25. Hofmann S., Engel A., Neuhold A., Leder K., Kramer J., Plenk H. Jr. Bone-marrow oedema syndrome and transient osteoporosis of the hip : An MRI-controlled study of treatment by core decompression. *J. Bone Joint Surg.*, 1993, 75-B, 210-216.
26. Hofmann S., Schneider W., Breitenseher M., Urban M., Plenk H. "Transient osteoporosis" as a special reversible form of femur head necrosis. *Orthopäde*, 2000, 29, 411-419.
27. Hunder G. G., Kelly P. J. Roentgenologic transient osteoporosis of the hip. A clinical syndrome ? *Ann. Intern. Med.*, 1968, 88, 539-552.
28. Jones J. P. J. Osteonecrosis and bone marrow edema syndrome : Similar etiology but a different pathogenesis. In : *Osteonecrosis : Etiology, Diagnosis and Treatment*. Urbaniak J. R., Jones J. P. J., eds. Rosemont, Illinois : AAOS, 1997, pp.181-189.
29. Junk S., Ostrowski M., Kokoszczynski L. Transient osteoporosis of the hip in pregnancy complicated by femoral neck fracture. A case report. *Acta Orthop. Scand.*, 1996, 67, 69-70.
30. Karagkevrekis C. B., Ainscow D. A. P. Transient osteoporosis of the hip associated with osteogenesis imperfecta. *J. Bone Joint Surg.*, 1998, 80-B, 54-55.
31. Keys G. W., Walters J. Idiopathic transient osteoporosis of the hip : brief report. *J. Bone Joint Surg.*, 1987, 69-B, 773-774.
32. Kim Y. M., Oh H. C., Kim H. J. The pattern of bone marrow oedema on MRI in osteonecrosis of the femoral head. *J. Bone Joint Surg.*, 2000, 82-B, 837-841.
33. Lakhapal S., Ginsburg W. W., Luthra H. S., Hunder G. G. Transient regional osteoporosis. A study of 56 cases and review of the literature. *Ann. Intern. Med.*, 1987, 106, 444-450.
34. Langloh N. D., Hunder G. G., Riggs B. L. Kelly P. J. Transient painful osteoporosis of the lower extremities. *J. Bone Joint Surg.*, 1973, 55-A, 1188.
35. Lequesne M. Transient osteoporosis of the hip. A nontraumatic variety of Sudeck's atrophy. *Ann. Rheumat. Dis.*, 1968, 27, 463-471.
36. Levy D., Hinterbukner C. Transient or migratory osteoporosis of lower extremities. *N.Y. State J. Med.*, 1976, 76, 739.
37. Major G. A. C. Regional migratory osteoporosis. *Postgrad. Med. J.*, 1984, 60, 420.
38. Mavichak V., Murray T. M., Hodsmen A. B., Robert N. J. Sutton R. A. L. Regional migratory osteoporosis of the lower extremities with vertebral osteoporosis. *Bone*, 1986, 7, 343.
39. McCord W. C., Nies K. M., Campion D. S., Louis J. S. Regional migratory osteoporosis : A denervation disease. *Arthr. Rheum.*, 1978, 21, 834.
40. Neuhold A., *et al.* Bone marrow edema of the hip : MR findings after core decompression. *J. Comp. Assist. Tom.*, 1992, 16, 951-955.
41. Nicol R. O., Williams P. F., Hill D. J. Transient osteopaenia of the hip in children. *J. Pediatr. Orthop.*, 1984, 4, 590-592.
42. Noorda R. J. P., Van der Aa J. P. W., Wuisman P. I. J., David E. F. L., Lips P., Van der Valk P. Transient osteoporosis and osteogenesis imperfecta. *Clin. Orthop.*, 1997, 337, 249-255.
43. Owen R. S., Dalinka M. K. Imaging modalities for early diagnosis of osteonecrosis of the hip. *Sem. Arthroplasty*, 1991, 2, 169-174.
44. Pantazopoulos T., Exarchou E. Hartofilakidis-Garofalidis G. Idiopathic transient osteoporosis of the hip. *J. Bone Joint Surg.*, 1973, 55-A, 315-321.
45. Paran D., Segal R., Jukovsky G., Fishel B., Yaron M. Transient regional osteoporosis with antiphospholipid antibodies : A report of two cases. *Clin. Exp. Rheumatol.*, 1996, 14, 677-680.
46. Potter H., Moran M., Schneider R., Bansal M., Sherman C. Markisz J. Magnetic resonance imaging in diagnosis of transient osteoporosis of the hip. *Clin. Orthop.*, 1992, 280, 223-229.
47. Ribes J., Fargueta I., Marti-Bonmati. Diagnóstico precoz de la osteoporosis transitoria de la cadera versus necrosis isquémica de la cabeza femoral. ¿Existen realmente signos diferenciales ?. *Rev. Esp. Cir. Osteoart.*, 1996, 31, 163-169.
48. Rosen R. A. Transitory demineralization of the femoral head. *Radiol.*, 1970, 94, 509-512.
49. Russell K. P., Gerald J. R. James A. U. Transient osteoporosis of the knee. *Skel. Radiol.*, 1997, 26, 306-309.
50. Schapira D. Transient osteoporosis of the hip. *Sem. Arthr. Rheumat.*, 1992, 22, 98-105.
51. Shifrin L. Z., Reis N. D., Zinman H., Besser M. I. Idiopathic transient osteoporosis of the hip. *J. Bone Joint Surg.*, 1987, 69-B, 769-773.
52. Sowers M. Pregnancy and lactation as risk factors for subsequent bone loss and osteoporosis. *J. Bone Min. Res.*, 1996, 11, 1052-1058.
53. Sowers M. F., Carton G., Shapiro B. Changes in bone density with lactation. *J. Am. Med. Assoc.*, 1993, 269, 3130-3135.
54. Sweeney A. T., Blake M. A., Holick M. F. Transient osteoporosis of the hip in pregnancy. *J. Clin. Densitometry*, 2000, 3, 291-297.
55. Uematsu N., Nakayama Y., Shirai Y., Tamai K., Hashiguchi H., Banzai Y. Transient osteoporosis of the hip during pregnancy. *J. Nippon Med. Sch.*, 2000, 67, 459-463.
56. Veldman P. H., Reynen H. M., Arntz I. E., Goris R. J. Signs and symptoms of reflex sympathetic dystrophy : Prospective study of 829 patients. *Lancet*, 1993, 342, 1012-1016.

57. Weitzel S. H., Percy A. J. Transient osteoporosis of the hip associated with pregnancy and osteogenesis imperfecta. *Orthopedics*, 2000, 23, 1291-1292.
58. Wilson A. J., Murphy W. A., Hardy D. C., Totty W. G. Transient osteoporosis : Transient bone marrow edema ? *Radiology*, 1988, 167, 757-760.
59. Yamamoto T., Kubo T., Hirasawa Y., Noguchi Y., Iwamoto Y., Sueishi K. A clinicopathologic study of transient osteoporosis of the hip. *Skeletal Radiol.*, 1999, 28, 621-627.

SAMENVATTING

E. CRESPO, D. SALA, R. CRESPO, A. SILVESTRE.
Voorbijgaande regionale osteoporosis.

Voorbijgaande osteoporosis is zeldzaam en gekenmerkt door spontane heling. De diagnose berust op het samengaan van gelocaliseerde gewrichtspijn en diffuse, maar spontaan over het beloop van enkele maanden verdwijnende radiografische osteopenie van het bot rond het betrokken gewricht. NMR en botscan zijn diagnostisch nuttig in de beginfase.

Men spreekt van migrerende regionale osteoporosis bij regelmatig herval eventueel op verschillende plaatsen.

De behandeling bestaat in relatieve gewrichtsontlasting, physiotherapie en NSAID.

RÉSUMÉ

E. CRESPO, D. SALA, R. CRESPO, A. SILVESTRE.
L'ostéoporose transitoire.

L'ostéoporose est une affection rare dont la caractéristique principale est d'être spontanément résolutive. Le diagnostic se fait sur base des signes cliniques et de la constatation, sur la radiographie, d'une ostéopénie diffuse au niveau de l'articulation affectée, ostéopénie qui régresse spontanément après quelques mois. On parle d'ostéoporose régionale migratrice lorsque de nouveaux épisodes surviennent après des laps de temps variables et dans des localisations variables. L'IRM et la scintigraphie au technetium-99 peuvent aider au diagnostic dans la phase précoce. Le traitement repose sur l'administration d'anti-inflammatoires non stéroïdiens, une restriction fonctionnelle notamment concernant l'appui pour le membre inférieur, et la physiothérapie.