



## Surgical repair of chronic rupture of the distal end of the biceps brachii. A modified anterior surgical repair technique

Dinesh K. SHARMA, Ved GOSWAMI, Jane WOOD

The authors have used a modified surgical technique for repair of the distal end of the biceps brachii in three patients who presented with chronic rupture, all more than 6 weeks old. All patients were males; two lesions were on the dominant right side and one was on the non-dominant left side. An anterior incision was made over the cubital fossa, a hole was drilled over the radial tuberosity and a simple pull-through technique with an Ethibond suture was used to attach the tendon to an endobutton over the posterior surface of the radius. All patients returned to their employment and preinjury activity levels by six months. There were no postoperative complications and clinically all repairs remained intact. The patients regained their normal range of movements in 3 months; all but one regained the endurance and strength of their bicep in 6 months as assessed by Cybex testing. Surgical repair of the distal end of the biceps using the technique reported has given excellent results in these three patients.

### INTRODUCTION

Rupture of the distal end of the biceps brachii muscle is an infrequent injury. Gilcreest and Albi (6) reported that only 3% of tendon ruptures of the biceps brachii involve the distal insertion, 1% involve the short head and the vast majority (96%) involve the long head.

The typical patient is a male in the age group 40 to 60 years: the lesion involves the dominant elbow and an association has been reported with smoking (14). The mechanism of injury is acute excessive eccentric tension due to the arm being

forced from a flexed position with a large load being lifted. The patient feels immediate sharp pain, with an audible snap in the elbow followed by persistent aching in the cubital fossa. Clinically the patient's forearm is tender to palpation and a defect in the continuity of the bicep tendon can be felt or the tendon stump can be felt as a palpable lump in the proximal part of the cubital fossa. The range of movements of the elbow is usually not limited, but weakness in supination and elbow flexion is observed. Many studies have reported that this injury may limit the sporting activities as well as the activities of daily living (13), owing to residual weakness of the elbow, loss of endurance strength, and disability (3,13).

Surgical repair usually gives good results. We report the use of a simple modified anterior surgical technique for the repair of rupture of the distal tendon of the biceps brachii. It consists of blunt dissection, drilling a hole over the radial tuberosity and Ethibond suture pull through, anatomical placement of the ruptured end and attaching it to an

---

*From Birmingham Heartlands & Solihull Hospitals, UK.*

Dinesh K. Sharma MS (Ortho) FRCS (Glas) Orthopaedic Surgeon.

Ved Goswami Mch (Ortho) FRCS, Orthopaedic Surgeon.

*Birmingham Heartlands & Solihull (Teaching) Hospitals, Bordesley Green East, UK.*

Jane Wood, MRSPSRP, Senior Physiotherapist,

*BUPA Parkway Hospital, Solihull, UK.*

Correspondence : Dinesh K.Sharma, 169, Kineton Green Road, Solihull, West Midlands B92 7EQ.UK.

E-mail : dksharma@doctors.org.uk

© 2004, Acta Orthopædica Belgica.

---

endobutton placed over the posterior surface of the radius.

### CASE REPORTS

– A 37-year-old right handed male, a regular body builder, was lifting heavy slabs in the garden when one of the slabs slipped, and while trying to hold it, he heard a snap in his left elbow. The elbow became painful and he was left with a residual mass in the arm. He was subsequently unable to do his weight lifting.

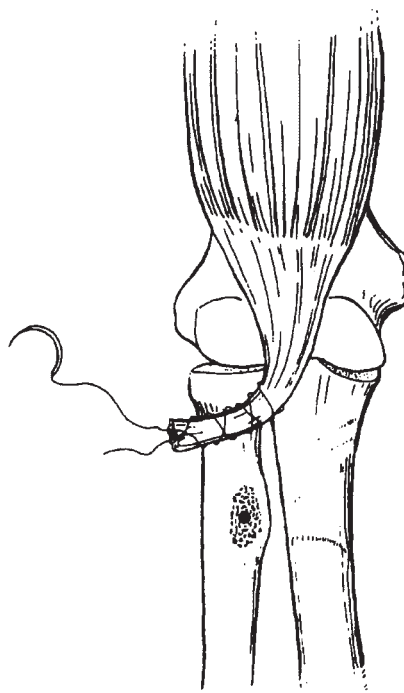
– A 46-year-old right handed male, while cutting tree branches, suddenly developed acute onset of pain and swelling in his right elbow. After some time pain eased off to dull ache but he noticed weakness of his right elbow, especially in flexion and supination. Pain was worse on movements and holding heavy objects.

– A 50-year-old right handed male was lifting a heavy television set when suddenly he heard a loud snap from his right elbow, he immediately felt something had given way in his elbow. The elbow became painful and swollen. He also noticed some bruising over the cubital fossa, which settled on its own. A lump was also visible over the arm. He also had pain on movements of the elbow, especially in flexion and supination.

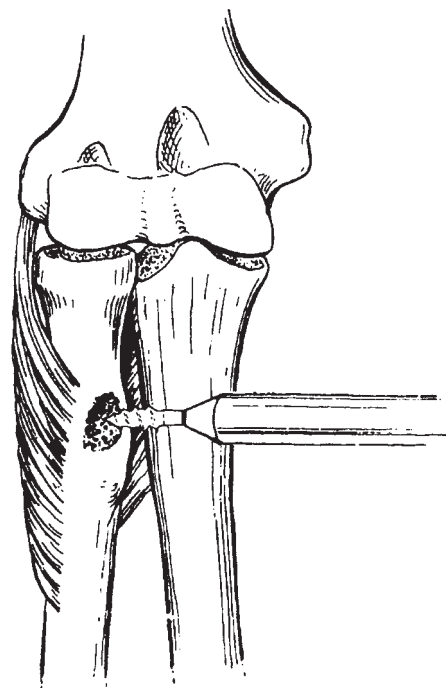
These patients were diagnosed as having complete rupture of the insertion of the biceps, and were investigated by MRI scan, which not only confirmed the diagnosis but also informed how much the ruptured end has retracted.

### Surgical technique

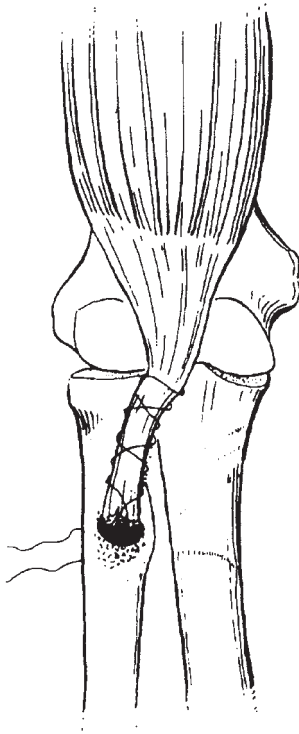
A lazy S-shaped incision was made over the cubital fossa. Following incision of the deep fascia, only blunt dissection was carried out. The ruptured end of the biceps tendon was located. The bicipital aponeurosis was preserved and a leash of blood vessels coming out of the radial artery were coagulated. The radial tuberosity was exposed after carefully retracting the posterior interosseous nerve proximally. A number 2 Ethibond suture (*Ethicon, Johnson and Johnson*) was placed in the ruptured tendon end using Bunnel's technique (fig 1). On



*Fig. 1.* — An Ethibond Nr 2 suture is passed into the end of the ruptured biceps tendon, using Bunnel's technique.

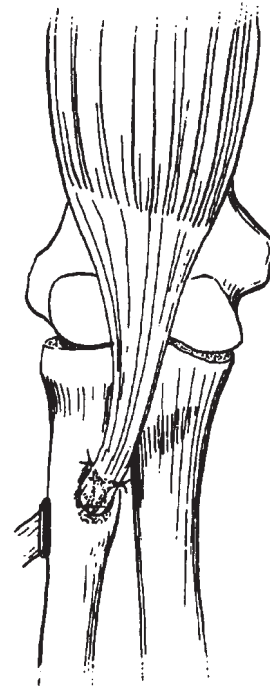


*Fig. 2.* — A hole is drilled into the radial tuberosity with a 2.5 mm drill.



*Fig. 3.* — The suture is pulled out posteriorly through the limited posterior approach.

table assessment was made to see if the retracted end could easily be brought to the radial tuberosity or not. Proximal mobilisation of the biceps muscle was required in one case to achieve this. A hole was drilled in the radial tuberosity using a 2.5 mm drill (fig 2). A small incision was made posteriorly over the drilled site and the posterior surface of the radius was subperiosteally exposed. The biceps tendon end was passed through a soft tissue tunnel to the radial tuberosity, to maintain the normal excursion of the tendon. The Ethibond suture ends were passed through the hole drilled in the radial tuberosity (fig 3) and tied to the endobutton over the exposed part of bone posteriorly, maintaining the normal tension (fig 4). In all three cases, the elbow was immobilised for 6 weeks in an above elbow plaster, following which an extensive course of physiotherapy was started, initially with passive stretches followed by active assisted exercise to gain full range of motion. A progressive strengthening programme using resisted exercises, supervised weights lifting and closed chain exercise fol-



*Fig. 4.* — The suture is tied over an endobutton.

lowed this. An isokinetic elbow flexion extension test by cybex was performed 12 weeks after operation. All these patients were clinically assessed at 6, 12 and 24 weeks. The assessment included patient's satisfaction, pain, any complications encountered, and range of movement at elbow and forearm and strength of the bicep muscle as objectively measured by Cybex.

## RESULTS

All the patients were highly satisfied post-operatively as they were able to return to their pre-operative employment and could perform all daily activities with no problem. The body builder was able to get back the normal contour of his biceps. We did not encounter any complications such as infection, joint stiffness, injury to the posterior interosseous nerve or radioulnar synostosis. All patients were able to regain full range of movements in elbow and forearm in 12 weeks. The strength and endurance of the biceps and triceps muscles were objectively measured by a Cybex isokinetic dynamometer; they were compared with

the strength on the unaffected side. Strength was assessed as the average of 3 sets of value at 30°/second whereas endurance was tested by the average of 3 sets of values at 180°/second. All the patients regained bicep strength and endurance equal to normal side with in 6 months. One patient with the lesion on his left non-dominant side had a deficit of nearly 20% strength but regained normal endurance within one year.

### DISCUSSION

Safran and Graham (14) in an extensive study on this injury have mentioned an incidence of 1.2 per 100,000 patients of these injuries. Rantanen and Orava (13) found in a meta-analysis that only 457 cases have been reported from 1897 to 1999 in the medical literature, indicating the rarity of these injuries. They are seen more frequently nowadays because of changes in life style.

The fact that surgical treatment gives better results than conservative treatment is well documented in the literature (1,3,12). It is known that these patients if treated conservatively will show some improvement over time but can suffer from activity related pain and decreased elbow strength and endurance, especially with flexion and supination (3,8,13). Surgical repair may be through an anterior incision or using Boyd and Anderson's 2-incision technique. The anterior approach, because of extensive dissection, may lead to radial and median nerve palsy (9,16) whereas the Boyd and Anderson approach has been associated with heterotopic ossification and synostosis (9). Over the time, the anterior approach with minimal dissection is becoming more popular. As far as chronic rupture is concerned, surgery becomes more complex. Primary repair can still be carried out within 4 to 6 weeks of injury (15), as was the case in the three patients in our study; proximal mobilisation of the tendon was however necessary in one. As far as the use of the endobutton is concerned, it has been used in the past. Our technique differs from others in that we did minimal sharp dissection, thus minimising the risk of neurological injury. We did not roughen the bony cortex nor made any trough into it, in order to limit the possibility of radioulnar synostosis. We

also did not insert the tendon end in the bone; it was anatomically placed at the radial tuberosity. We drilled only one hole in the radial tuberosity thus limiting the chances of injury to the posterior interosseous nerve and radioulnar synostosis.

For cases where primary repair cannot be done, various grafts have been described, which include fascia lata (8), semitendinosus (7), double looped flexor carpi radialis (10) and tendo Achilles allograft (15).

This study reports surgical outcomes in a small cohort of patients. We need more patients to properly assess this technique and its outcome. We believe rupture of the distal end of the biceps is a surgical condition, unlike rupture of its proximal end. Surgery restores the strength and endurance of the elbow even in chronic cases. Conservative treatment should only be considered for those who are either not fit for surgery or sedentary workers who do not require biceps strength.

*Acknowledgement to Ms Sarah McGrory, graphic designer, Birmingham Heartlands & Solihull (Teaching) Hospital.*

### REFERENCES

1. Agins HJ, Chess JL, Hoekstra DV, Teitge RA. Rupture of the distal insertion of the biceps brachii tendon. *Clin Orthop* 1988; 234 : 34-38.
2. Aldrige JW, Bruno RJ, Strauch RJ, Rosenwasser MP. Management of acute and chronic biceps tendon rupture. *Hand Clinics* 2000; 16 : 497-503.
3. Baker BD, Bierwagen D. Rupture of the distal tendon of the biceps brachii: operative versus non-operative treatment. *J Bone Joint Surg* 1985; 67-A : 414-417.
4. Boyd JB, Anderson LD. A method for the reinsertion of the distal biceps brachii tendon. *J Bone Joint Surg* 1961; 26-A : 428-431.
5. D'Alessandro D, Shields CL, Tibone JE, Chandler RW. Repairs of distal biceps tendon ruptures in athletes. *Am J Sports Med* 1993; 21 : 114-119.
6. Gilcreest EL, Albi P. Unusual lesions of muscles and tendons of the shoulder girdle and upper arm. *Surg Gynaecol Obstet* 1939; 68 : 903-917.
7. Hang DW, Bach BR, Bojchuk J. Repair of chronic ruptures of the distal biceps brachii tendon rupture using free autogenous semitendinosus tendon. *Clin Orthop* 1996; 323 : 188-191.

8. **Hovellius L, Josefsson G.** Rupture of the distal biceps tendon. *Acta Orthop Scand* 1977 ; 48 : 280-282.
9. **Kelly EW, Morrey BF, O'Driscoll SW.** Complication of repair of the distal biceps tendon with the modified two-incision technique. *J Bone Joint Surg* 2000 ; 82-A : 1575-1581.
10. **Levy HJ, Mashoof AA, Morgan D.** Repair of chronic ruptures of the distal biceps tendon using flexor carpi radialis tendon graft. *Am J Sports Med* 2000 ; 28 : 538-540.
11. **Linter S., Fischer T.** Repair of the distal biceps tendon using sutures anchors and an anterior approach. *Clin Orthop* 1996 ; 322 : 116-119.
12. **Morrey BF, Askew LJ, An KN et al.** Rupture of the distal tendon of the biceps brachii: a biomechanical study. *J Bone Joint Surg* 1985 ; 67-A : 418-421.
13. **Rantanen J. and Orava S.** Rupture of the distal biceps tendon *Am J Sports Med* 1999 ; 27 : 128-132.
14. **Safran MR., Graham SC.** Distal biceps tendon ruptures. *Clin Orthop* 2002 ; 404 : 275-283.
15. **Sanchez-Sotelo J, Morrey BF, Adams RA, O'Driscoll SW.** Reconstruction of chronic ruptures of the distal biceps tendon with use of an Achilles tendon allograft. *J Bone Joint Surgery* 2002 ; 84-A : 999-1005.
16. **Sotereanos DG, Pierce TD, Varitimidis SE.** A simplified method for repair of distal biceps tendon ruptures. *J Shoulder Elbow Surg* 2000 ; 9 : 228-233.