



Prophylaxis for heterotopic ossification after primary total hip arthroplasty A cohort study between Indomethacin and Meloxicam

Huub J. L. VAN DER HEIDE, Maarten SPRUIT, Rob SLAPPENDEL, Niels KLOOSTER, Jacques VAN LIMBEEK

The authors have conducted a prospective cohort study of the efficacy of a 7 days administration of Indomethacin (n = 89) versus Meloxicam (n = 92), in the prophylaxis of heterotopic ossification (HO) in primary total hip arthroplasty.

To assess the interobserver variability of the Brooker classification, all radiographs were evaluated by three investigators.

In the Indomethacin group 25 patients developed HO (grade I : 22 , grade III : 2 and grade IV : 1). In the Meloxicam group 34 developed HO (grade I : 30, grade II : 1 and grade III : 3).

We were not able to show any difference between Indomethacin and Meloxicam in preventing heterotopic ossification after primary hip arthroplasty. We found a high interobserver variability in the grading system according to Brooker, in particular for the higher grades (grade II, III and IV).

Lieberman *et al* (25) found more HO after cemented THA in osteoarthritis, and Maloney *et al* found a higher incidence in uncemented THA (8). Pulsed lavage does not affect the incidence of HO (40). Although HO might reduce range of motion, it does not usually alter hip function or produce pain (1,3) except for Brooker grades III to IV. Patient satisfaction has been reported to decrease from 90% good or excellent in patients without HO to 30% good or excellent in the higher grades (12).

To prevent heterotopic ossification, low dose radiation therapy (20,21,27,39,44) or non-steroidal anti-inflammatory drugs (NSAID) may be used (31,32). The prophylactic effect of NSAID's for heterotopic ossification was first observed by Dahl (8) who used Indomethacin as analgesic after THA. Several other studies have illustrated the ability of Indomethacin to prevent heterotopic ossification.

INTRODUCTION

Heterotopic ossification (HO) is frequently observed after primary total hip arthroplasty.

HO has been related to the extent of tissue trauma (16), previous hip surgery (1,26), HO of the contralateral hip (19,33,41), and epidural anaesthesia (16). The incidence is higher after an anterolateral approach compared to a posterior approach (5), and is higher after a transtrochanteric compared to a direct lateral approach (42) or a posterolateral approach (6). Men are more frequently affected (1,26,33,45). There is no agreement in the literature on the influence of cementing in THA. Some studies showed no difference (5,30,35,47), whereas

From Sint Maartenskliniek, Nijmegen, the Netherlands.

Huub J. L. van der Heide, MD, resident
Maarten Spruit, MD, Department Chairman

Department of Orthopaedics

Rob Slappendel, MD PhD, Consultant Anaesthesiologist

Department of Anaesthesiology

Niels Klooster, MD, Consultant Radiologist

Department of Radiology

Jacques van Limbeek, MD PhD, Epidemiologist,
Department Chairman.

Orthopedic Research

Correspondance : Huub J. L. van der Heide, M.D. Department
of Orthopaedics, Sint Maartenskliniek Nijmegen P.O.
Box 9011, 6500 GM Nijmegen, The Netherlands.

E-mail : huub.vanderheide@tiscali.nl

© 2004, Acta Orthopædica Belgica.

Table I

<i>Inclusion criteria</i>	<i>Exclusion Criteria</i>
Primary total hip arthroplasty	Previous surgery on the same hip joint
Spinal or epidural anaesthesia	Included in another study
Able to sign informed consent	History of bleeding disorders
Age 18-85 years	History of gastric ulcer
	Rheumatoid arthritis

Initially, prophylactic treatment was used for months. More recent studies show similar results with treatment periods ranging from 7 days to 6 weeks (4,7,17,18,20,29,36,37,41,49). Indomethacin used for three (43) or four (11) days showed inferior results. The frequency of side effects of Indomethacin cause a serious clinical problem even with a 7-day treatment (7).

The purpose of the present study was to determine if a selective COX-2 inhibitor would show the same decrease in HO with fewer side effects as compared to Indomethacin. The second aim was to evaluate the interobserver variability of the Brooker classification.

PATIENTS AND METHODS

This study was approved by the local ethics committee. Between January 1999 and July 2001, all consecutive patients with osteoarthritis, who were scheduled for a primary total hip arthroplasty, were eligible to participate in this study. The anaesthesiologist selected patients for inclusion or exclusion according to criteria listed in Table I. Randomisation of included patients was done by the department of orthopedic research. A total of 199 patients entered the study, but 18 were excluded: one patient appeared not to have signed the informed consent, three patients did not have their operation, five patients failed to receive prophylaxis and finally the medication was stopped after 2 to 4 days in 1 patient in the Indomethacin group due to the side effects and in 8 patients for unknown reasons (2 in the Indomethacin- and 6 in the Meloxicam-group). Of the 181 patients in this study, 86 underwent an uncemented, 37 a cemented and 58 a hybrid arthroplasty (table V).

There were 124 women and 57 men, mean age 67 years (range 42 to 87 years). Nonsteroidal anti-inflammatory drugs were stopped 10 days before surgery. Paracetamol was allowed. At the day of surgery, all patients received 7.5 mg midazolam orally one hour

before anaesthesia. Anaesthesia was spinal (20 mg bupivacain and 0.1 mg morphine dissolved in 4 ml saline) in all patients.

In all patients a standard posterolateral approach without trochanteric osteotomy was used. All patients received antibiotic prophylaxis immediately before surgery (one single intravenous administration of 1 gram of Cefazolin). Thromboembolic prophylaxis consisted in subcutaneous administration of low molecular weight heparin (nadroparin 10.000 IE once a day) during the first days and continued with acenocoumarol orally for three months. All patients had a vacuum drain for one or two days. Three days after surgery full weight bearing was allowed.

The Indomethacin group received a suppository of 100 mg one hour before surgery and three oral daily doses of 50 mg the next seven days. The Meloxicam group received a suppository of 15 mg one hour before surgery, followed by 15 mg once a day for seven days. No NSAIDs were permitted after this treatment period, if necessary pain was relieved by paracetamol or morphine. Despite the protocol 89 patients received their prophylaxis only during 5 or 6 days (Indomethacin group 19 and Meloxicam group 70). Nineteen patients received NSAIDs during 8 to 15 days (Indomethacin group 16, Meloxicam group 3).

Conventional anteroposterior pelvic radiographs were made five days after surgery, after six weeks, and after six months using the classification of heterotopic ossification by Brooker (table II). To investigate the interobserver variability of this classification system, 195 radiographs were independently evaluated by three investigators (H.v.d.H., M.S., and N.K.). To reach a consensus on radiographs with different observer scores the three investigators met in a joint reading. This study was not blinded, but the investigators who classified the radiographs were blinded concerning the prophylaxis the patients had received.

When the radiographs had been scored, the medical records were consulted to determine which medication each patient had received and to control the length of the treatment.

Table II. – Classification of heterotopic ossification by Brooker

Grade 0	No ossification
Grade I	Isolated bone islands.
Grade II	Bone spurs from the pelvis or proximal femur, the space between opposing surface is 1 cm or more.
Grade III	Bone spurs from the pelvis or proximal femur, the space between opposing bone surface is less than 1 cm.
Grade IV	Apparent bony ankylosis.

The two groups were compared using the chi-square test, with α set at 0.05.

Furthermore we compared these groups with a historic control group, in which the patients did not receive any prophylaxis. In all patients in this control group also a standard posterolateral approach without trochanteric osteotomy was used and the patients had the same demographics and inclusion criteria. This group consisted of 170 patients and has been described by Lemmens (24). In this historic control group 76% developed HO (19% grade 1, 28% grade 2, 17% grade 3 and 12% grade 4. We considered a placebo controlled study design unethical taking into account the effectiveness of NSAIDs reported in the literature (20,31).

The interobserver variability was tested by an agreement analysis giving the weighted Cohen’s kappa as measures of inter-rater agreement.

RESULTS

The results of the classification according to Brooker are shown in table IV. In 74% (n = 146) all observers assigned the HO to the same Brooker grade, but for most grades II to IV the scores were not equivalent.

Table III. – Cases in which all investigators classified the radiographs to the same Brooker classification, or in which there was lack of agreement (n = 195).

Brooker	Agreement (n = 145)	Lack of agreement (n = 50)
0	115	14
I	28	29
II	1	-
III	1	6
IV	-	1

After 6 months, 59 cases (33%) showed heterotopic ossification. High ossification grades III or IV were present in 6 of these cases (3%). The results for the different groups are shown in table V.

Although most patients in the Meloxicam group received only 5 days of prophylaxis we did not observe a difference (p = 0.11) between the Indomethacin group and the Meloxicam group. However, the difference was statistically significant between the historic control group, in which the patients did not receive any prophylaxis against heterotopic ossification, and both the Indomethacin (p < 0.001) and the Meloxicam group (p < 0.001) (fig 1).

Looking at the length of treatment in both experimental groups combined we found a significant difference (p = 0.01) between those who received prophylaxis for five or six days, and those who received 7 days or more.

In 9 patients (excluded from the study : see Patients and Methods) the medication was stopped

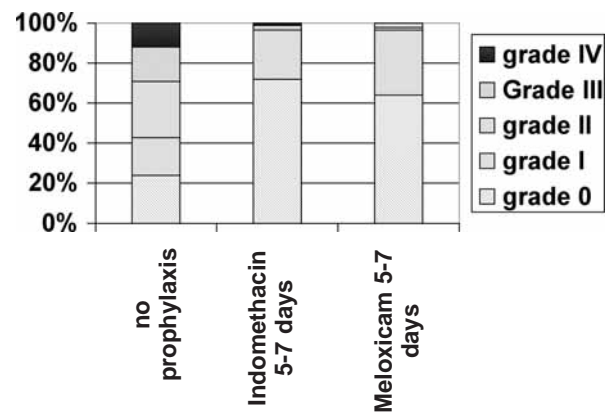


Fig. 1. — The first bar represents the historical control group not receiving any prophylaxis (24), the second and third represent the results of this study.

Table IV. – The weighted kappa values for the different observers, 95% confidence interval between brackets. OS = Orthopedic Surgeon, OR= Orthopedic Resident, R = Radiologist

	Brooker grade 0 or I	Grade II, III or IV
OS versus OR	0,66 (0,53-0,80)	0,38 (0,05-0,69)
OS versus R	0,70 (0,57-0,82)	0,64 (0,43-0,85)
OR versus R	0,58 (0,44-0,72)	0,74 (0,50-0,97)

after 2 to 4 days : in 1 patient in the Indomethacin group due to the side effects and in 8 patients for unknown reasons (2 in the Indomethacin- and 6 in the Meloxicam-group). Two of these 9 patients developed grade 3 HO, one in each group.

No difference was found for cemented or uncemented THA. Although the prevalence of HO was higher in men, this difference was not significant.

Complications

One patient had a massive bleeding from a gastric ulcer on the seventh day after starting Indomethacin, and was treated with endoscopic sclerotherapy and received 7 units of red blood cells. In two patients, one in each group, a gastric ulcer perforated and laparotomy and closure of the perforation were performed. Both patients were *Helicobacter Pylori* negative.

In 16 patients the wound drained for more than a week without signs of infection (6 in the Melo-

xicam group, 10 in the Indomethacin group). One was treated surgically; the others were treated conservatively and received continued prophylactic antibiotics.

One patient had a superficial wound infection, which was treated with antibiotics. Three patients had a deep infection ; one was treated with antibiotics, one with a one-stage revision and one prosthesis needed to be removed.

DISCUSSION

This study evaluates the effect of the selective COX-2 inhibitor Meloxicam versus Indomethacin to prevent heterotopic ossification after primary THA.

We could not detect a difference between the two treatments. When comparing the results with a historical control group, the difference between both experimental groups and the historical control group (no treatment) is significant (24). We considered a placebo controlled study design unethical taking into account the effectiveness of NSAIDs reported in the literature (20,31).

Given the results of this study in preventing HO and comparable reported results (31), and given fewer side-effects with a selective COX-2 inhibitor, HO prophylaxis in our clinic has now been changed from Indomethacin 50 mg 3 times daily to Meloxicam 15 mg once daily for seven days.

Table V. – Heterotopic ossification after primary total hip arthroplasty

	Indomethacin (total group)	Meloxicam (total group)	Indomethacin 5-6 days	Meloxicam 5-6 days	Indomethacin 7 days	Meloxicam 7 days	Indomethacin > 7 days	Meloxicam >7 days
Number of patients (M/F)	89 (33/56)	92 (22/70)	19 (8/11)	70 (10/60)	54 (10/44)	19 (4/15)	16 (5/11)	3 (-/3)
Type of prosthesis (uncemented/ cemented/hybrid)	37/21/31	49/16/27	8/3/8	35/13/22	24/13/17	11/3/6	8/2/6	3/-/-
Brooker								
Grade 0	64	58	8	41	44	14	12	3
Grade I	22	30	9	26	9	4	4	
Grade II	0	1						
Grade III	2	3	1	2	1	1		
Grade IV	1	0	1					

Kristensen *et al* (23) found increased perioperative blood loss after the use of Indomethacin, due to the reduction in platelet aggregation. In a subgroup of our study group Weber *et al* (46) found a decrease in per- and postoperative blood loss of 15% in the Meloxicam group compared to the Indomethacin group. Although Indomethacin is a powerful drug to prevent heterotopic ossification, the high incidence of side effects (31) poses a clinical problem. Knelles *et al* (20) showed 22 % side effects resulting in study withdrawal of 2.2 %. Cella *et al* (7) revealed contraindications to Indomethacin in 19 % of patients, and one third of their patients were withdrawn from the study. It seems the treatment period of one week with Indomethacin is the shortest effective period (43). Because of the side effects accompanying Indomethacin, several other NSAIDs have been studied. Naproxen for 8 days or 4 weeks (13,14), or Tenoxicam for 5 days and 6 weeks (6) have the same prophylactic effect as Indomethacin. Ibuprofen used for 5 (22) or 10 (2) days shows less favorable results, but after three weeks of Ibuprofen the effect is comparable to that of Indomethacin (34,41).

In recent years COX-2 selective inhibitors have been developed, with less side-effects and the same pain reducing effects (9,10,15,38).

In our study we found a 74% agreement and a weighted kappa ranging from 0.58 to 0.70 for grade 0 and I and from 0.38 to 0.74 for grade II, III or IV. In general kappa values between 0.4 and 0.7 are considered to show a fair to good interobserver reliability.

To our knowledge the only study describing the reliability and validity of the Brooker classification shows 68% agreement and a weighted kappa of 0.57 (48). That study based on 77 radiographs does not give the prevalence of HO, furthermore no distinction is made between the inconsistencies between the different grades.

Although the Brooker classification has been used in most studies, we found a high interobserver variability, particularly for the high grades (grade II, III and IV), but also in some grade 0 and grade I cases with very small bone islands around the greater trochanter. Even small pieces of bone in

the greater trochanter region on the radiograph six months after surgery, which were not present on the direct postoperative radiograph, were scored as grade I. In the six radiographs showing grade III and IV ossification, the three observers agreed there was a significant ossification, but there was no agreement on the presence of a bony ankylosis.

CONCLUSIONS

Although we found no difference between the Meloxicam group and the Indomethacin group in preventing HO, this study lacks the power to show that the results of the two different prophylaxes are the same. In order to have a chance to demonstrate that both treatments have similar effects, we would have needed 1621 patients (with alpha at 5% and beta at 20%). When comparing the results with a historical control group, which did not receive prophylaxis for HO, the difference for both treatments is significant, even though the majority of the patients in the Meloxicam group received their prophylaxis for only five days. Because of the fewer side effects shown in other studies and comparable results in preventing HO, the HO prophylaxis in our clinic has now been changed from Indomethacin 3 times daily 50 mg to Meloxicam 15 mg once daily for seven days.

Although we found a high interobserver variability in the grading system according to Brooker especially for grade II to IV, these kappa values are still considered to show a good reliability.

ACKNOWLEDGEMENTS

The support of A. Kyriazopoulos, MD and D. Langeloo, MD, from the department of orthopedics and M.L.T. Bugter and E.W.G. Weber, both anaesthesiologists, is gratefully acknowledged. Furthermore we would like to thank Miss P. Anderson for her support in the study design and corrections in the manuscript.

REFERENCES

1. **Ahrengart L.** Periarticular heterotopic ossification after total hip arthroplasty. Risk factors and consequences. *Clin Orthop* 1991 ; 263 : 49-58.
2. **Ahrengart L, Blomgren G, Tornkvist H.** Short-term ibuprofen to prevent ossification after hip arthroplasty. No effects in a prospective randomized study of 47 arthrosis cases. *Acta Orthop Scand* 1994 ; 65 : 139-141.
3. **Ahrengart L, Lindgren U.** Functional significance of heterotopic bone formation after total hip arthroplasty. *J Arthroplasty* 1989 ; 4 : 125-131.
4. **Amstutz HC, Fowble VA, Schmalzried TP, Dorey FJ.** Short-course indomethacin prevents heterotopic ossification in a high-risk population following total hip arthroplasty. *J Arthroplasty* 1997 ; 12 : 126-132.
5. **Bischoff R, Dunlap J, Carpenter L, DeMouy E, Barrack R.** Heterotopic ossification following uncemented total hip arthroplasty. Effect of the operative approach. *J Arthroplasty* 1994 ; 9 : 641-644.
6. **Bursens A, Thiery J, Kohl P, Molderez A, Haazen L.** Prevention of heterotopic ossification with tenoxicam following total hip arthroplasty : a double-blind, placebo-controlled dose-finding study. *Acta Orthop Belg* 1995 ; 61 : 205-211.
7. **Cella JP, Salvati EA, Sculco TP.** Indomethacin for the prevention of heterotopic ossification following total hip arthroplasty. Effectiveness, contraindications, and adverse effects. *J Arthroplasty* 1988 ; 3 : 229-234.
8. **Dahl HK.** Kliniske observasjoner. *Symposium on hip arthroprothese. Blindern, MSD, Norway* 1975; 37-46.
9. **Degner F, Turck D, Pairet M.** Meloxicam, Pharmacological, Pharmacokinetic and Clinical Profile. *Drugs of today* 1998 ; 34.
10. **Dequeker J, Hawkey C, Kahan A, Steinbruck K, Alegre C, et al.** Improvement in gastrointestinal tolerability of the selective cyclooxygenase (COX)-2 inhibitor, meloxicam, compared with piroxicam : results of the safety and efficacy large-scale evaluation of cox-inhibiting therapies (select) trial in osteoarthritis. *Br J Rheumatology* 1998 ; 37 : 946-951.
11. **Dorn U, Grethen C, Effenberger H, Berka H, Ramsauer T, Drekonja T.** Indomethacin for prevention of heterotopic ossification after hip arthroplasty. A randomized comparison between 4 and 8 days of treatment. *Acta Orthop Scand* 1998 ; 69 : 107-110.
12. **Eggl S, Rodriguez J, Ganz R.** Heterotopic ossification in total hip arthroplasty : the significance for clinical outcome. *Acta Orthop Belg* 2000 ; 66 : 174-180.
13. **Gebuhr P, Soelberg M, Orsnes T, Wilbek H.** Naproxen prevention of heterotopic ossification after hip arthroplasty. A prospective control study of 55 patients. *Acta Orthop Scand* 1991 ; 62 : 226-229.
14. **Gebuhr P, Wilbek H, Soelberg M.** Naproxen for 8 days can prevent heterotopic ossification after hip arthroplasty. *Clin Orthop* 1995 ; 314 : 166-169.
15. **Hawkey C, Kahan A, Steinbruck K, Alegre C, et al.** Gastrointestinal tolerability of meloxicam compared to diclofenac in osteoarthritis patients. *Br J Rheumatology* 1998 ; 37 : 937-945.
16. **Hierton C, Blomgren G, Lindgren U.** Factors associated with heterotopic bone formation in cemented total hip prostheses. *Acta Orthop Scand* 1983 ; 54 : 698-702.
17. **Kjaersgaard-Andersen P, Nafei A, Teichert G et al.** Indomethacin for prevention of heterotopic ossification. A randomized controlled study in 41 hip arthroplasties. *Acta Orthop Scand* 1993 ; 64 : 639-642.
18. **Kjaersgaard-Andersen P, Schmidt SA.** Total hip arthroplasty. The role of antiinflammatory medications in the prevention of heterotopic ossification. *Clin Orthop.* 1991 ; 263 :78-86.
19. **Kjaersgaard-Andersen P, Steinke MS, Hougaard K, Sojbjerg JO, Jensen J.** Heterotopic bone formation following hip arthroplasty. A retrospective study of 65 bilateral cases. *Acta Orthop Scand* 1991 ; 62 : 223-225.
20. **Knelles D, Barthel T, Karrer A, Kraus U, Eulert J, Kolbl O.** Prevention of heterotopic ossification after total hip replacement. A prospective, randomised study using acetylsalicylic acid, indomethacin and fractional or single-dose irradiation. *J Bone Joint Surg* 1997 ; 79-B : 596-602.
21. **Kolbl O, Knelles D, Barthel T, Kraus U, Flentje M, Eulert J.** Randomized trial comparing early postoperative irradiation vs. the use of nonsteroidal antiinflammatory drugs for prevention of heterotopic ossification following prosthetic total hip replacement. *In J Radiat Oncol Biol Phys* 1997 ; 39 : 961-966.
22. **Koorevaar CT, Hu HP, Lemmens A, van Kampen A.** No effective prophylaxis of heterotopic ossification with short-term ibuprofen. *Arch Orthop Trauma Surg* 1999 ; 119 : 183-185.
23. **Kristensen SS, Pedersen P, Pedersen NW, Schmidt SA, Kjaersgaard-Andersen P.** Combined treatment with indomethacin and low-dose heparin after total hip replacement. A double-blind placebo-controlled clinical trial. *J Bone Joint Surg* 1990 ; 72-B : 447-449.
24. **Lemmens A.** Analyse van de radiologische veranderingen rond de totale heupprothese volgens Charnley-Muller. *Thesis, Nijmegen, The Netherlands.* 1987.
25. **Lieberman IH, Moran E, Hastings DE, Bogoch ER.** Heterotopic ossification after primary cemented and non-cemented total hip arthroplasty in patients with osteoarthritis and rheumatoid arthritis. *Can J Surg* 1994 ; 37 : 135-139.
26. **Lindholm TS, Viljakka T, Vankka E, Popov L, Lindholm TC.** Development of heterotopic ossification around the hip. A long-term follow-up of patients who underwent surgery with two different types of endoprostheses. *Arch Orthop Trauma Surg* 1986 ; 105 : 263-267.
27. **Maloney WJ, Jasty M, Willett C, Mulroy RD, Jr.,**

- Harris WH.** Prophylaxis for heterotopic bone formation after total hip arthroplasty using low-dose radiation in high-risk patients. *Clin Orthop.* 1992 ; 280 : 230-234.
28. **Maloney WJ, Krushell RJ, Jasty M, Harris WH.** Incidence of heterotopic ossification after total hip replacement: effect of the type of fixation of the femoral component. *J Bone Joint Surg* 1991 ; 73-A : 191-193.
 29. **McMahon JS, Waddell JP, Morton J.** Effect of short-course indomethacin on heterotopic bone formation after uncemented total hip arthroplasty. *J Arthroplasty* 1991 ; 6 : 259-264.
 30. **Nayak KN, Mulliken B, Rorabeck CH, Bourne RB, Woolfrey MR.** Prevalence of heterotopic ossification in cemented versus noncemented total hip joint replacement in patients with osteoarthritis : a randomized clinical trial. *Can J Surg* 1997 ; 40 : 368-374.
 31. **Neal B, Rodgers A, Dunn L, Fransen M.** Non-steroidal anti-inflammatory drugs for preventing heterotopic bone formation after hip arthroplasty. *Cochrane Database Syst Rev* 2000 ; CD001160.
 32. **Neal BC, Rodgers A, Clark T et al.** A systematic survey of 13 randomized trials of non-steroidal anti-inflammatory drugs for the prevention of heterotopic bone formation after major hip surgery. *Acta Orthop Scand* 2000 ; 71 : 122-128.
 33. **Nollen JG, van Douveren FQ.** Ectopic ossification in hip arthroplasty. A retrospective study of predisposing factors in 637 cases. *Acta Orthop Scand* 1993 ; 64 : 185-187.
 34. **Persson PE, Sodemann B, Nilsson OS.** Preventive effects of ibuprofen on periarticular heterotopic ossification after total hip arthroplasty. A randomized double-blind prospective study of treatment time. *Acta Orthop Scand.* 1998 ; 69 : 111-115.
 35. **Purtill JJ, Eng K, Rothman RH, Hozack WJ.** Heterotopic ossification. Incidence in cemented versus cementless total hip arthroplasty. *J Arthroplasty* 1996 ; 11 : 58-63.
 36. **Ritter MA, Gioe TJ.** The effect of indomethacin on pararticular ectopic ossification following total hip arthroplasty. *Clin Orthop* 1982 ; 113-117.
 37. **Schmidt SA, Kjaersgaard-Andersen P, Pedersen NW, Kristensen SS, Pedersen P, Nielsen JB.** The use of indomethacin to prevent the formation of heterotopic bone after total hip replacement. A randomized, double-blind clinical trial. *J Bone Joint Surg* 1988 ; 70-A : 834-838.
 38. **Schoenfeld P.** Gastrointestinal safety profile of meloxicam : a meta analysis and systemic review of randomized controlled trials. *Am J Med* 1999 ; 107 (suppl 6a) : 48s-54s.
 39. **Sell S, Willms R, Jany R et al.** The suppression of heterotopic ossifications : radiation versus NSAID therapy — a prospective study. *J Arthroplasty* 1998 ; 13 : 854-859.
 40. **Sneath RJ, Bindi FD, Davies J, Parnell EJ.** The effect of pulsed irrigation on the incidence of heterotopic ossification after total hip arthroplasty. *J Arthroplasty* 2001 ; 16 : 547-551.
 41. **Sodemann B, Persson PE, Nilsson OS.** Prevention of heterotopic ossification by nonsteroid antiinflammatory drugs after total hip arthroplasty. *Clin Orthop* 1988 ; 237 : 158-163.
 42. **Testa NN, Mazur KU.** Heterotopic ossification after direct lateral approach and transtrochanteric approach to the hip. *Orthop Rev* 1988 ; 17 : 965-971.
 43. **van der Heide HJ, Koorevaar RT, Schreurs BW, van KA, Lemmens A.** Indomethacin for 3 days is not effective as prophylaxis for heterotopic ossification after primary total hip arthroplasty. *J Arthroplasty* 1999 ; 14 : 796-799.
 44. **van Leeuwen WM, Deckers P, de Lange WJ.** Preoperative irradiation for prophylaxis of ectopic ossification after hip arthroplasty. A randomized study in 62 hips. *Acta Orthop Scand* 1998 ; 69 : 116-118.
 45. **Vastel L, Kerboull L, Anract P, Kerboull M.** Heterotopic ossification after total hip arthroplasty : risk factors and prevention. *Rev Rhum Engl Ed* 1998 ; 65 : 238-244.
 46. **Weber EWG, Slappendel R, Durieux ME, Dirksen R, van der Heide HJ, Spruit M.** COX 2 selectivity of non-steroidal anti-inflammatory drugs and perioperative blood loss in hip surgery. A randomized comparison of indomethacin and meloxicam. *Eur J Anaesthesiologie* 2003 ; 20 : 963-966.
 47. **Wixson RL, Stulberg SD, Mehlhoff M.** Total hip replacement with cemented, uncemented, and hybrid prostheses. A comparison of clinical and radiographic results at two to four years. *J Bone Joint Surg* 1991 ; 73-A : 257-270.
 48. **Wright JG, Moran E, Bogoch E.** Reliability and validity of the grading of heterotopic ossification. *J Arthroplasty* 1994 ; 9 : 549-553.
 49. **Wurnig C, Eyb R, Auersperg V.** Indomethacin for prevention of ectopic ossification in cementless hip arthroplasties. A prospective 1-year study of 100 cases. *Acta Orthop Scand* 1992 ; 63 : 628-630.