



Is systematic long-term sonographic follow-up after arthroscopic rotator cuff repair useful in asymptomatic patients ?

Emilie DESPORTES, Mathieu LEFERE, Pierre-Henri FLURIN, Pierre ABADIE, Lionel PESQUER, Benjamin DALLAUDIERE

Department of Radiology, University Hospitals Gasthuisberg, Leuven, Belgium

Objective : To establish whether ultrasonographic (US) appearance is correlated to functional outcome in asymptomatic patients 12 months after rotator cuff repair.

Materials and methods : 26 asymptomatic patients at twelve months after arthroscopic cuff repair and 26 controls were retrospectively included. A clinical score (Constant's Shoulder Score, CSS) was compared with a US score (the modified Sugaya Score, mSS). The minimal thickness of the anterior and posterior parts of the cuff was also measured.

Results : CSS improved significantly from preoperatively to postoperatively (mean increased from 41 to 82.6, $p < .001$). Correlation between the postoperative CSS and the minimal thickness of the cuff at its anterior and posterior part ($p = 0.55$ and $p = 0.13$) was not significant. There was also no significant correlation between the postoperative CSS and mSS ($p = 0.34$).

Conclusion : The sonographic appearance of the cuff repair is not correlated to the functional outcome at 12 months after arthroscopic surgery in asymptomatic patients.

Keywords : ultrasound ; shoulder ; cuff ; arthroscopic ; postoperative ; Constant's Shoulder Score ; repair ; asymptomatic.

INTRODUCTION

Arthroscopic rotator cuff repair leads to high rates of satisfaction (92%) and good functional re-

sults (17,29). While avoiding large scars and deltoid tears, this surgical technique allows the detection and treatment of associated shoulder pathologies that are sometimes overlooked on preoperative imaging studies. Moreover, arthroscopic repair is a faster procedure with a better clinical functional outcome, resulting in a superior integrity of the repaired cuff compared with open surgery (2,21,26).

-
- Emilie Desportes^{1,2}, MD.
 - Mathieu Lefere³, MD.
 - Pierre-Henri Flurin⁴, MD.
 - Pierre Abadie⁴, MD.
 - Lionel Pesquer¹, MD.
 - Benjamin Dallaudiere^{1,6}, MD, PhD.

¹Department of Musculoskeletal Radiology, Clinique du sport de Bordeaux-Mérignac, Mérignac, France.

²Medicine Faculty of Paris Descartes University - Paris 5, Paris, France.

³Department of Radiology, University Hospitals Gasthuisberg, Leuven, Belgium.

⁴Department of Orthopedics, Clinique du sport de Bordeaux-Mérignac, Mérignac, France.

⁵Department of Orthopedics, Xavier Bichat - Claude Bernard University, Assistance Publique - Hôpitaux de Paris, Paris, France.

⁶Department of Musculoskeletal Imaging, Centre Hospitalier Universitaire Pellegrin, Bordeaux, France.

Correspondence : Mathieu Lefere, Department of Radiology, University Hospitals Gasthuisberg, Herestraat 49, 3000 Leuven, Belgium. E-mail : mathieu.lefere@uzleuven.be

© 2015, Acta Orthopædica Belgica.

Usually, postoperative follow-up after arthroscopic cuff repair includes a physical examination with functional testing using the Constant Shoulder Score on at least three occasions (immediately, at 3 months and at 12 months post surgery) (5). This clinical consultation is often complemented with an ultrasound (US) study despite 75 to 82% of patients being asymptomatic at that moment (6,27).

Indeed, in association with plain radiographs, US is an effective imaging modality in the assessment of rotator cuff disorders (7,10,20) because of its availability and lower cost compared to magnetic resonance imaging (MRI) and computed tomography arthrography. Ultrasound also allows for a dynamic evaluation and overcomes metal artefacts. Moreover, Prickett *et al* have shown that US is an excellent imaging modality for the evaluation of the integrity of the rotator cuff in postoperative shoulders (13). Nevertheless, it takes a skilled operator to perform an accurate sonographic evaluation of the shoulder (16,22), particularly in post-operative cases, since thinning and other shape abnormalities of the rotator cuff are still present after surgery (12,19). To avoid a high intra- and inter-observer variability, the use of reproducible scores seems essential. For that purpose, Sugaya *et al* classified the degree of integrity of repaired rotator cuffs into five types on T2-weighted MRI sequences (24), while Carillon *et al* modified it for ultrasound (4).

Quite some studies have focused on cross-sectional imaging and functional outcome of the cuff after arthroscopic repair (2,15,22,24,25). The anatomic appearance of the cuff on ultrasound at 12 or 24 months has been investigated, but mainly in symptomatic patients with massive cuff tears, and without the use of reproducible scores (1,3,9). To our knowledge, there are no studies on the reproducibility of the ultrasonographic findings 12 months after surgery in asymptomatic patients. As such, the added value of systematic sonographic follow-up at mid- to longterm in these patients remains unclear.

Therefore, the purpose of our study was to compare the clinical assessment (using Constant's Shoulder Score) with the ultrasonographic findings (using a reproducible sonographic score) at 12 months after arthroscopic rotator cuff repair in asymptomatic patients.

MATERIALS AND METHODS

We conducted a single center descriptive cohort study on 26 consecutive, asymptomatic patients who underwent an arthroscopic rotator cuff repair between January 2011 and November 2011. The orthopaedic surgeons referred all the patients to our imaging department for systematic radiographic and sonographic assessment 12 months after surgery. We constituted a control group of 26 asymptomatic volunteers, with no history of shoulder pain or shoulder surgery, matched to the control group by age and sex. All the patients were informed of the study procedure and gave their written informed consent.

The surgical arthroscopic procedure (PA, PHF) consisted of three steps : First, a diagnostic arthroscopy was performed to evaluate the injuries, especially to the rotator cuff and to the biceps tendon. Secondly, a tenotomy or tenodesis of the long head of the biceps was performed. Thirdly, the arthroscopic device was redirected to the subacromial space, and a complete bursectomy was performed with removal of the acromio-clavicular joint osteophytes. Finally, the degenerated and frayed tissue around the rotator cuff edge was removed and the edge of the cuff tear was brought back to its normal position without undue tension, using suture anchors.

All patients were seen before surgery and at 12 months after treatment by two senior shoulder orthopaedists with respectively 5 and 20 years of experience (PA, PHF). Constant's Shoulder Score was systematically calculated. This clinical scoring system includes a gradation of pain (15 points), daily activities (20 points), range of motion (40 points) and shoulder power at 90 degrees abduction (25 points) (5). It enables the establishment of normal values for a given age and sex (14).

All patients underwent an ultrasound exam 12 months after surgery by four experienced musculoskeletal radiologists with five to twenty years of experience (LP, BD and colleagues). We used a 17 MHz linear probe with both grayscale and color Doppler functionalities (IU 22, Philips Medical healthcare®, Amsterdam, Netherlands), although for this study, only the grayscale setting was used. Rotator cuff repair was assessed by systematically acquiring six images : an axial view of the long bicipital and subscapularis tendons ; a coronal oblique image of the supraspinatus and infraspinatus tendons ; a sagittal oblique view to measure the anterior and posterior thickness of the rotator cuff, and finally a coronal view of the acromio-clavicular joint. We systematically acquired the same six views in the control group. All pictures were collected on a commercially available PACS (Fuji®).

Patients' and controls' identities were removed from all images. Two musculoskeletal radiologists with one and five years of experience, respectively (ED, BD) evaluated the images. They were blinded to the clinical and functional information, and assessed all US images on the PACS by consensus and in random order.

For each patient, the aspect of the repaired rotator cuff was initially assessed. Then, the smallest anterior and posterior thickness of the cuff (considered as the most pathologically significant values) was measured on the sagittal oblique view. Finally, the patients were classified using the modified Sugaya score ; type 1 : normal thickness and homogeneous aspect of the cuff ; type 2 : nor-

mal thickness and heterogeneous echogenicity of the cuff ; type 3 : insufficient thickness without discontinuity of the cuff ; type 4 : minor discontinuity suggesting a small cuff tear ; type 5 : major discontinuity suggesting a complete rupture of the cuff (24) (Fig. 1). In addition, the preoperative and postoperative Constant Shoulder Scores were determined for each patient. The control group was assessed using the exact same method.

Statistical analysis was performed using the SAS® software.

We compared the preoperative and postoperative Constant Shoulder Score values using the Wilcoxon signed-rank test. The postoperative Constant Score was

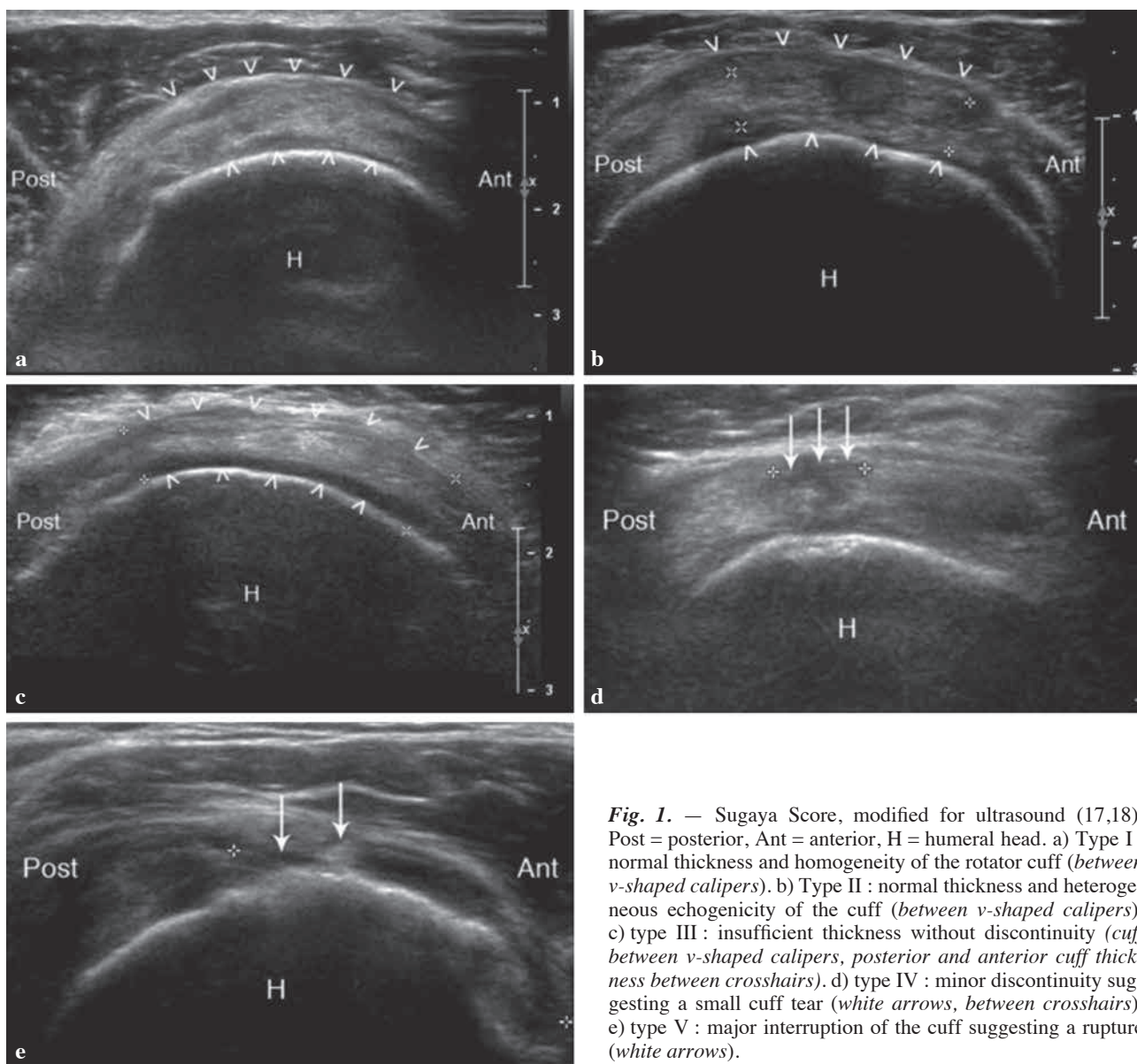


Fig. 1. — Sugaya Score, modified for ultrasound (17,18). Post = posterior, Ant = anterior, H = humeral head. a) Type I : normal thickness and homogeneity of the rotator cuff (between v-shaped calipers). b) Type II : normal thickness and heterogeneous echogenicity of the cuff (between v-shaped calipers). c) type III : insufficient thickness without discontinuity (cuff between v-shaped calipers, posterior and anterior cuff thickness between crosshairs). d) type IV : minor discontinuity suggesting a small cuff tear (white arrows, between crosshairs). e) type V : major interruption of the cuff suggesting a rupture (white arrows).

compared with the thickness of the rotator cuff (at its thinnest anterior and posterior parts) using Pearson correlation coefficients. The postoperative Constant Score was compared to the modified Sugaya Score using the Kruskal-Wallis test. Finally, we compared the thickness of the rotator cuff in the patient group with the control group using the Wilcoxon signed-rank test. A *p*-value less than 0.05 was considered as statistically significant.

RESULTS

Population

Twenty-six patients (11 men and 15 women) were included in this study. Mean age of the patients was 77 ± 4.54 years and median age was 77 years. For the 26 controls (11 men and 15 women), mean age was 75 ± 5.45 years and median age was 76 years.

Surgical procedure

All of the 26 included patients underwent arthroscopic repair of the rotator cuff with tenotomy of the long head of biceps tendon and partial resection of the distal clavicle. The transosseous-suture anchor technique was used (Healix type, Mitek) (1 row (*n* = 22), 2 rows (*n* = 2), 3 rows (*n* = 1)).

Clinical follow-up

Before surgery, mean Constant Shoulder Score was 41.6 ± 10.7 with a median of 39. At 12 months after surgery, mean Constant Shoulder Score was 82.6 ± 6.2 with a median of 83. All patients were asymptomatic after surgery (Table I).

Sonographic follow-up

Patient group

Four patients had a homogeneous cuff, twenty-two had a heterogeneous cuff, six had small tears and two had a major tear.

The minimal thickness of the cuff, measured in its anterior part was, on average 4.6 ± 1.9 mm, with a median of 4.9 mm.

Table I. — Normal values for Constant's Shoulder Score as determined by Katolik *et al* (14)

Age (y)	Men	Women
18-29	95	88
30-39	95	87
40-49	96	86
50-59	94	84
60-69	92	83
≥ 70	88	81

In its posterior part, the mean was 5.1 ± 1.1 mm, with a median of 5 mm.

The average value, all measures combined, was 4.8 ± 1.2 mm, with a median of 4.8 mm.

Using the modified Sugaya Score for ultrasound, four patients had a type I cuff, eleven had a type II cuff, three had a type III cuff, six had a type IV cuff and two had a type V cuff.

Control group

Twelve subjects had a homogeneous cuff, fourteen had a heterogeneous cuff and four had an interstitial tear below 5 mm.

The minimal thickness of the cuff measured at its anterior part was 4.8 ± 0.6 mm, with a median of 4.9 mm.

The minimal thickness of the cuff measured at its posterior part was 4.7 ± 0.8 mm, median was 4.8 mm.

The modified Sugaya scores of all patients are summarized in table II.

Data analysis

At twelve months after surgery, all patients presented a significant clinical improvement (*p* = 0.0001). This was measured by comparing the preoperative and postoperative Constant Shoulder scores.

There was no significant correlation between the postoperative Constant Score and the minimal thickness of the cuff at its anterior (*p* = 0.55) or posterior (*p* = 0.13) part. There was no significant correlation between the postoperative Constant

Table II. — Mean postoperative Constant Score and number of patients (*n*) for each type of cuff using the modified Sugaya Score for ultrasound (I to V)

modified Sugaya Score	postoperative Constant Score	<i>n</i>
I	86	4
II	83,1	11
III	85	3
IV	80,7	6
V	75	2

score and the modified Sugaya score for ultrasound ($p = 0.34$).

The minimal thickness of the cuff did not significantly differ between the control group and the patient group ($p = 0.24$ for the anterior cuff, $p = 0.70$ for the posterior cuff).

DISCUSSION

Our study demonstrates for the first time that there was no correlation between the postoperative Constant Score and the sonographic assessment after arthroscopic rotator cuff repair at 12 months follow up in asymptomatic patients.

Because of the broad availability, low cost and efficiency of ultrasound, many studies have tried to evaluate and correlate the postoperative clinical outcome to the anatomical changes seen in the rotator cuff on ultrasound (8). Unfortunately, these series have made contradictory conclusions regarding such correlation. Most of the time, cuff tears are large and massive, making a reproducible sonographic score difficult, if not impossible to obtain. Nonetheless, Galatz *et al* concluded that there could be a relationship between sonographic cuff integrity and functional outcome in some patients. In their experience, 17 of 18 repaired cuffs had a recurrent defect while at the same time, two-thirds of the patients had good functional results after a follow-up time of at least 12 months (9). Anderson *et al* reported a high correlation between cuff integrity and increased muscle strength in elevation and external rotation at a mean follow-up of 30 months in full-thickness rotator cuff tears (1). Carillon *et al* per-

formed a sonographic follow-up study in rotator cuff repairs after six months, showing that there was a high correlation between Constant Score and modified Sugaya Score (4). Yoo *et al* on the other hand, showed that in massive tears, after a mean follow-up time of 30 months with ultrasound and conventional radiographs, the functional outcome improved regardless of a failure of healing, although ultrasound was not performed in all patients (28).

Given these discordant results with ultrasound, magnetic resonance imaging (MRI) may be of interest in the assessment of postoperative recurrent rotator cuff tears.

Indeed, even if both imaging modalities appear to be reliable to detect the presence of a rotator cuff tear (8), MRI is generally considered to be the imaging modality of choice in suspected rotator cuff lesions and the evaluation of rotator cuff repairs, because of its non-invasive and reproducible nature (11,18). Sugaya *et al* have evaluated the integrity of cuff repairs with MRI at 14 months postoperatively, suggesting that shoulders with a type-V repair (large remaining cuff tear) demonstrated significantly inferior functional outcome in terms of scores and strength compared with the other types (24). In the same line, Jost *et al* suggested that the clinical outcome correlated significantly with the size of the postoperative tear seen on MRI (13). On the other hand, prospective studies have shown that the integrity of the repair as seen on MRI has no influence on the functional outcome, including muscle strength (15). So despite its lower observer bias, MRI also presents conflicting results regarding the assessment of rotator cuff repairs.

In our study, we strictly focused on asymptomatic patients at mid-term follow-up by including a systematic clinical and sonographic examination at 12 months, using a systematic and reproducible method. Moreover, we chose to include all type of tears (small, medium-sized and massive ones) unlike most other studies that were limited to massive tears in symptomatic patients. Lastly, we used a validated scoring system and constituted a control group.

Our study has several limitations. Firstly, as with any technique, sonographic evaluation is subject to interobserver variability. In order to reduce this

bias, we evaluated all sonographic views by consensus and used a reproducible score. Also, our study was retrospective : we analysed images on a PACS using the six systematic views used in our institution ; the lack of cine clips may have reduced the accuracy of this study. Finally, the number of patients included in our study (n = 52) was limited and future prospective studies with a longer follow-up time will be needed to confirm our initial results.

This is however, to our knowledge, the only study assessing the sonographic appearance of the cuff at twelve months after surgery in asymptomatic patients after arthroscopic cuff repair, by using a reproducible sonographical and clinical score.

CONCLUSION

Our study suggests that the sonographic appearance of the rotator cuff in asymptomatic patients at twelve months after arthroscopic repair is not significantly correlated to the functional outcome. For that reason and given the limitations of the technique, there seems to be no interest in performing a systematic postoperative sonographic evaluation of the cuff repair at mid- to longterm in patients with good functional results. We believe this should be reserved for symptomatic patients. Furthermore, in cases where a surgical re-intervention is considered, it may be advisable to complement the sonographic evaluation with MRI or arthro-CT, to improve the diagnostic performance.

REFERENCES

1. **Anderson K, Boothby M, Aschenbrener D, Vanholsbeeck M.** Outcome and structural integrity after arthroscopic rotator cuff repair using 2 rows of fixation : minimum 2-year follow-up. *Am J Sports Med* 2006 ; 34 : 1899-1905.
2. **Bishop J, Klepps S, Lo IK et al.** Cuff integrity after arthroscopic versus open rotator cuff repair : a prospective study. *J Shoulder Elbow Surg* 2006 ; 15 : 290-229.
3. **Boyer P, Bouthors C, Delcourt T et al.** Arthroscopic double-row cuff repair with suture-bridging : a structural and functional comparison of two techniques. *Knee Surg Sports Traumatol Arthrosc* 2013 (in press).
4. **Constant CR, Murley AH.** A clinical method of functional assessment of the shoulder. *Clin Orthop Relat Res* 1987 ; 214 : 160-164.
5. **Cotten A.** Imagerie musculo-squelettique tome 2. Pathologies loco-regionales. Elsevier Masson, France, 2008, pp 572-573.
6. **Crass JR, Craig EV, Bretzke C, Feinberg SB.** Ultrasonography of the rotator cuff. *Radiographics* 1985 ; 5 : 941-953.
7. **Frei R, Chládek P, Trc T, Kopečný Z, Kautzner J.** Arthroscopic evaluation of ultrasonography and magnetic resonance imaging for diagnosis of rotator cuff tear. *Ortop Traumatol Rehabil* 2008 ; 10 : 111-114.
8. **Galatz LM, Ball CM, Fracs et al.** The outcome and repair integrity of completely arthroscopically repaired large and massive rotator cuff tears. *J Bone Joint Surg Am* 2004 ; 86 : 219-224.
9. **Gazzola S, Bleakney RR.** Current imaging of the rotator cuff. *Sports Med Arthrosc* 2011 ; 19 : 300-309.
10. **Gusmer PB, Potter HG, Donovan WD, O'Brien SJ.** MR imaging of the shoulder after rotator cuff repair. *AJR Am J Roentgenol* 1997 ; 168 : 559-563.
11. **Haviv B, Bronak S, Thein R.** Symptomatic rotator cuff tear of the shoulder. *Harefuah* 2012 ; 151 : 102-106.
12. **Jost B, Pfirrmann CW, Gerber C, Switzerland Z.** Clinical outcome after structural failure of rotator cuff repairs. *J Bone Joint Surg Am* 2000 ; 82 : 304-314.
13. **Katolik LI, Romeo AA, Cole BJ et al.** Normalization of the Constant Score. *J Shoulder Elbow Surg* 2005 ; 14 : 279-285.
14. **Klepps S, Bishop J, Lin J et al.** Prospective evaluation of the effect of rotator cuff integrity on the outcome of open rotator cuff repairs. *Am J Sports Med* 2004 ; 32 : 1716-1722.
15. **Le Corroller T, Cohen M, Aswad R, Pauly V, Champsaur P.** Sonography of the painful shoulder : role of the operator's experience. *Skeletal Radiol* 2008 ; 37 : 979-986.
16. **Levy O, Venkateswaran B, Even T, Ravenscroft M, Copeland S.** Mid-term clinical and sonographic outcome of arthroscopic repair of the rotator cuff. *J Bone Joint Surg Br* 2008 ; 90 : 1341-1347.
17. **Magee TH, Gaenslen ES, Seitz R, Hinson GA, Wetzel LH.** MR imaging of the shoulder after surgery. *AJR Am J Roentgenol.* 1997 ; 168 : 925-928
18. **Masaoka S, Hashizume H, Senda M et al.** Ultrasonographic analysis of shoulder rotator cuff tears. *Acta Med Okayama* 1999 ; 53 : 81-89.
19. **Moosikasuwon JB, Miller TT, Burke BJ.** Rotator cuff tears : clinical, radiographic, and US findings. *Radiographics* 2005 ; 25 : 1591-1607.
20. **Park JY, Lhee SH, Oh KS, Moon SG, Hwang JT.** Clinical and Ultrasonographic Outcomes of Arthroscopic Suture Bridge Repair for Massive Rotator Cuff Tear. *Arthroscopy* 2013 ; 29 : 280-289.

21. **Petranova T, Vlad V, Porta F et al.** US of the shoulder. *Med Ultrason* 2012 ; 14 : 133-140.
22. **Prickett WD, Teefey SA, Galatz LM et al.** The accuracy of ultrasound imaging of the rotator cuff in shoulders that are painful postoperatively. *J Bone Joint Surg Am* 2003 ; 85 : 1084-1089.
23. **Sugaya H, Maeda K, Matsuki K, Moriishi J.** Functional and structural outcome after arthroscopic full-thickness rotator cuff repair : single-row versus dual-row fixation. *Arthroscopy* 2005 ; 21 : 1307-1316.
24. **Sugaya H, Maeda K, Matsuki K, Moriishi J.** Repair integrity and functional outcome after arthroscopic double-row rotator cuff repair : a prospective outcome study. *J Bone Joint Surg Am* 2007 ; 89 : 953-960.
25. **Tudisco C, Bisicchia S, Savarese E et al.** Single-row vs double-row arthroscopic rotator cuff repair : clinical and 3 Tesla MR arthrography results. *BMC Musculoskeletal Disorders* 2013 ; 14 : 1-10.
26. **Walton JR, Murell GA.** A two-year clinical outcomes study of 400 patients, comparing open surgery and arthroscopy for rotator cuff repair. *Bone joint Res* 2012 ; 1 : 210-217.
27. **Yoo JC, Ahn JH, Koh KH, Lim KS.** The outcome and repair Integrity of completely arthroscopically repaired large and massive rotator cuff tears. *Arthroscopy* 2009 ; 25 : 1093-100.
28. **Zhang AL, Montgomery SR, Ngo SS et al.** Analysis of Rotator Cuff Repair Trends in a large Private Insurance Population. *Arthroscopy* 2013 ; 29 : 623-629.