



The long term fate of the fibula when used as an intraosseous graft

Onkar N. NAGI, Mandeep S. DHILLON, Sameer AGGARWAL

From the Post Graduate Institute of Medical Education and Research, Chandigarh, India

The long term fate of the fibula in an intra-osseous site is still a matter of debate. Since the procedure of free fibular grafting for neglected femoral neck fractures was routinely done at our institute, we were able to observe the serial changes in 37 cases with an average 8.9 years follow-up. Graft incorporation was not consistent in the 4 to 10-year postoperative period, but in cases with more than 10 years follow-up, a major portion of the graft got incorporated into the host bone. A classification system for the incorporated grafts is suggested. The presence of avascular necrosis seems to initially hinder graft incorporation, but if the bone revascularises, graft incorporation proceeds at a comparable rate. This study shows that cortical bone gets well incorporated into host cancellous bone and helps to reconstitute the neck in cases of femoral neck nonunions.

INTRODUCTION

Free fibular grafts have been routinely used to fill up gaps created by bone tumour excision, after resection of infected bone, and in nonunions. Free fibular grafts are now used less frequently, as vascularised fibular grafts have gained in popularity, and the expertise is available in most advanced centers.

Free fibular graft, however, is still popular in the underdeveloped countries ; many reports in the literature highlight the good results obtained after extraosseous placement of the bone, especially after tumour excision (5), or in infections. The fibu-

la has been shown to hypertrophy in the long term after union to host bone. We have used free fibular grafts for the management of delayed or neglected cases of fractures of the femoral neck for the last 20 years (1, 2, 3) ; the indications for surgery, case selection and operative procedure have been described in other publications (1, 2). A large percentage of these cases united, and were subsequently reviewed after varying periods of time. The radiological picture of the fibula, however, was somewhat inconsistent, and did not correlate exactly with the time elapsed after surgery or any other factors. Keeping this in mind, we tried to analyse the radiological fate of these free grafts, when inserted at an intraosseous site.

MATERIALS AND METHODS

Thirty-seven cases with follow-up more than 4 years were reviewed in the period May-Sept 2002. These cases had no major problems, and form the basis of this

■ Onkar N. Nagi, MS, MSc (Oxon), FAMS, Professor and Chairman.

■ Mandeep S. Dhillon, MS, MNAMS, Additional Professor.

■ Sameer Aggarwal, MS, Assistant Professor.

Department of Orthopaedics, Post Graduate Institute of Medical Education and Research, Chandigarh, India.

Correspondence : Onkar N. Nagi, 1027, Sector 24, Chandigarh, 160024, India. E mail : mandyrima@hotmail.com
mandeep@drdhillon.net.

© 2004, Acta Orthopædica Belgica.

Table I

Grade of resorption	Radiological appearance	N° of cases
Grade I	Complete fibular graft incorporation ; scar of bone may be visible on radiographs	8 cases
Grade II	More than 2/3 rd graft incorporation, 1/3 rd visible on radiographs	10 cases
Grade III	Less than 1/2 of the graft incorporated ; more than 1/2 to 2/3 rd visible on radiographs Trabeculae cross graft	14 cases
Grade IV	Almost complete fibula visible on radiographs ; Trabeculae cross graft	5 cases

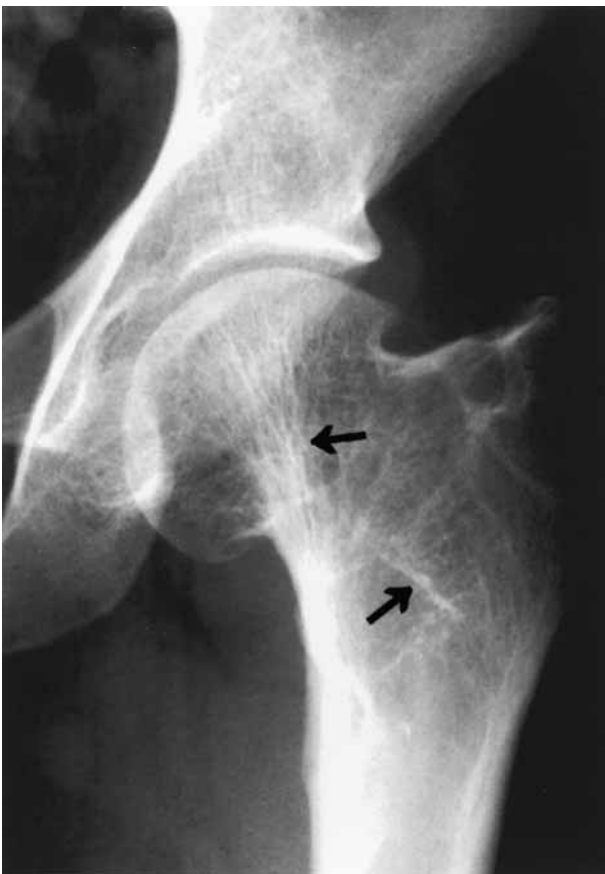

Fig. 1a. — Radiograph of hip (AP view) showing complete incorporation of the fibula, 17 years after fibular grafting. Note the revascularised femoral head and the (healed) subtrochanteric fracture which occurred 12 years post surgery.

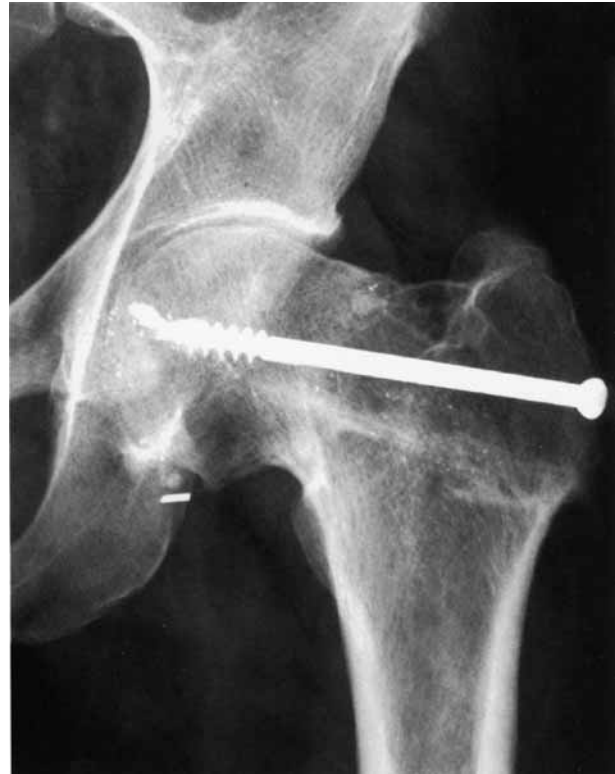

Fig. 1b. — Radiograph of hip (AP view) showing two-third incorporation of the fibular graft, and passage of host trabeculae across the cortical bone, 7 years post surgery.

radiological study. AP and lateral radiographs were assessed for the fate of the fibula inside the femoral neck ; a classification was devised by the authors to grade the extent of residual graft inside the cancellous bone of the femoral neck (table I), in an attempt to assess the rates of radiological incorporation. We also attempted to correlate the graft incorporation with time elapsed since surgery.

Observations and Results

In the 34 male and 3 female patients, the average age at fracture was 35.2 years (range, 17-49), average age at follow-up was 46.1 years. All had fracture union in good position ; 4 cases had healed avascular necrosis of the femoral head. Follow-up ranged from 4.1 years to 19.2 years (average, 8.9 years). Eight cases (Type I) showed complete incorporation (fig 1a) of the graft into host bone (minimal scar of graft observed) ; type II incorporation (less than one-third visible) was noted in 10 cases (fig 1b). Fourteen cases where half or more

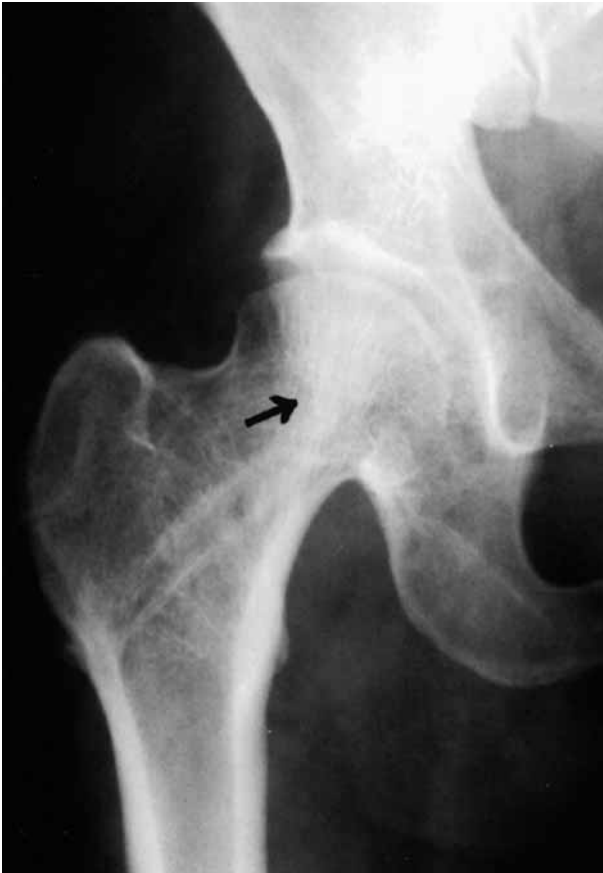

Fig. 1c. — Radiograph of hip (AP view) showing less than $\frac{1}{2}$ incorporation of the fibular graft, but trabeculae are seen to cross the fibular graft as well as the fracture site.

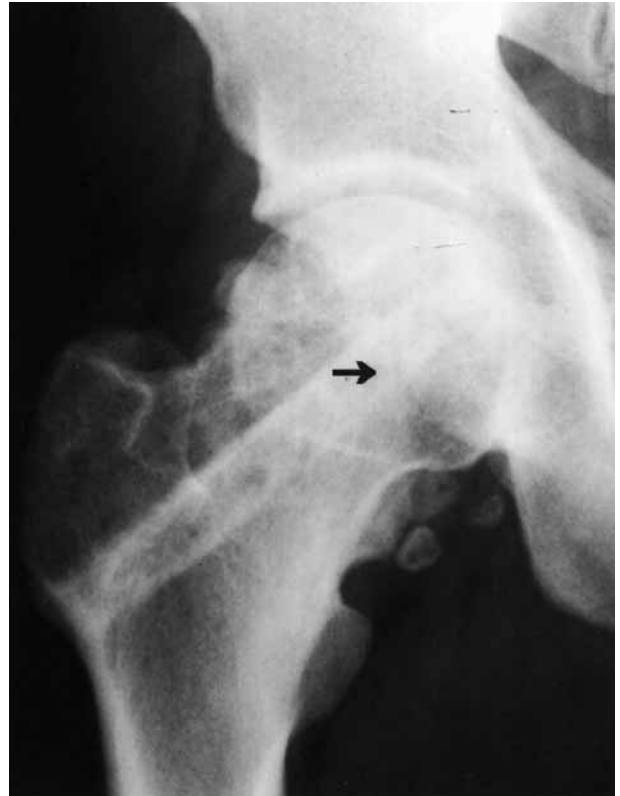

Fig. 1d. — Radiograph of hip (AP view) showing almost complete retention of the fibular graft outline 5 years post surgery, with good union and trabeculae crossing the fibular graft (arrow).

than half of the fibular graft remained visible were labeled as type III incorporation (fig 1c), and in 5 others, more than two-thirds of the original fibular graft was still recognisable (type IV incorporation) (fig 1d).

Upon correlating the times from surgery to the graft incorporation, we found that increased time post surgery and no evidence of avascular necrosis at initial presentation, were factors that increased the percentage of the graft that was readily incorporated. The age at surgery and the duration between injury and surgery, or history of previous surgery, had no significant influence on graft incorporation. In certain radiographs, a trabecular pattern was observed across the fibular graft. Whatever the degree of intraosseous graft incorporation, we noted in all radiographs evaluated a distinct fusion pattern of the graft with host bone at the base of the greater trochanter.

DISCUSSION

Free fibular grafting, a fairly easy procedure, is at times the only option available in the underdeveloped countries. In an intraosseous setting it is most commonly employed for problems relating to femoral neck fractures and to fill up cavities after tumour excision. The long term fate of the graft in this unique situation has not been documented radiologically in detail, although there are always anecdotal references to the fact that the graft is “incorporated adequately” with sufficient follow-up. Most of these studies were done when the fibula was used in femoral head avascular necrosis, where the host settings were not totally congenial.

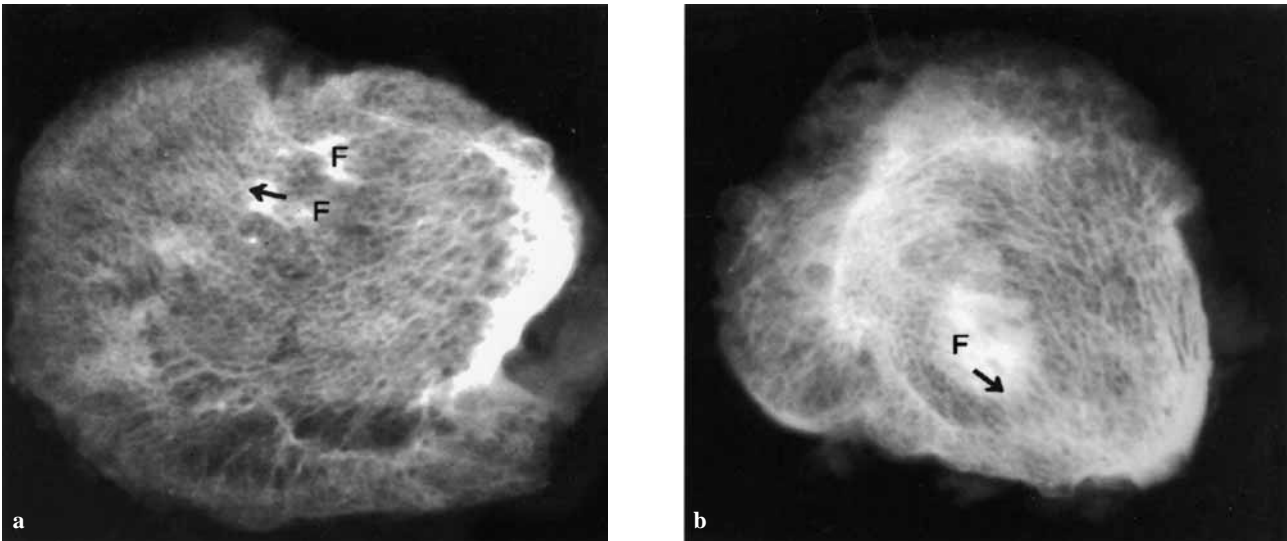


Fig. 2a and b. — CT scan of bone specimen (head and neck area) removed at THA showing residual fibular graft in host cancellous bone ; note bony spicules growing into the graft.

We were able to review only about one-third of our operated cases (48 out of 153, out of which 37 had intact fibula *in situ*) ; the percentage reviewed has little relevance, as the aim was not to see the outcome of the procedure, but to evaluate the long term radiological fate of the graft.

Different rates of graft incorporation were noted ; one common factor in cases with follow-up of 10 years was the graft incorporation into the host bone, with trabeculae being seen to cross the graft. In cases seen earlier than 10 years follow-up, there was no correlation between time from surgery and rate of graft incorporation, and we can offer no explanation for this. Although avascular necrosis of the femoral head is a detrimental factor, the 4 cases where a healed AVN was encountered without significant collapse had somewhat comparable rates of graft incorporation till 10 years follow-up. In two cases (which we had excluded due to primary procedure failure) total hip arthroplasty had been done for AVN-induced collapse and arthritis ; the resected neck specimens were sliced, and these showed significant fibular residual graft ; however CT scans of these specimens showed bony spicules

growing into the graft and some evidence of bony outgrowths from the fibula (fig 2).

A major advantage of free fibular grafts placed at an extrasosseous site to act as bone bridges is the graft hypertrophy reported by some authors. This is not a feature of the intraosseous grafts, where they seem to act as conduits to bone growth, and radiological incorporation of these cortical struts occurs at variable rates initially. They probably become a part of the host bone, and in addition to providing initial stability at the fracture site, also stimulate bone conduction across them.

In conclusion we have noted that cortical grafts become incorporated variably into host bone in young adults with femoral neck fractures, provided a stable reduction can be achieved and maintained. Variable graft incorporation is observed early, but after longer follow-up most of the grafts become part of the host bone. It is true that we cannot prove that radiological integration parallels microscopic integration ; the present radiological classification is just an attempt at documentation of graft incorporation into host bone, and has no significance with respect to the clinical outcome.

REFERENCES

1. **Nagi ON, Gautam VK, Marya SKS.** Treatment of femoral neck fractures with a cancellous screw and a fibular graft. *J Bone Joint Surg* 1986 ; 68-B : 387-391.
2. **Nagi ON, Dhillon MS, Goni V.** Open reduction, internal fixation and fibular autografting for neglected femoral neck fractures in young adults. *J Bone Joint Surg* 1998 ; 80-B ; 798-804.
3. **Nagi ON, Dhillon MS, Gill, SS.** Fibular osteosynthesis for delayed type II and type III femoral neck fractures in children. *J Orthop Trauma* 1992 ; 6 : 306-313.
4. **Nagi ON, Dhillon MS, Sharma S, Gill SS.** Donor site morbidity and regeneration after harvesting of the fibula as free graft. *Contemporary Orthopaedics* 1992 ; 24 : 535-540.
5. **Yadav SS.** Guest lecture. Double fibular grafting. 19th North Zone IOA conference, Chandigarh, 1999.