



Coracoid process transfer for anterior shoulder instability : a pectoralis minor sparing method

Joris BECKERS, Tom VAN ISACKER, Bart BERGHS

From the Department of Orthopaedic Surgery, AZ Sint-Jan & AZ Sint-Lucas Brugge, Belgium

The Latarjet procedure alters scapulothoracic motion by releasing the pectoralis minor insertion to the coracoid process and by changing the vector of the conjoint tendon. The purpose of this study is to evaluate the feasibility of retaining the pectoralis minor insertion and a part of the conjoint tendon on to the remainder of the coracoid, and to evaluate the efficiency of the procedure in avoiding scapular dyskinesia, without concessions to glenohumeral stability.

Since June 2017, a modification to the Latarjet procedure has been used in the treatment of posttraumatic anterior shoulder instability. The pectoralis minor insertion and a part of the conjoint tendon is retained on its anatomical position, by harvesting only the lateral part of the coracoid. We retrospectively enrolled the first 9 consecutively treated shoulders with a minimum of 6 months follow up and recorded scapulothoracic position and scapulothoracic motion, patient satisfaction, Oxford score, and Short Form (SF)-36. All patients underwent a radiographic review at final follow up.

No scapular dyskinesia was observed at final follow-up. Radiographies consistently showed a bony spur at the original osteotomy site, suggesting a functional attachment of the pectoralis minor tendon to the scapula.

Harvesting only the lateral part of the coracoid is technically feasible, efficient in treating anterior shoulder instability and avoids scapular dyskinesia.

Level of evidence : Level IV, Retrospective Cohort study, Treatment study.

Keywords : Pectoralis minor sparing ; Latarjet ; modified Latarjet ; shoulder instability ; scapular dyskinesia ; coracoid process transfer.

INTRODUCTION

Anterior glenohumeral instability is a common condition with an overall incidence rate of 1,7% (8). Recurrent anterior instability can be surgically treated with soft tissue procedures or bony procedures depending on the anatomic lesion and the requirements of the patient. In case of bone loss of the glenoid or in high demand patients, a bony reconstruction procedure is advised (11). The Latarjet procedure has proven to be a successful treatment for anterior instability with bone loss in low and high demand patients. In this technique, the coracoid process is transferred with the attachment of the conjoint tendon through the middle of the subscapularis muscle to the antero-inferior glenoid

■ Joris Jan J Beckers^{1,2}

■ Tom Van Isacker²,

■ Bart Berghs³

¹UZ Leuven, Belgium.

²AZ Sint-Lucas Brugge, Belgium.

³AZ Sint-Jan Brugge, Belgium.

Correspondence : Joris Jan J. Beckers, UZ Leuven, Herestraat 49, 3000 Leuven, Belgium.

Email : beckers.joris@hotmail.com

© 2020, Acta Orthopædica Belgica.

neck. Thereby, the coracoid covers the bony deficiency of the glenoid, while the conjoint tendon tensions the inferior part of the subscapularis, functioning as a dynamic sling (4).

Despite its efficiency as a stabilizing procedure, there is a concern about the anatomical changes after the Latarjet procedure : the pectoralis minor tendon is released and the vector of the conjoint tendon is changed. Several authors have investigated and described alterations in scapular position and motion after the Latarjet procedure. Although not statistically significant, Cerciello et Al. described scapular protraction 45 days after the Latarjet procedure, trending towards scapular retraction after 6 months in their computed tomography analysis (3). Recently, Carbone et Al. observed scapular dyskinesia in 5 out of 20 patients who underwent the Latarjet procedure. No dyskinesia was observed in a control group treated by a modified iliac crest bone graft transfer procedure (J-bone graft). They hypothesized that the Latarjet procedure could alter scapular position and motion due to the detachment of the pectoralis minor tendon and a change in vector of the conjoint tendons (2). Since scapular dyskinesia is most probably a potential impairment to optimal shoulder function, we modified the Latarjet procedure in order to spare the pectoralis minor insertion and the medial part of the conjoint tendon to its original attachment. We report our short-term outcome regarding the feasibility and safety of the procedure, patient satisfaction, postoperative scapular movement and recurrence of instability.

MATERIALS AND METHODS

A retrospective cohort study was performed to obtain short-term postoperative results of nine patients who have been treated by a pectoralis minor sparing coracoid transfer method. All surgical procedures were performed by the same surgeon.

Recurrent anterior shoulder instability was the preoperative diagnosis for every patient. Three out of nine patients underwent previous arthroscopic soft tissue reconstruction surgery but experienced recurrent anterior shoulder instability necessitating a revision intervention.

Our post-operative protocol includes outpatient clinic visits at two weeks, six weeks, three months and six months postoperatively. At six months a final standard shoulder radiograph including a Bernageau view was performed to investigate the degree of consolidation of the bone block. Every patient in follow-up completed the validated Dutch Oxford shoulder score and SF-36 questionnaires at 6 months postoperatively. Clinical examination of the shoulder was performed at every consultation moment, scapulothoracic movement was precisely registered by the two lead investigators separately using the scapular dyskinesia yes/no test described by Uhl et al (10).

Early postoperative complications, recurrent instability, patient satisfaction and clinical investigation were actively registered during every postoperative visit.

The Ethical Review Board of the Sint-Jan Hospital in Bruges, Belgium found no objectives against this original retrospective study (Approval number 2213). All investigations were conducted in conformity with the ethical principles of research.

General anesthesia is induced after an interscalene nerve block. The patient is installed in the beach-chair position ; the affected arm is draped free to allow intraoperative manipulation of the arm for adequate exposure.

A standard deltopectoral approach is used to expose the coracoid process. The clavipectoral fascia is opened along the lateral border of the conjoint tendon and the coracoacromial ligament is transected at the coracoid using an electrocautery device. A sharp straight osteotome is used to perform an osteotomy of the coracoid 2 to 3 mm lateral from the medial border of the coracoid, thereby leaving the pectoralis minor insertion intact. A sharp curved osteotome is used to complete the osteotomy, just anterior to the coracoclavicular ligaments, into the elbow of the coracoid, hereby harvesting the horizontal arm of the coracoid. The conjoint tendon is split carefully in a Y-shape until the musculocutaneous nerve enters the muscle (Figure 1).

The arthrotomy is performed through a subscapularis split, followed by a capsulotomy, extending far medially onto the glenoid neck. A Fukuda

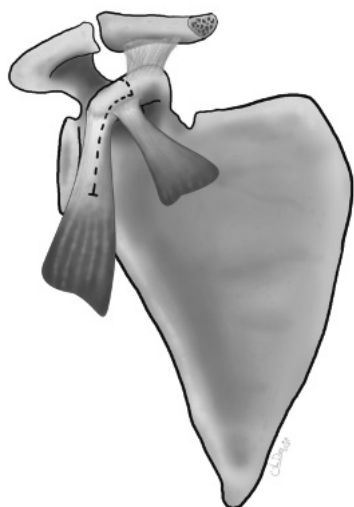


Figure 1.— The pectoralis minor sparing osteotomy of the coracoid process is followed by a Y-shaped split of the conjoint tendon.

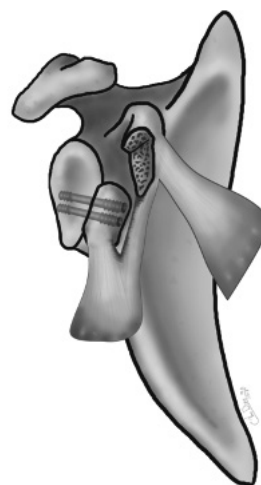


Figure 2.— The medial side of the bone block is positioned against the debrided anterior rim of the glenoid.

retractor is placed intraarticular to allow exposure of the glenoid articular surface. The anteroinferior glenoid is prepared for capsular closure by placing 2 Juggernaut 1,4mm anchors (Zimmer Biomet, Indiana, USA) on the edge of the articular surface, 1 at half past 3 and 1 at half past 5 o'clock. The sutures are passed through the capsule without tying.

The graft is used in the congruent arc modification of Burkart and de Beer (1,6). With a deperiosteum, the deficient anteroinferior glenoid neck is gently abraded and the medial surface of the coracoid is positioned onto the anteroinferior glenoid, about 1 mm medial to the articular surface. Two 2.0 mm K-wires are used in a parallel configuration for preliminary fixation of the graft. The K-wires are measured. The proximal K-wire is removed and manually replaced by the guide-wire for a HCS 3.0 screw (DePuy Synthes, Massachusetts, USA). The screw is inserted over the guide wire and compression is performed with the appropriate screwdriver. The same sequence is followed for the distal screw. Screw-length varies between 32 and 38mm (Figure 2). The Fukuda retractor is removed and the sutures on the Juggernaut anchors are closed, placing the capsulolabral complex onto the graft. The capsule is closed without shift with Ethibond 0 (Ethicon, New Jersey, USA) sutures and

the subscapularis split with Vicryl 1 (Ethicon, New Jersey, USA) absorbable sutures.

Postoperatively, an adduction sling is used at night for 6 weeks. Immediate mobilization is allowed without forced external rotation for 3 months. Physiotherapy is started at 6 weeks if external rotation did not recover within 30° of the unaffected side.

RESULTS

Nine consecutively treated patients with a mean follow-up of 10 months (range 6-15 months) were included. The impact of the surgery was measured at six months follow-up through the Oxford Shoulder Score and SF-36 questionnaires. Mean Oxford Shoulder Score was 46 (41-48). A score between 40 and 48 indicates a satisfactory joint function (5). SF-36 subscale scores are available in table I. Physical Component Summary (PCS) score was 57,42 and Mental Component Summary (MCS) score was 56,82 (9).

None of the 9 patients have experienced recurrent anterior shoulder instability and no postoperative complications have been registered. One malunion due to partial displacement of the graft has been recognized on the six-month follow-up radiograph.

Table I. — Mean SF-36 subscale scores

SF-36 (n=9)	(%)	St.Dev.
Physical functioning	94	6,4
Role limitations due to physical health	97	8,3
Role limitations due to emotional problems	100	0
Energy/fatigue	81	10,4
Emotional well-being	86	9,4
Social functioning	100	0
Pain	100	0
General health	84	12,6
Health change	78	19,5

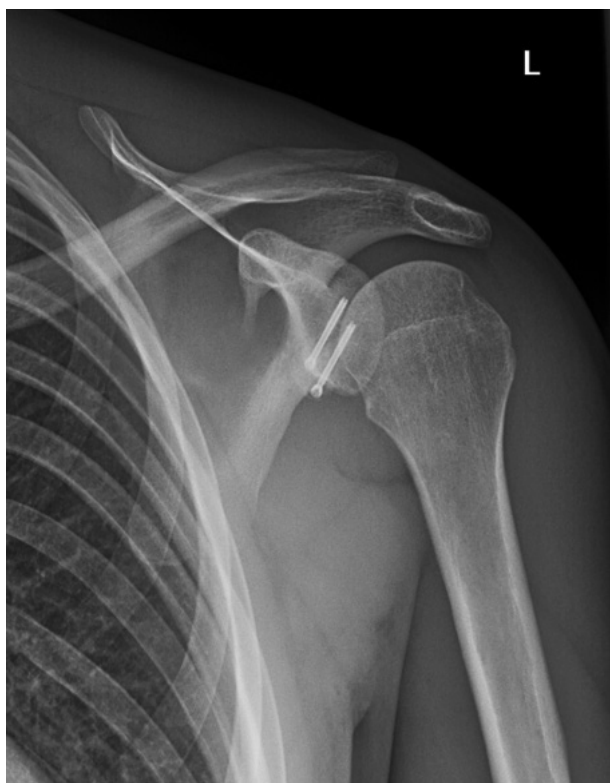

Figure 3. — An obvious bony spur at the base of the former coracoid process emphasizes pectoralis minor function.

This malunion however did not seem to cause any clinical impairment.

At final follow-up a bony spur can be noticed at the donor site of the transferred coracoid process on control radiographic images (Figure 3).

At a minimum of six months of follow-up, no scapular dyskinesis has been registered by the investigators using the scapular dyskinesis yes/no test.

DISCUSSION

The pectoralis minor sparing Latarjet procedure has been conceived as a theoretically valuable improvement to the Latarjet procedure in order to prevent postoperative scapular dyskinesis. In our early series, symmetrical scapular movement is found in all patients at final clinical examination. Pectoralis minor function is further assumed because of the presence of a bony traction spur on the coracoid on final X-rays (Figure 3).

A potential drawback of decreasing the dimensions of the coracoid is its biomechanical efficiency. Retaining 2 to 3 mm of the medial side of the coracoid diminishes the average width of the coracoid to 10 to 12 mm, which is still wider than the average thickness of 9,3 to 10,7 mm (12). There is as such no concession to replacing the bony defect when compared to the classic Latarjet procedure.

Decreasing the dimensions of the transferred coracoid and retaining a part of the conjoint tendon on its original anatomic position did not affect the clinical efficiency of the procedure as a treatment for instability : there was no recurrent instability so far, the Oxford Shoulder Scores were high with a mean score of 46 and patient satisfaction was excellent. Although 1 shoulder revealed a partial displacement

of the graft with consequently a malunion, there were no clinical consequences.

Besides the influence on scapular movement, the pectoralis minor sparing adjustment of the Latarjet procedure could be beneficial in some other regards ;

- Since the conjoint tendon is split until the level of entrance of the musculocutaneous nerve (MCN) before transferring the coracoid, the traction on the MCN is thought to be equal before and after the conjoint tendon split, reducing the chance of postoperative MCN palsy (7).
- A significant bony spur at the donor site of the coracoid process can be observed postoperatively, emphasizing a functioning pectoralis minor muscle. This bony spur mimics the presence of a coracoid process and can therefore be used as an anatomical landmark in revision surgery if necessary.

The limited amount of patients included in this paper is most definitely the greatest limitation of this paper. The advantageous results however and the absence of clinical complications at this moment was determining in our decision to present the early results for this promising procedure. In total 42 patients have been treated so far, results of a bigger, prospectively followed cohort will be published in process of time.

CONCLUSION

The pectoralis minor sparing adjustment to the classical congruent-arc Latarjet procedure promises several theoretical advantages. In the first cohort of nine consecutively treated patients, no complications urging revision surgery have been registered. Overall patient satisfaction was excellent and postoperative scapular movement was symmetrical, possibly emphasizing the function of the pectoralis minor in the overall movement of the scapula.

Further investigation of a more extensive cohort with longer follow-up will reveal whether or not

this adjustment to the congruent-arc modified Latarjet procedure is as valuable clinically as it is theoretically promising in this stage.

REFERENCES

1. **Burkhart SS, De Beer JF, Barth JRH, Criswell T, Roberts C, Richards DP.** Results of Modified Latarjet Reconstruction in Patients With Anteroinferior Instability and Significant Bone Loss. *Arthroscopy*. 2007 ; 23 : 1033-41.
2. **Carbone S, Moroder P, Runer A, Resch H, Gumina S, Hertel R.** Scapular dyskinesia after Latarjet procedure. *J Shoulder Elb Surg* 2016 ; 25 : 422-7.
3. **Cerciello S, Edwards TB, Cerciello G, Walch G.** Scapular position after the open Latarjet procedure : results of a computed tomography scan study. *J Shoulder Elb Surg*. 2015 ; 24 : 199-202.
4. **Cowling PD, Akhtar MA, Liow RYL.** What is a Bristow-Latarjet procedure? A review of the described operative techniques and outcomes. *Bone Joint J* 2016 ; 98-B : 1208-14.
5. **Dawson J, Fitzpatrick R, Carr A.** Questionnaire on the perceptions of patients about shoulder surgery. *J Bone Joint Surg Br*. 1993 ; 78 : 593-600.
6. **De Beer JF, Roberts C.** Glenoid Bone Defects - Open Latarjet with Congruent Arc Modification. *Orthop Clin North Am*. 2010 ; 41 : 407-15.
7. **Gupta A, Delaney R, Petkin K, Lafosse L.** Complications of the Latarjet procedure. *Curr Rev Musculoskelet Med*. 2015 ; 8 : 59-66.
8. **Hovelius L, Augustini BG, Fredin H, Johansson O, Norlin R, Thorling J.** Primary Anterior Dislocation of the Shoulder in Young Patients. *J Bone Joint Surg Am*. 1996 ; 78(11) : 1677-84.
9. **Laucis NC, Hays RD, Bhattacharyya T.** Scoring the SF-36 in Orthopaedics : A Brief Guide. *J Bone Joint Surg Am*. 2015 ; 7 ; 97 : 1628-34.
10. **Levine WN, Sonnenfeld JJ, Shiu B.** Shoulder Instability Common Problems and Solutions. *Clin Sports Med*. 2018 ; 37 : 161-77.
11. **Uhl LT, Kibler WB, Gecewich B, Tripp BL.** Evaluation of Clinical Assessment Methods for Scapular Dyskinesia. *Arthroscopy*. 2009 ; 25 : 1240-8.
12. **Young AA, Baba M, Neyton L, Godeneche A, Walch G.** Coracoid graft dimensions after harvesting for the open Latarjet procedure. *J Shoulder Elb Surg*. 2013 ; 22 : 485-8.