



## Prevention of post-traumatic elbow stiffness using Botulinum toxin

Henrik C. BÄCKER, Chia H. WU, Robert J. STRAUCH, Carsten PERKA, Christina FREIBOTT, Melvin P. ROSENWASSER

*From the Columbia University Medical Center, Orthopaedic Surgery, New York City, USA*

Botulinum toxin (Botox) has been used in orthopaedic surgery for facilitating rehab after tendon repairs, and for the treatment of lateral epicondylitis. To our knowledge, role of Botox in postoperative management of elbow fracture has not been studied. Our aim was to investigate the efficacy of Botulinum Toxin (Botox) in preventing post-traumatic elbow-stiffness.

We performed a retrospective study dated between 2007 and 2017. This included all patients with intercondylar distal humerus fractures, and Monteggia fractures treated by a single surgeon. A matched control group based on fracture pattern and age was created for comparison. For functional outcome, we assessed the arc-of-motion (AOM) after six weeks, three months, six months, and final follow up for evaluation.

Of the 30 patients that met the inclusion criteria, 15 patients (50%) received Botox injections. Intercondylar distal humerus fractures were identified in 11 cases (n=11/15 ; 73.3%) and Monteggia fractures in 4 cases (n=4/15 ; 26.7%). The mean age was 52.2 years and the dominant side was affected in 7 patients (47%). Significant differences in elbow extension for proximal ulna and radius fractures after six-weeks (extension  $26 \pm 4.04$  degree vs.  $45.63 \pm 7.45$  degree ;  $p < 0.05$ ) were observed.

Elbow extension was improved significantly at 6 weeks postop for intercondylar fractures. No complications related to Botulinum toxin were identified. Botox appears to be safe and effective in improving elbow motion in some cases.

**Keywords :** Elbow ; trauma ; stiffness ; Botulinum toxin ; Monteggia fracture ; fracture

Level of Evidence : Therapeutic III, retrospective study.

## INTRODUCTION

Botulinum toxin type A (Botox®) is an exotoxin produced by *Clostridium botulinum*. It is reported to be safe and causes reversible localized muscle paralysis (1). There are a variety of different indications in aesthetic, orthopaedic and trauma surgery. Possible indications include the treatment of lateral epicondylitis, tendon repairs in the hand, and contractures after total knee arthroplasty (1,2,3).

Of all the upper extremity injuries, fractures about the elbow are concerning for developing elbow stiffness. Elbow functional range of motion is generally considered to be between 30 to 130 degrees of flexion and 50 degrees of pronation as

- 
- Henrik Constantin Bäcker<sup>1</sup>
  - Chia H Wu<sup>2</sup>
  - Robert J. Strauch<sup>1</sup>
  - Carsten Perka<sup>3</sup>
  - Christina Freibott<sup>1</sup>
  - Melvin P. Rosenwasser<sup>1</sup>

<sup>1</sup>Columbia University Medical Center, Orthopaedic Surgery, New York City, USA.

<sup>2</sup>Baylor College of Medicine, Department of Orthopedic Surgery.

<sup>3</sup>University Hospital Berlin, Charité, 10117 Berlin, Germany.

Correspondence : Henrik Constantin Bäcker, Columbia University Medical Center, Orthopaedic Surgery, New York City, USA.

Email : henrik.baecker@sports-med.org

© 2020, Acta Orthopaedica Belgica.

---

well as supination (4). Reasons for elbow stiffness include intrinsic causes such as intra-articular incongruity as well as extrinsic ones like soft tissue contracture or heterotopic ossification (5,6). This may lead to significant disability and requires physical therapy, manipulation under anesthesia (5,7,8) or even revision surgery like capsular release with removal of ossification (9,10,11,12,13). To prevent post-traumatic elbow stiffness, optimal reduction and fixation with as little soft tissue injury as possible is recommended. This is challenging even for specialized surgeons.

This study aims to investigate the effects of Botulinum toxin in the treatment of post-traumatic elbow stiffness compared to a matched control group.

## MATERIALS AND METHODS

We performed a retrospective review dating between 2007 and 2017 looking at functional outcomes including arc of motion. Study had been approved by the Institutional Review Board (IRB).

One fellowship trained orthopaedic surgeon reviewed the charts of all patients who underwent surgery for intercondylar distal humerus fractures as well as Monteggia fractures/ dislocation. Patients have to be older than 18 years old to be included. Patients who are excluded include those who are minors, those who were treated conservatively, those who had burns around the elbow, as well as patients with neurological diseases requiring the use of medications that can interfere with neuromuscular function. The arc of motion – flexion/extension and pronation/supination are documented after six weeks, three months, six months postop and compared against the control group that did not receive the Botox injection. Additionally, all x-rays were reviewed again for classification of fracture types and assessment of bony healing. A matched control group was selected. Those in the Botox group treated by the senior author were matched with patients from a different fellowship trained orthopaedic surgeon.

Botox was injected after completion of surgical fixation and removal of the sterile tourniquet. The anterior upper arm was re-prepped. The muscle

belly of the biceps brachii was palpated and injected midline at approximately 13 cm distal to the coracoid process. One vial of 100 units of Botulinum toxin A (human serum albumin and sodium chloride in a sterile, vacuum-dried form without preservatives) was injected with a 23 gauge needle in biceps brachii. Second vial was injected similarly 17cm distal to the coracoid process into the brachialis muscle. Elbow was then stretched passively. Control patients did not receive any injection.

For rehabilitation, the same postoperative protocol was initiated for all patients. A standardized pain control protocol was implemented. A posterior splint was applied after surgery with the elbow in 30° of flexion if there is complex bony-ligamentous injuries. Shoulder sling is applied for isolated bony injury without ligamentous instability. Hinged orthotic brace was also applied to those that underwent ligamentous repair or showed evidence of instability intraoperatively to protect the soft tissue as it healed.

Physical therapy was initiated within a week after surgery. Patients were asked to perform active range of motion (AROM) of the elbow several times per day. Appointments were scheduled two to three times per week. Light resistive exercises were initiated for the forearm, wrist and hand after two weeks. After three and a half weeks, patients were asked to begin strengthening exercises including elbow extension and flexion. Gradually, the resistive exercises progress to heavier weights. Six weeks after surgery, patients continued with strengthening exercises until they obtained their maximum rehabilitation potential. This process typically takes at least six months following the procedure.

To compare the arc of motion, independent two-sided t-test was used to compare differences between groups. Statistical significance was set at the threshold of  $p < 0.05$ . Furthermore, a matched control group of patients was selected based on similar fracture types, and age.

## RESULTS

Between 2007 and 2017, 30 patients met the inclusion criteria. Fifteen patients are in the botulinum toxin type A group and 15 patients are

Table 1. — Demographic of patients

	<b>Botox</b>	<b>Control</b>
Patients	15	15
Males	8 (53.3%)	6 (40.0%)
Dominant Side	7 (46.7%)	10 (66.7%)
Mean Age	52.2	52.6
<b>Injury Descriptions</b>		
<b>Botox (15 total)</b>		<b>Control (15 total)</b>
Intercondylar distal humerus (11)		Intercondylar distal humerus (11) Open (2)
Monteggia fracture/dislocation (4)		Monteggia fracture/dislocation (4)

Table 2. — Arc of Motion and significances

Monteggia fracture Variable	6 weeks			3 months			Last follow up		
	Botox	Control	<i>p</i>	Botox	Control	<i>p</i>	Botox	Control	<i>p</i>
Flexion	100 ± 2.0	108 ± 8.3	0.41	125 ± 4.6	116 ± 11.4	0.47	131 ± 4.3	120 ± 5.8	0.33
Extension	26 ± 6.3	38 ± 7.5	0.44	24 ± 7.5	20 ± 7.4	0.81	23 ± 6.3	21 ± 7.7	0.89
Arc of Motion	74 ± 5.5	70 ± 15.4	0.86	101 ± 11.0	96 ± 15.9	0.84	109 ± 6.6	99 ± 13.0	0.60
<b>Intercondylar fracture</b>									
Flexion	104 ± 7.7	103 ± 7.3	0.92	117 ± 4.8	121 ± 7.9	0.62	129 ± 2.8	123 ± 8.2	0.42
Extension	<b>26 ± 7.5</b>	<b>46 ± 4.0</b>	<b>0.02</b>	19 ± 6.3	21 ± 6.0	0.83	17 ± 4.0	16 ± 5.8	0.86
Arc of motion	58 ± 10.2	51 ± 18.0	0.77	99 ± 12.6	98 ± 9.6	0.93	112 ± 13.0	107 ± 5.8	0.67

in the matched control group. Patients received 100 units of Botox in brachialis and biceps brachii muscle bellies each (200 units total). The control group did not receive any. For better comparison, we separate the patients into two groups by fractures by type. Monteggia fractures are in one group. The other group includes Intercondylar distal humerus fractures. There were 17 females and 13 males, with a mean age of 52.2 years old (range 18-87) in the Botox group. The control group was on average 52.6 years old (range 28-72). The dominant arm was involved in 46.7% in the Botox patients and 66.7% in the control patients. (Table 1)

Range of motion for control patients were similarly measured at six weeks, three months, with the final follow-up at a mean of 1.97 years postop for the Monteggia fracture group and 1.3 years postop for the intercondylar fracture group. After six weeks, extension in both groups was better. In the Intercondylar fracture Botox group, the extension was 26 ± 7 degree compared to the control group at 46 ± 4 degree (*p* < 0.05). For the Monteggia fracture Botox group, extension revealed 26 ± 6 degrees as compared to 37.5 ± 8 degrees (*p* = 0.44) in the

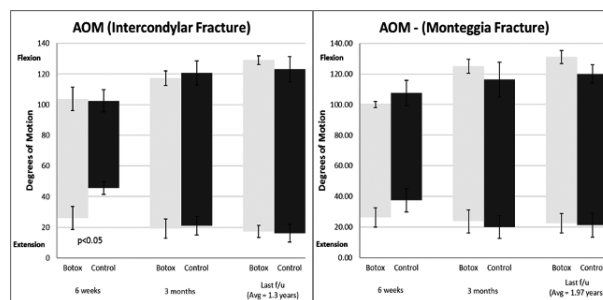


Figure 1. — Arc of motion in A) Monteggia and B) Intercondylar fracture.

control group. In all other follow-up comparisons at different time points, no significant differences were identified. There was a positive trend at 3 months postop in improved flexion for the Monteggia group as compared to control (125 ± 5 versus 116 ± 11; *p* = 0.47) as shown in table 2 and figure 1.

### DISCUSSION

Thirty percent of all upper extremity fractures consist of traumatic elbow injuries. Severe, complex

elbow injuries represent a clinical challenge for its association with stiffness. Stiffness can cause severe disability and limitations in daily activities. Currently, stiffness of elbow is initially addressed with intense rehabilitation protocol. In refractory cases, revision surgery such as open capsular release and removal of heterotopic ossification may be needed. This study seeks to evaluate the effectiveness of a postop Botox injection in improving range of motion.

Our study shows improvements in extension at six weeks after surgery ( $p < 0.05$ ) in the Botulinum toxin injection group as compared to the controls (Figure1). Furthermore, improvements in motion that are not statistically significant have been observed, which warrants further investigation. No increase in complication rates have been identified in our study with equivalent rates of bony healing.

Once full functional range of motion is achieved, no further physical therapy will be performed – typically after 3 months. This is typically earlier in the Botox group as compared to the control group. Earlier return to activity postop is also observed in the Botox group. However, these time points are determined by the non-blinded surgeon based on postoperative clinical assessment. Additionally, there is potential for further improvement in the Botox group relative to the control if therapy has been instituted beyond achieving functional range of motion. Overall, improvements in motion with therapy not only help minimize scar tissue and heterotopic ossification, but also have the potential to limit cartilage damage and pro-inflammatory molecule formation according to the literature (14,15,16,17).

The effect of botulinum toxin in modifying pain is known, although the exact mechanism is not fully understood (18). Because of this, Botox is used for the treatment of neuropathic pain with good results.<sup>(19)</sup> In elbow fractures, this may also help treat postoperative pain. Relaxation of muscles can theoretically reduce contact pressure to facilitate cartilage healing, although this is not addressed in our study.

There are limitations to this study. For one, we did not investigate the pain modifying effect of Botox and its relationship to the range of motion.

The study only included 15 patients in the Botox group due to the inclusion criteria. Furthermore, all fracture fixations were performed by a single surgeon, which makes the study internally consistent but findings less generalizable.

This study highlights the effects of Botulinum toxin in the prevention of elbow stiffness, without any increase in other complications such as adverse effects on bone healing or infection. Chemo denervation of the elbow flexors appears to be safe and warrants further investigation.

## CONCLUSION

The results of Botulinum toxin application in prevention of elbow stiffness is novel. While a significant increase in elbow extension for intercondylar fracture pattern distal humerus fracture was observed, improvement in motion was not statistically significant at other time points. Of note, no increases in complications were found. Additionally, there is a positive trend toward improved elbow flexion long term. Amount of physical therapy any given patient receives is not specifically studied and can be the basis of future investigation.

## REFERENCES

1. Seyler TM, Smith BP, Marker DR *et al.* Botulinum neurotoxin as a therapeutic modality in orthopaedic surgery : more than twenty years of experience. *J. Bone Joint Surg. Am.* 2008 ; 90 Suppl 4 : 133-45.
2. Placzek R, Drescher W, Deuretzbacher G, Hempfing A, Meiss AL. Treatment of chronic radial epicondylitis with botulinum toxin A. A double-blind, placebo-controlled, randomized multicenter study. *J. Bone Joint Surg. Am.* 2007 ; 89(2) : 255-60.
3. Hayton MJ, Santini AJ, Hughes PJ, Frostick SP, Trail IA, Stanley JK. Botulinum toxin injection in the treatment of tennis elbow. A double-blind, randomized, controlled, pilot study. *J. Bone Joint Surg. Am.* 2005 ; 87(3) : 503-7.
4. Morrey BF, Askew LJ, Chao EY. A biomechanical study of normal functional elbow motion. *J. Bone Joint Surg. Am.* 1981 ; 63(6) : 872-7.
5. Bruno RJ, Lee ML, Strauch RJ, Rosenwasser MP. Posttraumatic elbow stiffness : evaluation and management. *J. Am. Acad. Orthop. Surg.* 2002 ; 10(2) : 106-16.
6. Page C, Backus SI, Lenhoff MW. Electromyographic activity in stiff and normal elbows during elbow flexion and extension. *J. Hand Ther.* 2003 ; 16(1) : 5-11.

7. **Lindhovius AL, Jupiter JB.** The posttraumatic stiff elbow : a review of the literature. *J. Hand Surg. Am.* 2007 ; 32(10) : 1605-23.
8. **Nandi S, Maschke S, Evans PJ, Lawton JN.** The stiff elbow. *Hand (N Y).* 2009 ; 4(4) : 368-79.
9. **Ek ET, Goldwasser M, Bonomo AL.** Functional outcome of complex intercondylar fractures of the distal humerus treated through a triceps-sparing approach. *J. Shoulder Elbow Surg.* 2008 ; 17(3) : 441-6.
10. **Kraus E, Harstall R, Borisch N, Weber D.** [Primary total elbow replacement for complex intra-articular distal humerus fractures]. *Unfallchirurg.* 2009 ; 112(8) : 692-8.
11. **Lindhovius AL, van de Luijngaarden K, Ring D, Jupiter J.** Open elbow contracture release : postoperative management with and without continuous passive motion. *J. Hand Surg. Am.* 2009 ; 34(5) : 858-65.
12. **Ring D, Chin K, Jupiter JB.** Radial nerve palsy associated with high-energy humeral shaft fractures. *J. Hand Surg. Am.* 2004 ; 29(1) : 144-7.
13. **Kim SJ, Shin SJ.** Arthroscopic treatment for limitation of motion of the elbow. *Clin. Orthop. Relat. Res.* 2000 ; (375) : 140-8.
14. **Driscoll C, Chanalaris A, Knights C, Ismail H, Sacitharan PK, Gentry C, et al.** Nociceptive Sensitizers Are Regulated in Damaged Joint Tissues, Including Articular Cartilage, When Osteoarthritic Mice Display Pain Behavior. *Arthritis Rheumatol.* 2016 ; 68(4) : 857-67.
15. **Kroon FPB, van Beest S, Ermurat S, Kortekaas MC, Bloem JL, Reijnierse M, et al.** In thumb base osteoarthritis structural damage is more strongly associated with pain than synovitis. *Osteoarthritis Cartilage.* 2018 ; 26(9) : 1196-202.
16. **Sanchez-Adams J, Leddy HA, McNulty AL, O'Connor CJ, Guilak F.** The mechanobiology of articular cartilage : bearing the burden of osteoarthritis. *Curr. Rheumatol. Rep.* 2014 ; 16(10) : 451.
17. **Nakamura S, Arai Y, Takahashi KA, Terauchi R, Ohashi S, Mazda O, et al.** Hydrostatic pressure induces apoptosis of chondrocytes cultured in alginate beads. *J. Orthop. Res.* 2006 ; 24(4) : 733-9.
18. **Ranoux D, Attal N, Morain F, Bouhassira D.** Botulinum toxin type A induces direct analgesic effects in chronic neuropathic pain. *Ann. Neurol.* 2008 ; 64(3) : 274-83.
19. **Park J, Park HJ.** Botulinum Toxin for the Treatment of Neuropathic Pain. *Toxins (Basel).* 2017 ; 9(9).