

UNUSUAL FINDING AFTER CONTRAST INJECTION OF A SOLITARY BONE CYST. A CASE REPORT

J. C. ABRIL¹, J. A. QUEIRUGA¹, J. CASAS², J. ALBIÑANA¹

Injection of radiopaque contrast into a solitary bone cyst (SBC) prior to methylprednisolone acetate (MPA) injection has been previously reported.

We report an unusual finding during the injection of radiopaque contrast in the treatment of one case of SBC of the femur : a bicameral appearance of the cyst was observed ; no filling of the proximal cavity occurred and immediate perfusion of the femoral vein with contrast was noted.

In cases of SBC such as this one, percutaneous autologous marrow or corticosteroid injection may fail to be effective. Furthermore there exists the potential risk of fat embolus secondary to bone marrow injection. Based on these findings in the case reported, we suggest that contrast injection should be performed prior to bone marrow or corticosteroid injection in order to evaluate both the venous drainage of the cyst and its degree of loculation.

Keywords : unicameral bone cyst ; contrast examination ; bone marrow injection ; corticosteroid injection.

Mots-clés : kyste osseux solitaire ; opacification ; injection de moëlle osseuse ; injection de corticostéroïde.

INTRODUCTION

The following have all been described as etiologic factors of a solitary bone cyst (SBC) : mechanical trauma to the physis, a focus of fibrous tissue, intramedullary hemorrhage, dysplastic tumorlike tissue, local venous obstruction, and bone resorptive factors such as prostaglandins. The most widely accepted hypothesis is local venous obstruction (1). Certain previously described findings support this hypothesis : greater compartmental pressures within the cyst than in the venous circulation, and the presence of a

membrane (often a thick layer of fibrous tissue) lining the cystic cavity.

Methylprednisolone acetate (MPA) is a therapeutic option in the treatment of SBC (4). MPA has cytostatic action at the level of the cell membrane. The success of treatment with MPA depends on the following previously described factors : age, location in relation to the physis and degree of loculation.

On the other hand, recent publications (3, 4) show healing of SBC's following percutaneous intracystic injection of autologous bone marrow. However there are no comments in the literature regarding the potential risk of fat embolus following marrow injection of SBCs with a direct connection to the venous circulation.

We report an unusual finding during the injection of radiopaque contrast in the treatment of one case of SBC. A complete communication was discovered between the cyst and its venous drainage. This finding shows that the cyst cavity is not a closed system, suggesting that there exists the risk of flow of injected material into the vascular system, with the consequent risk of vascular complications.

This implies that high blood pressure does not play a role in the etiology of SBC.

¹ Pediatric Orthopedic Division, Hospital Niño Jesus (Madrid), Spain.

² Harvard Medical School (Boston), U.S.A.

Correspondence and reprints : J. C. Abril, Pediatric Orthopedic Division, Hospital Niño Jesus. C/ Menéndez Pelayo, 65. 28009-Madrid, Spain.

CASE REPORT

A 4-year-old girl was referred to our hospital with an 18-month history of discomfort in the anterior portion of the right thigh. On clinical examination, the patient showed normal and symmetrical range of motion of both hips. Physical examination was noncontributive.

On the plain radiograph a pathological fracture in the right proximal femur was observed, associated with a lytic lesion with a sclerotic border (fig. 1). There was no connection between the lesion and the proximal femoral physis. A radiological diagnosis of unicameral bone cyst was made. Invasive treatment was considered because of the severity of the symptoms and the risk of

a new pathological fracture and subsequent deformity. Under general anesthesia, radiopaque medium was injected through the lateral cortex into the distal part of the lesion. A bicameral appearance of the cyst was observed, and prior to corticosteroid injection (methylprednisolone acetate, 60 mg), a second bolus of dye was injected, this time into the proximal region of the lesion. Unexpectedly, no filling of the proximal cavity was observed because of the immediate retrograde dye perfusion into the femoral vein (fig. 2).

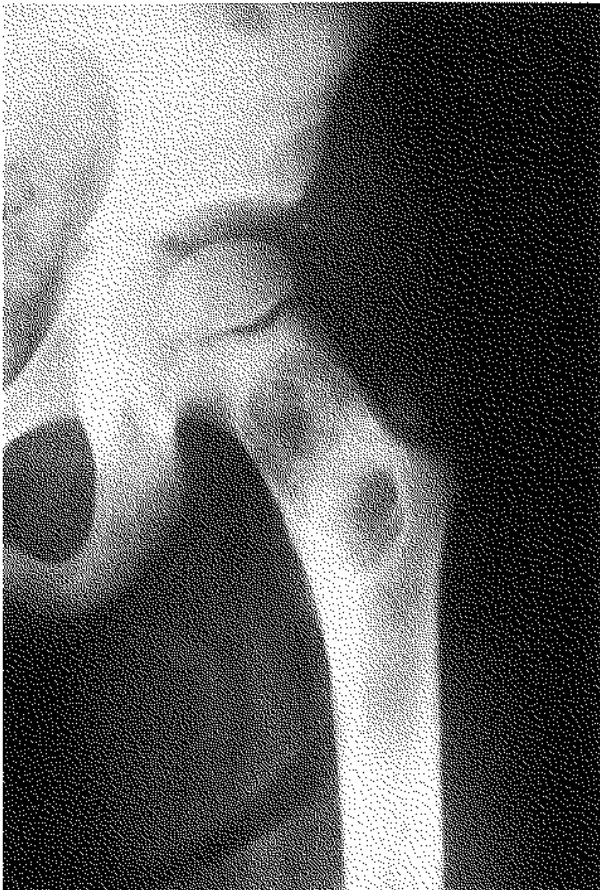


Fig. 1. — Anteroposterior radiograph of the proximal left femur with a lytic metaphyseal lesion. The diagnosis of solitary bone cyst was based on the biopsy specimen.

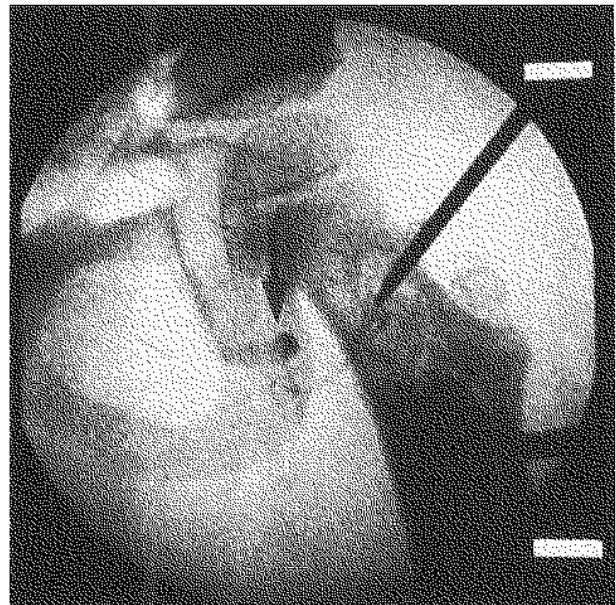


Fig. 2. — A septum divides the lesion into two cavities: the distal cavity is filled with dye; no filling of the proximal cavity is observed. Immediately following contrast injection into the proximal cavity, retrograde flow of dye into the venous circulation is seen (arrow).

Curettage and bone grafting were performed after the contrast examination, instead of corticosteroid infiltration, because of the communication between the cystic cavity and the venous circulation. Three years after the operation the patient was asymptomatic, and radiological follow-up showed graft integration.

DISCUSSION

Various indications for the treatment of unicameral bone cyst have been previously described : uncertain diagnosis, symptomatic lesion, progressive enlargement of the cyst, repeated pathologic fractures, etc. The best approach is still in doubt : curettage and bone grafting, corticosteroid injection (4), drilling of multiple holes, flexible intramedullary nailing (1), packing with high-porosity hydroxyapatite cubes (2), or percutaneous autologous marrow grafting (3, 5).

Cysts with repeated pathological fractures may become multiloculated after the healing process. In such cases, injection of radiopaque medium into the cyst is indicated as this allows for the evaluation of the number of septa within the cyst. Assessment of the number of septa is crucial in such cases of SBC, given that multiloculated cysts are less responsive to treatment than unilocular cysts. In the case presented, surgical treatment was indicated because of a previous history of pathologic fracture of the proximal right femur with subsequent risk of deformity.

At our institution, we biopsy all cystic lesions prior to corticosteroid injection according to our current protocol. In active SBC, the surgical procedure has a low recurrence rate as compared to the conventional treatment. In the case presented, injection of radiopaque medium revealed two separate compartments within the cyst (fig. 2), making equal distribution of MPA throughout the cyst very difficult.

Lokiec *et al.* (3) and Wientroub *et al.* (5) have reported excellent results following percutaneous autologous bone marrow injections. None of their patients underwent dye-injection studies prior to treatment and none developed intraoperative or postoperative complications. However this does not rule out the possibility that some of the marrow injected into the cyst may have rapidly entered the vasculature owing to communication between the cystic cavity and the venous circulation. This may result in poor response or lack of response to treatment as well as in an increased risk of circulatory complications.

Preliminary contrast study has also been used to study how contrast exits the cyst and to

measure the injection pressure as an attempt to elucidate the etiology of SBC. Recently, Gebhart and Blaimont (1) pointed out the existence of venous obstruction and recommended the use of decompressive systems as the treatment of choice.

Our case shows an unusual finding as the dye travels directly into the femoral vein (fig. 2) and no filling of any part of the cyst is observed. This radiological finding is inconclusive with respect to further elucidation of the pathogenesis of SBC. In this case, if the only treatment modality employed were MPA injections, the likelihood of recurrence would be high given the drainage of the cyst discovered during contrast injection. This lack of response to treatment could also occur when employing percutaneous autologous marrow grafting.

We consider preliminary dye injection to be an essential preliminary to autologous marrow grafting and corticosteroid injections or to the drilling of multiple holes in the treatment of SBC, as dye injection is useful in determining the venous drainage and the extent of cyst loculation. Direct communication between the cyst and the venous circulation could contraindicate percutaneous autologous marrow graft injection as a treatment option given the risk of vascular complications. Further investigations are necessary to support this hypothesis.

REFERENCES

1. Gebhart M., Blaimont P. Contribution to the vascular origin of the unicameral bone cyst. *Acta Orthop. Belg.*, 1996, 62, 137-143.
2. Inoue O., Ibaraki K., Shimabokuro H., Shingaki I. Packing with high-porosity hydroxyapatite cubes alone for the treatment of simple bone cyst. *Clin. Orthop.*, 1993, 293, 287-292.
3. Lokiec F., Ezra E., Khermash O., Wientroub S. Simple bone cyst treated by percutaneous autologous marrow grafting. *J. Bone Joint Surg.*, 1996, 78-B, 6, 934-937.
4. Scaglietti C., Marchetti P. G., Bartolozzi P. The effects of methylprednisolone acetate in the treatment of bone cyst. *J. Bone Joint Surg.*, 1979, 61-B, 200-204.
5. Wientroub S., Goodwin D., Khermash O., Salama R. The clinical use of autologous marrow to improve osteogenic potential of bone grafts in pediatric orthopaedics. *J. Pediatr. Orthop.*, 1989, 9, 186-190.

SAMENVATTING

J. C. ABRIL, J. A. QUEIRUGA, J. CASAS, J. ALBIÑANA. Ongewone bevindingen na contrastinjectie in een solitaire beencyste.

De behandeling door injectie van een radio-opaque contrast in een solitaire beencyste met methylprednisolonacetaat werd voorheen gemeld.

Wij rapporteren een ongewone bevinding tijdens de injectie van dit contrastmiddel.

Wij vonden een tweekamerig aspect van de cyste. Er was geen opvulling van de proximale caviteit. Een onmiddellijke perfusie van de femorale venen werd eveneens geobserveerd. In dergelijke gevallen kan een injectie met percutaan autoloog beenmerg of corticoïde falen. Eveneens is er een potentieel risico van een vetembool bij injectie van beenmerg. Gebaseerd op deze bevindingen stellen wij voor dat een contrastinjectie altijd moet gebeuren vooraleer injectie met beenmerg of corticoïde.

RÉSUMÉ

J. C. ABRIL, J. A. QUEIRUGA, J. CASAS, J. ALBIÑANA. Observation inhabituelle après injection de produit de contraste dans un kyste osseux solitaire.

Le traitement du kyste osseux solitaire par injection de méthylprednisolone est une option reconnue. On a décrit aussi l'intérêt de l'injection d'un produit de contraste dans le kyste avant l'injection du corticoïde pour évaluer son degré de cloisonnement et s'assurer d'une distribution homogène du corticoïde dans le kyste.

Les auteurs rapportent une observation peu fréquente lors de l'injection intrakystique du produit de contraste au cours du traitement d'un kyste osseux essentiel. Une fois le contraste injecté, le remplissage du kyste a montré qu'il était biloculé. La cavité proximale n'a pas été opacifiée et l'on a observé un passage direct du produit de contraste dans la veine fémorale.

On peut déduire de cette observation que le traitement par injection percutanée de moëlle osseuse ou de corticoïde peut s'avérer inefficace dans certains cas de kyste osseux essentiel. Il existe de plus, un risque théorique d'embolie graisseuse secondaire à l'injection de moëlle osseuse.

Quand on a opté pour ce traitement, il semble donc utile d'injecter d'abord un produit de contraste dans le kyste, pour déterminer sa morphologie et son degré de cloisonnement et pour rechercher une éventuelle communication directe avec le système vasculaire.