

PSEUDODYSTROPHY A CONVERSION DISORDER MIMICKING REFLEX SYMPATHETIC DYSTROPHY

M. DRIESSENS¹, P. BLOCKX², G. GEUENS¹, H. DIJS¹, G. VERHEYEN¹, G. STASSIJS¹

The authors suggest some criteria by which pseudodystrophy and reflex sympathetic dystrophy, although sharing some similar clinical features, can be distinguished as two different conditions, each requiring its own approach and management. The most important distinction is found on bone scintigraphy. In reflex sympathetic dystrophy the bone scan shows a typical increased tracer uptake (at least during stages I and II) ; in pseudodystrophy there is a normal or decreased tracer uptake in the affected region. Moreover the vascularization is increased in reflex sympathetic dystrophy stage I, whereas in pseudodystrophy hypovascularization is found from the beginning.

The clinical features, as well as the results of technical investigations, psychological evaluation and treatment of 4 patients with pseudodystrophy are presented. The importance of distinguishing this condition from reflex sympathetic dystrophy is stressed.

Keywords : pseudodystrophy ; disuse related dystrophy ; reflex sympathetic dystrophy ; bone scintigraphy ; psychological factors.

Mots-clés : pseudodystrophie ; dystrophie par non-usage ; algodystrophie ; scintigraphie osseuse ; facteurs psychologiques.

stage II reflex sympathetic dystrophy (RSD), while both conditions are frequently initiated by trauma. Furthermore, radiological examination may show osteoporosis of the affected bone structures in both conditions. It is therefore not surprising that pseudodystrophy and reflex sympathetic dystrophy are frequently confused.

A completely different picture, however, may be seen on bone scintigraphy. While increased bone tracer uptake in the affected regions is considered to be an essential feature in the diagnosis of RSD stage I and II, patients with PD present with either normal findings, or, more frequently, with decreased tracer uptake, but never with increased uptake. Therefore, PD is referred to in the literature by various authors as "RSD with decreased uptake on bone scan" (3, 4, 8, 9, 10).

In our opinion, however, PD and RSD should be regarded as two separate entities, as there are other distinct differences, apart from the findings on bone scintigraphy. In stage I RSD vascular scintigraphy shows an increase in regional blood flow and blood volume (1, 2, 5), whereas in PD decreased blood flow and blood volume are observed right from the onset of the condition. Decreased blood flow and blood volume are also

INTRODUCTION

The clinical features of pseudodystrophy (PD) or disuse-related dystrophy usually include severe pain at a joint or part of a limb with major functional disability, cyanosis, coldness and edema or atrophy. Similar features may also be present in

Antwerp University Hospital, Departments of ¹Physical medicine and ²Nuclear Medicine.

Correspondence and reprints : M. Driessens, Department of Physical Medicine and Rehabilitation, University Hospital Antwerp, Wilrijkstraat 10, B-2650 Edegem, Belgium.

observed in stage II RSD, but in this case the bone scintigraphy still shows an increased tracer uptake (5).

It is only in stage III RSD that the findings on bone scan (normalization or slightly decreased uptake after initial increased uptake) and vascular scan (decreased blood flow and volume) may be similar to those observed in PD. In this case, however, differences may still be found in the clinical history and presentation of the patient. In stage III RSD, the pain usually becomes less or disappears, while pain is always a prominent feature of PD. Also, permanent joint stiffening is observed in stage III RSD due to sclerosis and retraction of the joint capsules, ligaments and tendons. In PD, passive joint mobility is usually preserved. If any limitation of joint mobility occurs, it can probably be attributed to muscle contractures, as is indicated by the fact that joint mobility is normal when the patient is placed under general anesthesia, which is not the case in RSD. Finally, unlike in RSD, pseudo-inflammatory signs are never seen during the course of PD.

Unfortunately, little is known with certainty about the pathophysiology of either RSD or PD. RSD, however, is frequently attributed to a deregulation of the sympathetic nervous system, while PD is considered to be due to disuse, usually associated with psychological lability or relational problems.

Finally, there appears to be a distinct difference in patient population. RSD is found in the entire adult population, without any specific correlation with age or gender. PD, on the other hand, is typically found in children, adolescents and young adults of the female sex.

As an illustration, four patients with PD are presented, each with a typical history and clinical findings. These four clinical cases were selected because the diagnosis of PD could be established beyond any doubt by the fact that previous treatment for RSD had been ineffective, and that cure was obtained after intensive physiotherapy and psychotherapy as the only treatment, which could never have been effective in real RSD. All four cases underline the importance of the underlying psychological disturbance.

Case report 1

A 41-year-old female secretary, married with two children, presented with the inability to move her right knee after a contusion four years before presentation.

She declared to have pain all the time and was unable to stand on her right leg. She had been treated by her general practitioner as suffering from RSD, diagnosed purely on clinical grounds. Current treatment consisted of physiotherapy and analgesics, but was experienced by the patient as ineffective.

Clinical assessment revealed cyanosis and hypothermia of the right leg (difference in skin temperature of 2.8° C). The right foot was fixed in equinovarus position and the right knee in 30° flexion. The patient reported a diffuse pain sensation on palpation of the right leg. She could walk with two elbow crutches, but without bearing weight on the right leg.

Standard xrays showed diffuse osteoporosis of the right knee, while 99mTc-MDP bone scintigraphy showed diffuse decreased tracer uptake in the affected leg (fig. 1). A 99mTc-HSA vascular scintigram (1, 5, 6) revealed hypoperfusion in the right

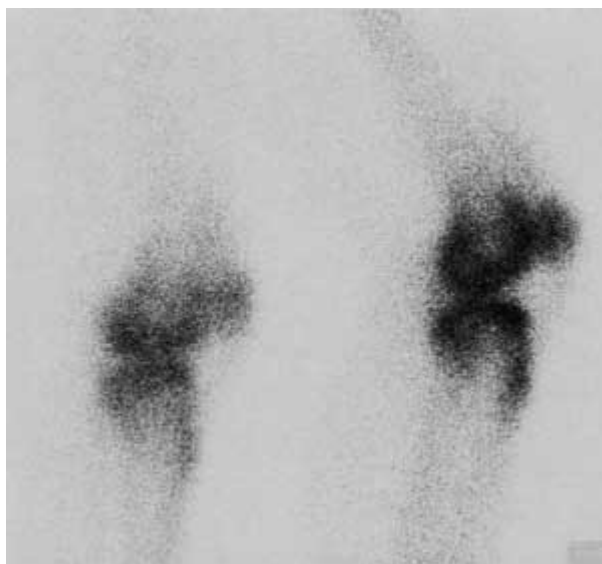


Fig. 1. — 99mTc-MDP-bone scintigraphy : diffuse decreased tracer uptake at the right knee.

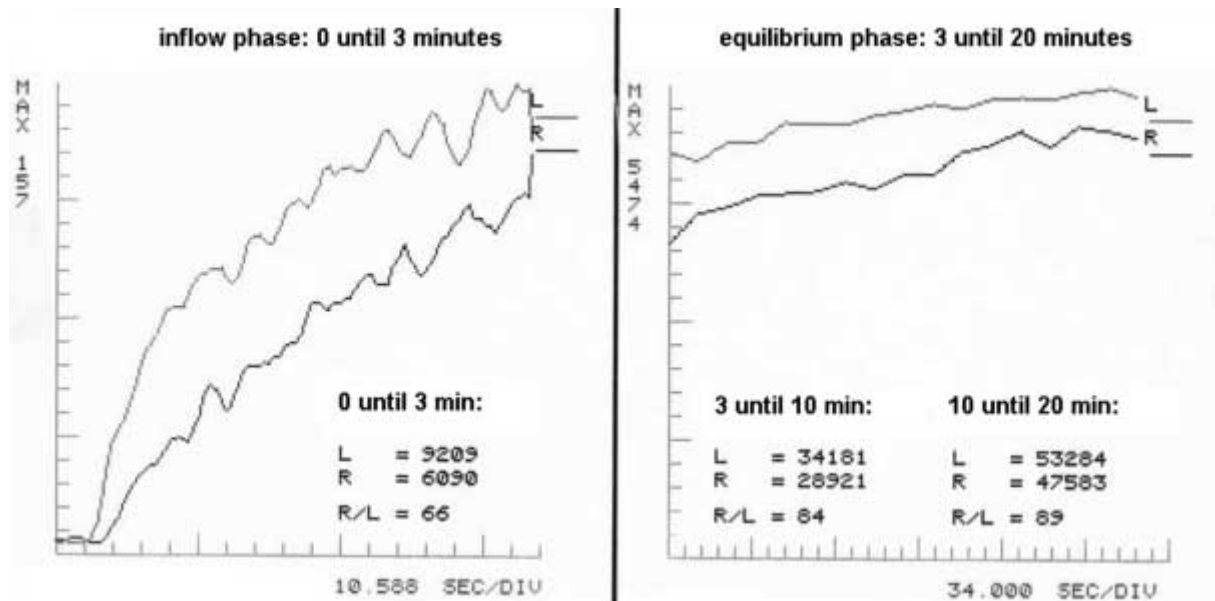


Fig. 2. — ^{99m}Tc -HSA-vascular scintigraphy showing hypoperfusion at the right leg compared to the left

Table I. — Common differences between RSD (stage I) and PD

	Reflex Sympathetic Dystrophy stage I	Pseudodystrophy
Patients	Adults of both sexes	Mostly young women and children
Clinical signs	Warmth, tenderness, joint stiffness	Coldness, cyanosis, tenderness ; no joint stiffness, but frequently compulsive posture
Precipitating factor	Frequently trauma	Psychosocial problem (+ trauma)
Bone scan	Increased tracer uptake	Normal or decreased bone tracer uptake
Vascular scan	Increased blood flow and blood volume	Normal or decreased blood flow and blood volume from the beginning

leg compared to the left (fig. 2). Neuropsychological assessment was terminated after one session, as the patient regarded this as “not necessary and senseless”. It was concluded, that the patient suffered from PD of the right knee (leg), probably with a psychogenic component.

The patient was hospitalized, and subsequent treatment consisted mainly of intensive physiotherapy with the accent on progressive active exercise therapy, while the analgesics were replaced by a placebo.

After two weeks, no significant improvement was achieved, and mobilization of the right leg under general anesthesia was carried out. This mobi-

lization showed no passive resistance whatsoever, and photographs were taken to show the patient (fig. 3). Intensive physiotherapy was continued and psychological awareness-therapy was started by repeatedly showing the patient the photographs made during mobilization under general anesthesia.

This approach resulted in a dramatic improvement : active flexion of the right knee up to 100° and normalization of the extension deficit after two weeks. The patient was transferred to her home town, where further out-patient treatment was continued. After two weeks, however, she discontinued the therapy. Thereafter she relapsed and started to

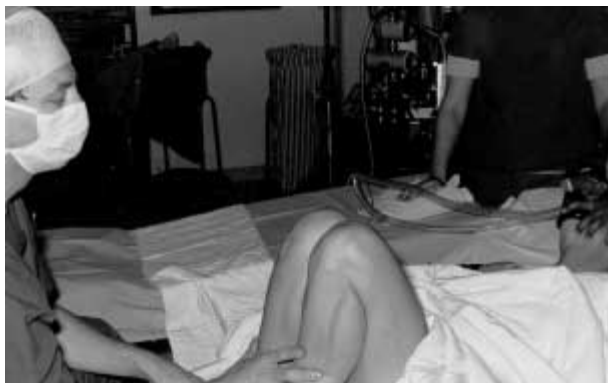

Fig. 3. — Mobilization under general anesthesia of the right knee showing no passive resistance.

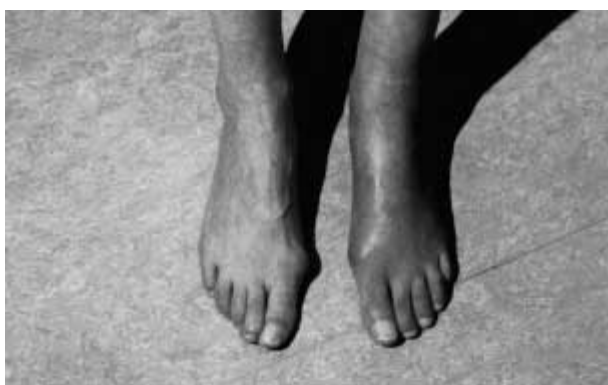

Fig. 4. — Erythrocyanosis of the left ankle and foot

use analgesics again in large amounts. Clinical examination of the right knee again showed a 50° flexion and 10° extension deficit.

Nevertheless, psychotherapy and physiotherapy were continued, and this finally resulted, after a few months, in partial healing and a satisfactory socioeconomic reintegration.

Case report 2

The second case concerns a 17-year-old girl attending high school, who presented with pain and functional impairment of the left ankle and foot of 2 years duration.

The medical history revealed epilepsy at the age of 7 years, controlled by valproic acid, and resection of a fibrohistiocytoma at the left ankle at the

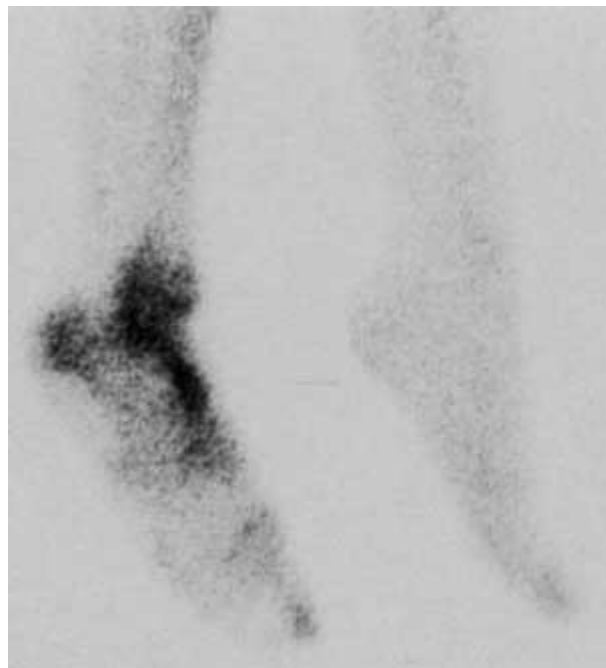


Fig. 5. — 99mTc-MDP-bone scintigraphy : diffuse decreased tracer uptake in the left ankle and foot.

age of 4 years with 4 reoperations over the following 10 years. Although the complaints were severe, the patient did not take any analgesics and she had not undergone physiotherapy.

Clinical examination showed hypothermia (difference in skin temperature of 1.5° C) with erythrocyanosis of the left ankle and foot (fig. 4). Attempts at passive mobilization of the ankle and foot joints met with active muscle resistance. Palpation-induced pain was reported at the left medial malleolus and midfoot. Measurement of the circumference at the midfoot and calf did not show any left-right differences. On walking, the patient showed severe limping.

Standard xrays showed diffuse osteoporosis of the left ankle and foot, most prominent at the toes, while bone scintigraphy showed a decrease in tracer uptake (fig. 5). The vascular scintigraphy showed decreased blood flow at the left ankle and foot, but a normal blood volume. MRI examination was normal, except for the presence of scar tissue, resulting from the multiple interventions the patient had undergone. Unlike passive mobilization, mobilization under general anesthesia did not show any

limitation of joint mobility. Psychological evaluation revealed a nervous and very anxious young woman who hoped to gain affection and attention from her busy parents by having a "serious disease".

The patient was treated with intensive physiotherapy and appropriate psychological counselling, resulting in a complete cure after 4 weeks. There was no relapse.

Case report 3

This 36-year-old female was referred from a "pain clinic" because of therapy-resistant pain and major functional impairment of the left ankle and foot after a traffic accident nearly three years previously. Previous examinations had revealed no major organic cause of the pain syndrome, and treatment including bracing of the ankle, transcutaneous electro-neuro stimulation (TENS); oral analgesics and sympathetic blocks had brought little or no relief. Finally a morphine pump had been implanted, allowing some control of the pain.

The psychosocial history of the patient was impressive. In childhood, she had been the victim of incest, and at the age of 15 she had been admitted to a psychiatric institution for three months. Two weeks prior to her marriage, she was readmitted for a few days. She had five children, but divorced 8 years ago and none of her children were presently staying with her. Recent psychiatric examination showed a personality disorder with manipulation and hysteric behaviour.

Physical examination showed an atrophic aspect of the left ankle and foot with erythrocyanosis and hypothermia (difference in skin temperature of 1.5° C). Active plantar flexion of the foot showed a predominance of the posterior tibial muscle with inversion of the foot. On palpation of the ankle and foot a diffuse pain sensation was reported. The patient was unable to stand on her left foot and used two elbow crutches. Passive mobilization of the ankle and foot joints, however, was normal.

Standard xrays showed diffuse osteoporosis of the left foot and ankle, bone scintigraphy showed decreased tracer uptake, and vascular scintigraphy

showed hypoperfusion of the affected left foot and ankle compared to the right.

The patient was admitted for intensive locomotor rehabilitation and psychological counselling. She had recently started a new relationship, and her new friend was asked to participate in the psychological support. The morphine was replaced by placebo, and eventually the pump was removed "to obviate infection". Oral placebo analgesics were started and progressively stopped again. In the meantime, intensive physiotherapy, hydrotherapy, occupational therapy and functional rehabilitation were started. The ankle brace and crutches were removed for increasingly longer periods of time, and weight bearing on the left ankle and foot encouraged.

This treatment program resulted in a gradual improvement of the psychological status and the functional disability of the patient.

After discharge from the clinic, however, the patient apparently attended a seance of an occult mystic sect, resulting in a "miraculous cure after exorcism". She experienced no more pain, while function of the left ankle and foot was restored to normal.

Case report 4

The last case involves a 26-year-old female with persisting complaints and functional impairment after distorsion of the right ankle due to an accident at work more than one year previously. Although bone scintigraphy was normal shortly after the accident, she had been treated elsewhere as suffering from RSD, without any result.

When she was first seen in our department, the patient avoided any weight bearing on the right leg, and she used two elbow crutches. Clinical examination showed an atrophic aspect and hypothermia of the right ankle and foot, but normal joint mobility.

Bone scintigraphy showed decreased tracer uptake in the affected region, and vascular scintigraphy showed decreased blood flow, but normal blood volume. Standard xrays showed slight osteoporosis of the right ankle and foot.

The patient was admitted for intensive rehabilitation and psychological evaluation. The latter revealed that the father of the patient had died just before the accident. Apparently, the father-daughter binding had been very strong, and the patient had not yet accepted the loss. Appropriate psychotherapy was started while the physiotherapy was continued, and a clinical cure was obtained after 3 months. There was no relapse.

DISCUSSION

Although it does not seem to be recognized as such in many studies (3, 4, 7, 8, 9, 10, 7), we suggest that PD is a clinical syndrome that should be differentiated from RSD.

First of all, PD requires its own management and therapeutic approach. As the case studies illustrate, psychogenic factors (usually relational problems, sometimes hysteric conversion, depression, psychosis) play an important part in PD, far more so than in RSD. Considerable effort should therefore be made to disclose and, if possible, to treat any underlying psychological disorders and social problems. The degree to which the psychological counselling succeeds, determines to a large extent the cooperation of the patient in his or her concomitant locomotor rehabilitation and reactivation. In the latter, the accent should be placed on active exercise therapy and, if the lower limb is involved, on obtaining full weight bearing, discouraging the use of braces, crutches and the like. Frequently, admission to a rehabilitation unit is indicated, not only to implement a full-time rehabilitation scheme, but also to withdraw the patient from her or his environment.

Other means of treatment may include the use of vasodilating and/or psychiatric drugs, as well as the gradual replacement of analgesics by placebo. Invasive and/or aggressive methods of treatment such as sympathectomy, placement of a neurostimulator or morphine pump and phenolization of nerves are best avoided as they may be more disabling than curative.

As opposed to stage I RSD, where it is frequently the treatment of choice, there is no place for

calcitonin in the treatment of PD. It has been shown that calcitonin has a vasoconstrictive effect on bone circulation (5), and the vascular scintigraphy shows that in PD there already exists a state of hypoperfusion.

Also, any factors that increase the pain sensation are best avoided in RSD, as they may further trigger the reflex mechanisms that are believed to cause this condition. This is not the case in PD. Subsequently in PD, physiotherapy may exceed the pain limit and full weight bearing on an affected lower limb may be encouraged, as opposed to stage I reflex sympathetic dystrophy.

Failure to differentiate between RSD and PD may not only lead to poor therapeutic results, but it also seems to invalidate many studies on this subject. For example, to what extent can the effect of a drug on RSD be assessed if the selected patient population also includes cases of PD and possibly also other clinically similar conditions such as posttraumatic arthritis? It would therefore appear, that an internationally accepted consensus on the diagnostic criteria of at least RSD (and if possible also of PD) is called for. The criteria of "complex regional pain syndrome" are an example of diagnostic confusion; at least bone scintigraphy should be included for differentiation between different syndromes.

Indeed, in the differentiation of RSD from PD, bone scintigraphy appears to be a very useful tool. In stage I and II RSD, bone scintigraphy shows increased tracer uptake, typically affecting an entire region. In PD, on the other hand, bone scintigraphy shows either normal findings, or, more frequently, decreased tracer uptake, but never an increase in tracer uptake. Also, the vascular scintigraphy shows increased regional blood supply in stage I, but in PD a decreased blood supply is seen right from the onset of this condition.

Only in stage III RSD may the findings on bone scintigraphy and vascular scintigraphy be similar to those observed in PD. In this case, however, differentiation is usually possible on clinical grounds and medical history. PD typically involves mostly young females and children. Passive joint mobility is usually normal and pseudoinflammatory signs are never seen, as opposed to RSD.

It seems that the concept of pseudodystrophy should replace what was earlier described as RSD with negative bone scan. This may explain therapeutic failures observed in the past in many studies about RSD.

REFERENCES

1. Blockx P., Driessens M. The use of ⁹⁹Tcm-HSA dynamic vascular examination in the staging and therapy monitoring of reflex sympathetic dystrophy. Nucl. Med. Comm., 1991, 12, 725-731.
2. Charkes J. Skeletal blood flow : Implications for bone-scan interpretation. Nuc. Med., 1980, 21, 91-98.
3. Dietz F. R., Mathews K. D., Montgomery W. J. Reflex sympathetic dystrophy in children. Clin. Orthop., 1990, 258, 225-231.
4. Doury P., Deshayes P., Pattin S., Gougeon J., Eaurly F., Renier J. C., Coulomb R., Masson C., Tabaraud F. Algodystrophie de l'enfant. A propos de quatre cas. Rev. Rhum., 1982, 11, 775-779.
5. Driessens M. Circulatory aspects of reflex sympathetic dystrophy. In : Bone Circulation and Vascularization in Normal and Pathological Conditions, 1993, Plenum Press, A. Schoutens *et al.*, eds., New York, pp. 217-231.
6. Driessens M., Blockx P., Mortier G., De Bruyne J. Evaluation of the vascular effect of calcitonin treatment in reflex sympathetic osteodystrophy. In : Bone Circulation, J. Arlet, R. P. Ficat, D. S. Hungerford, Williams & Wilkins, Baltimore/London, 1984, pp. 367-370.
7. Kim, C., Millin S., Park J. Scintigraphic patterns of the reflex sympathetic dystrophy syndrome of the lower extremities. Clin. Nucl. Med., 1989, 14, 657-661.
8. Kozin F. Reflex sympathetic dystrophy syndrome. Curr. Opin. Rheumatol., 1994, 6, 210-216.
9. Wilder R. T., Berde C. B., Wolohan M., Vieyra M. A., Masek B. J., Micheli J. Reflex sympathetic dystrophy in children. Clinical characteristics and follow-up of seventy patients. J. Bone Joint Surg., 1992, 74(A), 910-919.
10. Willame L. M., Sand A. Hypofixation on bone scintigraphy in reflex sympathetic dystrophy syndrome. Clin. Rheumatol., 1991, 10, 73-75.

SAMENVATTING

M. DRIESENS, P. BLOCKX, G. GEUENS, H. DIJS, G. VERHEYEN, G. STASSIJNS. *Pseudodystrofie.*

De auteurs suggeren enkele criteria volgens dewelke pseudodystrofie en reflexalgodystrofie, hoewel ze soms bepaalde klinische gelijkenissen vertonen, toch kunnen onderscheiden worden als 2 verschillende pathologieën, die elk hun eigen benadering vereisen.

Het belangrijkste verschil wordt door botscintigrafie aangetoond. Bij reflexalgodystrofie toont de botscan een verhoogde traceropname (toch op zijn minst in stadia I en II), bij pseudodystrofie is er een normale of verminderde traceropname in de desbetreffende zone. Daar waar de doorbloeding verhoogd is in het eerste stadium van algodystrofie, is ze eerder van in het begin verlaagd bij pseudodystrofie.

In dit artikel worden de klinische gegevens samen met de resultaten van technische onderzoeken, psychologische evaluatie en behandeling van 4 patiënten met pseudodystrofie voorgesteld.

Het komt erop aan pseudodystrofie te onderscheiden van algodystrofie.

RÉSUMÉ

M. DRIESENS, P. BLOCKX, G. GEUENS, H. DIJS, G. VERHEYEN, G. STASSIJNS. *La pseudodystrophie.*

Les auteurs suggèrent quelques critères pour différencier la pseudodystrophie de la neuro-algodystrophie réflexe. Toutes deux ont parfois la même présentation clinique.

La différence se fait par la scintigraphie osseuse. Dans la neuro-algodystrophie réflexe, la scintigraphie osseuse montre une augmentation de la captation du traceur osseux dans la zone concernée (du moins aux stades I et II), tandis que dans la pseudodystrophie on retrouve une captation normale ou diminuée.

Là où la circulation sanguine est augmentée dans le stade I de l'algodystrophie on la retrouve diminuée pour la pseudodystrophie.

Dans cette article sont décrits les données cliniques, les résultats d'examen techniques, l'évaluation psychologique et le traitement de quatre patients souffrant d'une pseudodystrophie.

L'accent est mis sur l'importance de la distinction entre la pseudodystrophie et l'algodystrophie.