

WHICH PROCEDURE GIVES BEST RESULTS IN RECONSTRUCTING DISLOCATED HIP JOINTS IN CEREBRAL PALSY ?

BRUNNER R.

A retrospective study of the surgical repair of dislocated or subluxed hip joints in patients with spastic cerebral palsy was carried out to determine the procedure with the lowest recurrence rate. An open reduction and a corrective femoral osteotomy were combined with different pelvic osteotomies and different interventions on the iliopsoas muscle in most cases. The radiological results in 58 hip joints of 42 patients were assessed with a follow-up time of 5.9 years on average (2.8 to 11.0 years). Although some combined procedures were carried out in only a small number of cases, we can still draw some conclusions.

The results were better, if a pelvic osteotomy and an intervention on the iliopsoas muscle were performed. An additional iliopsoas transfer made the hip joints more stable over the long term than lengthening. For severely deformed acetabula the Pemberton osteotomy was superior to the Chiari osteotomy. The Salter osteotomy was a good alternative in cases with mild subluxation. With some combined procedures the redislocation rate was as high as 66%, whereas the combination of an open reduction, a femoral osteotomy, an iliopsoas transfer and a Pemberton or Salter osteotomy gave a redislocation rate of only 11%. A concentric reduction of the hip joints was necessary. Primarily noncentered joints did not improve during the later course.

Keywords : hip dislocation ; hip subluxation ; cerebral palsy ; surgical procedure ; outcome.

Mots-clés : luxation de hanche ; subluxation de hanche ; technique opératoire ; résultat.

of the neurological problem. Howard *et al.* (7) reported a 33% prevalence in 85 patients. Twenty-six (59%) of 44 patients with total body involvement cerebral palsy had an unstable hip joint. In 29 diplegic patients, however, there were only 2 abnormal hips. Twenty-two hemiplegic patients showed no abnormalities of their hip joints. Lonstein and Beck (8) found 57% of decentered hip joints in nonwalkers, but only 11% in walkers.

Clinically a dislocation or subluxation becomes apparent because of pain, stiffness or instability. Pain is difficult to assess in severely handicapped patients who are unable to express themselves, but is frequently present. Bleck (1) reports pain in about 1/3 of dislocated hip joints after the age of 15 years, and according to Coopermann *et al.* (6), up to 50% of dislocated hip joints will become painful. Besides pain, stiffness of the hip is a further clinical sign of a dislocation or subluxation. The reduced mobility of the joint predisposes to fractures of the leg (3, 8). The instability of the hip joint results from an acetabular deformity : the femoral head presses a channel into the acetabular roof and shifts along this slope (4).

Pain, instability and stiffness of the hip joint interfere with daily activities and impede the ability of the patient to walk, to stand and finally to sit. Thus surgery is indicated for the hip dislocations and should aim to achieve a painfree, stable and mobile joint. On this basis the perfor-

INTRODUCTION

Hip dislocation or subluxation is a common complication in patients with cerebral palsy. It occurs in up to 59% depending on the severity

Division of Pediatric Orthopedics, University of Basel, Switzerland.

Correspondence and reprints : R. Brunner, Division of Pediatric Orthopedics, Neuro-Orthopedic Unit, Children's Hospital, CH-4005 Basel.

mance of the locomotor functions can improve and the quality of life of these often wheelchair-dependent patients will be ameliorated.

The dislocated hip joint always presents a typical uniform complex anatomical deformity in patients with cerebral palsy. It consists of a de-centered joint, a channel-like deformity of the acetabulum (4), increased femoral anteversion and CCD-angle, a deformation of the femoral head, muscle shortening and imbalance. All these structural and functional deformities have to be taken into account when the hip joint is repaired surgically. The procedure therefore consists of several surgical steps. A variety of such combinations, however, is possible: Mubarak *et al.* (10) combine a femoral shortening-derotation-varus osteotomy, a pericapsular pelvic osteotomy, an adductor release, a psoas release and a release of the proximal hamstrings, Samilson *et al.* (12) prefer an open reduction with a femoral osteotomy and soft tissue surgery, and Root *et al.* (11) perform a femoral osteotomy in combination with an open reduction, a pelvic osteotomy of different types and an iliopsoas release. Adductor tenotomies are added if necessary.

At our unit various surgical steps were used in different combinations for the repair of dislocated or subluxed hip joints in patients with cerebral palsy. In addition to an open reduction and a femoral corrective osteotomy several pelvic osteotomies and interventions on the iliopsoas muscle were carried out. The pelvic osteotomies as well as the iliopsoas operations represented different therapeutic principles: the acetabulum can be shaped, reorientated or augmented, and the iliopsoas can be lengthened (or tenotomized) or the direction of pull can be changed. The aim of the present study was to find the most appropriate combination of surgical steps to improve the results of the repairs. We particularly emphasized analysis of the effects of the pelvic osteotomies and the iliopsoas operations.

PATIENTS AND METHODS

All patients with spastic cerebral palsy who underwent a surgical repair of a dislocated or subluxed hip joint between 1982 and 1989 with a minimum radi-

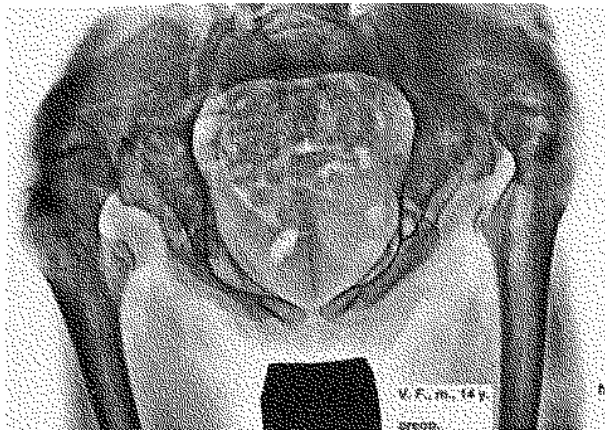
ological follow-up of 2 years were included. The lateralization index and the modified CE-Wyberg angle (9) to correct for the effect of unilateral subluxation were utilized to assess the centration of the hip joint. The xrays taken before surgery, after surgery, closest to 2.5 years and at last recheck (average 5.9 years, 2.8 to 11.0 years) were analyzed. A lateralization index of less than 25% was rated as centered, between 25 and 50% as subluxed and over 50% as dislocated. Only descriptive statistics were used.

Forty-two patients with 58 surgically repaired hip joints were included into the study. Twenty-two of the 42 patients were female, 20 male. The age at surgery averaged 10.1 years (3.4 to 19.4 years). The left hip was affected in 30 cases, the right hip in 28. Before surgery 6 hip joints were subluxed; 52 were dislocated. In 9 hip joints the open reduction failed. They were studied as a separate group. In the remaining 49 hip joints 7 Salter osteotomies, 6 Chiari osteotomies and 27 Pemberton osteotomies were carried out. The iliopsoas was transferred anteriorly according to Mustard in 35 and lengthened in 4 cases. The data were analyzed with respect to the different pelvic osteotomies, the types of iliopsoas surgery and their combinations.

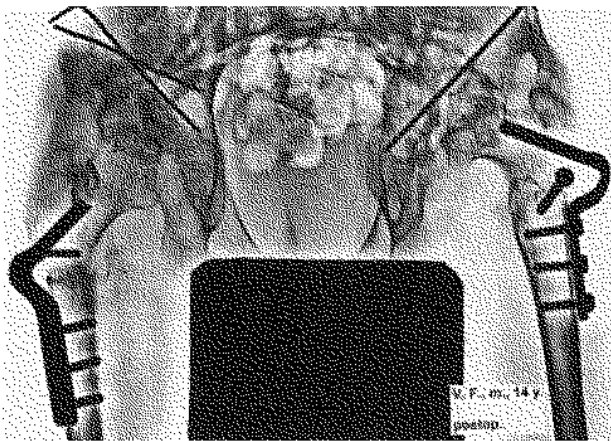
INDICATIONS AND SURGICAL PROCEDURE

A stable, mobile and painfree hip joint is the best prerequisite for sitting, standing and walking. This goal can only be reached by repair of the dislocated hip joint. Any more destructive surgery such as proximal femoral resection can still be carried out in cases of failure. Because of this all dislocated hip joints, even in the neurologically most severely affected patients, were reconstructed by a combined surgical procedure.

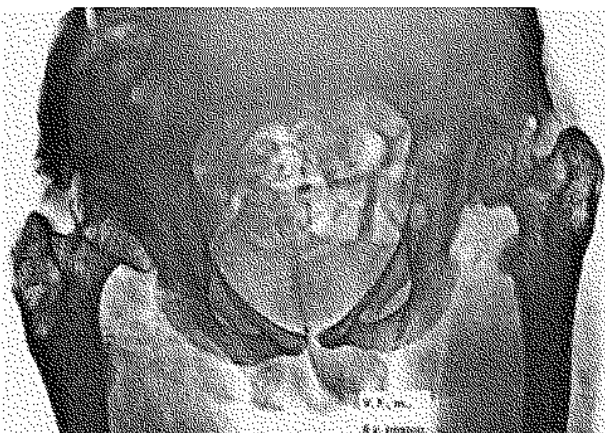
An anterior approach was used to expose the hip joint. The joint was opened and reduced in all cases. Using the same incision, the surgery for the iliopsoas and the pelvic osteotomy were performed. The iliopsoas was transferred (36 hips) in patients with severe spasticity and was lengthened (4 hips) or left untouched (9 hips) in the less severely affected patients. If the acetabulum was still concave, pelvic osteotomy (8 hips) or a Salter osteotomy (7 hips) was not added. If the acetabulum was more severely deformed, a Pemberton osteotomy (27 hips) or a Chiari osteotomy (6 hips) was carried out.



a



b



c

Through a lateral approach a femoral derotation-varus osteotomy was performed in all cases. The femur was osteotomized before the open reduction and the pelvic osteotomy and was fixed only after these procedures by a blade-plate with a correction of the neck-shaft angle to 120° to 125° and of the anteversion to 10° to 25° .

RESULTS

Forty-nine hips were reduced after the combined surgical procedure. At 2.5 years, 9 were resubluxed, but none dislocated. When last seen at 5.9 years on average, 11 hips had subluxed and 3 had dislocated. The redislocation rate at 2.5 years was 18% (9/49 hips), at 5.9 years, 29% (14/49).

Nine hip joints remained dislocated despite surgery. None of these hip joints centered spontaneously or improved during the later course.

a. Effects of pelvic osteotomy (Table I)

With the Pemberton osteotomy 18% (5/28) of the hip joints resubluxed within 2.5 years. After 5.9 years 2 more hip joints had subluxed and 1 had progressed to dislocation. Six hip joints were well centered after 2.5 years (lateralization index = 0%) and were lost to follow-up; they were regarded as centered. The redislocation rate at last follow up was 25% (7/28).

With the Chiari osteotomy 2 out of 6 hips had subluxed after 2.5 years. After 5.9 years, only 2 out of 6 were centered, 3 had subluxed and 1 had progressed to complete dislocation. The redislocation rate was 4 out of 6.

With the Salter osteotomy only 1 hip out of 7 had subluxed after 5.9 years. The redislocation rate was 1 out of 7.

Without any pelvic osteotomy 2 out of 8 hips had subluxed after 2 years. After 5.9 years 1 was

Fig. 1. — Chiari pre-/postoperatively. a) Preoperative view of the hip joints of a 14-year-old tetraspastic boy. b) X rays after the repair including an iliopsoas transfer and a Chiari osteotomy as well as a corrective femoral osteotomy and an open reduction. The right hip is acceptably centered, whereas the left hip remains subluxed. c) After 6 years the coverage of the right hip has not changed, but the femoral head is flattened. The subluxation on the left side has increased.

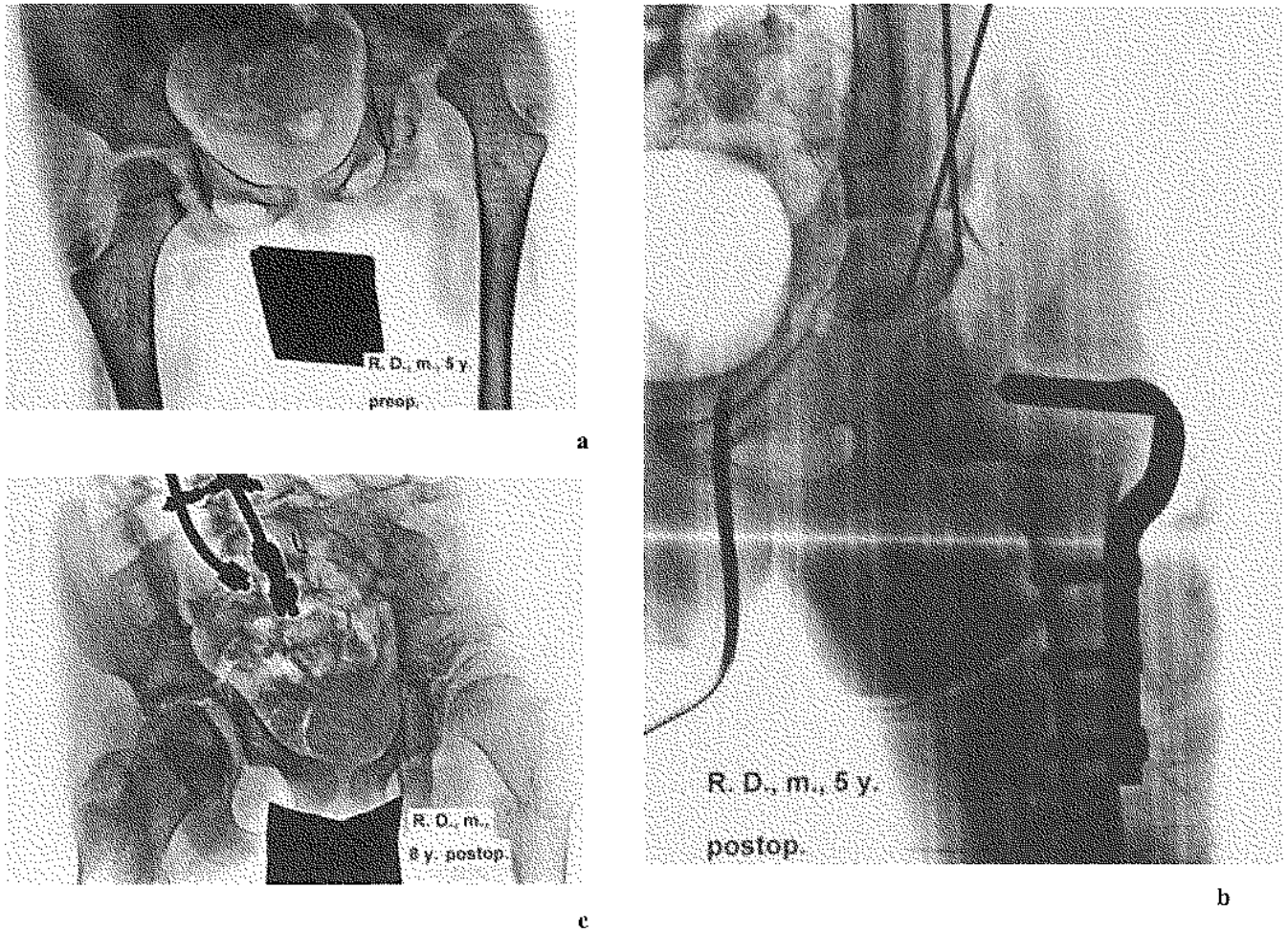


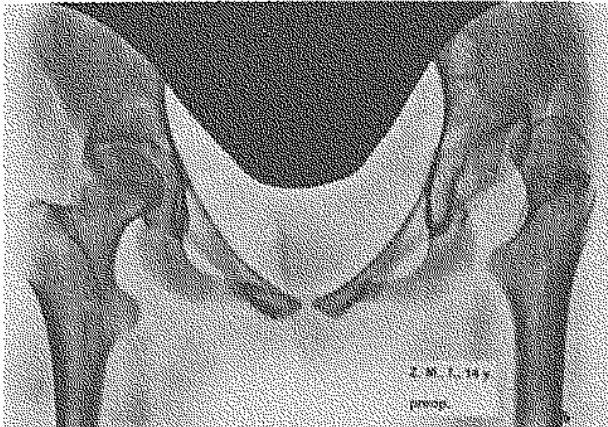
Fig. 2. — Salter pre-/postoperatively. a) Left hip dislocation in a 5-year-old tetraspastic boy preoperatively. b) The left hip after corrective femoral osteotomy, iliopsoas transfer, Salter osteotomy and open reduction. c) 8 years postoperatively: the joint is concentrically reduced and congruent.

Table I. — Results of different pelvic osteotomies (total : 49 hip joints)

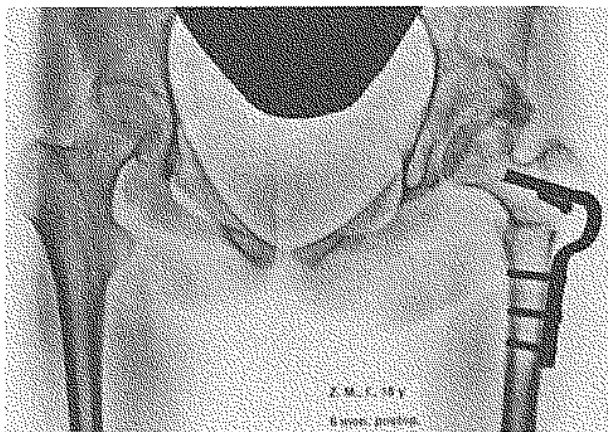
		lost	centered	subluxed	dislocated
None (n = 8)	postop.	0	8	0	0
	2.5 years	0	6	2	0
	5.9 years	1	5	1	1
Pemberton (n = 28)	postop.	0	28	0	0
	2.5 years	0	23	5	0
	5.9 years	6	15	6	1
Salter (n = 7)	postop.	0	7	0	0
	2.5 years	1	6	0	0
	5.9 years	0	6	1	0
Chiari (n = 6)	postop.	0	6	0	0
	2.5 years	0	4	2	0
	5.9 years	0	2	3	1

Table II.— Results of different types of interventions on the psoas (total : 49 hip joints)

		lost	centered	subluxed	dislocated
None (n = 9)	postop.	0	9	0	0
	2.5 years	0	8	1	0
	5.9 years	1	4	3	1
Transfer (n = 36)	postop.	0	36	0	0
	2.5 years	0	28	8	0
	5.9 years	6	21	7	2
Lengthening (n = 4)	postop.	0	4	0	0
	2.5 years	1	3	0	0
	5.9 years	0	3	1	0



a



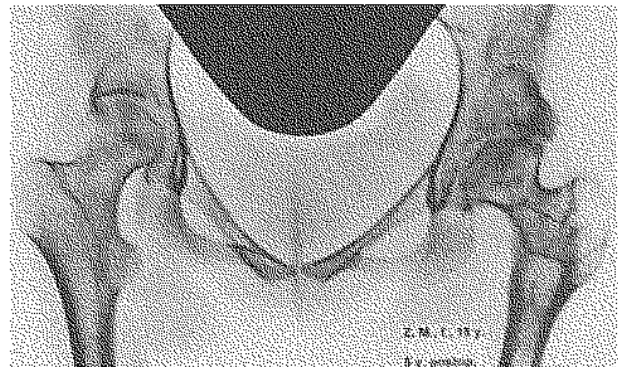
b

lost to follow-up, 1 was subluxed and 1 was dislocated. The redislocation rate was 2 out of 8.

b. Iliopsoas intervention (Table II)

With the iliopsoas transfer according to Mustard, 8 out of 36 hips were subluxed after 2.5 years. At 5.9 years after surgery 2 had progressed to complete dislocation and 7 had subluxed. Six were lost to final follow-up. The redislocation rate was 25% (9/36). Lengthening of the iliopsoas was carried out 4 times. No hips had deteriorated at 2.5 years. At 5.9 years, one hip had subluxed (redislocation rate : 1 out of 4).

Without any operation on the iliopsoas muscle, one out of 9 hips was subluxed after 2.5 years. At final control 5.9 years postoperatively 1 patient was lost. Three hips were subluxed and 1 was dislocated (redislocation rate : 4 out of 9).



c

Fig. 3. — Pemberton pre-/postoperatively. a) Left hip dislocation in a 14-year-old tetraplastic girl before surgery. b) After corrective femoral osteotomy, iliopsoas transfer, Pemberton osteotomy and open reduction. c) 5 years postoperatively : the hip joint is congruent and concentrically reduced.

Table III. — Results of different combinations of pelvic osteotomies and psoas surgery (Total : 49 hip joints)

pelvic osteotomy	psoas surgery	time postop.	lost	centered	subluxed	dislocated
None (n = 8)	transfer	postop.	0	8	0	0
		2.5 years	0	6	2	0
		5.9 years	1	5	1	1
Pemberton (n = 6)	none	postop.	0	6	0	0
		2.5 years	0	5	1	0
		5.9 years	1	2	2	1
Pemberton (n = 21)	transfer	postop.	0	21	0	0
		2.5 years	0	17	4	0
		5.9 years	5	12	4	0
Pemberton (n = 1)	lengthening	postop.	0	1	0	0
		2.5 years	0	1	0	0
		5.9 years	0	1	0	0
Salter (n = 1)	none	postop.	0	1	0	0
		2.5 years	0	1	0	0
		5.9 years	0	1	0	0
Salter (n = 3)	transfer	postop.	0	3	0	0
		2.5 years	0	3	0	0
		5.9 years	0	3	0	0
Salter (n = 3)	lengthening	postop.	0	3	0	0
		2.5 years	1	2	0	0
		5.9 years	0	2	1	0
Chiari (n = 2)	none	postop.	0	2	0	0
		2.5 years	0	2	0	0
		5.9 years	0	1	1	0
Chiari (n = 4)	transfer	postop.	0	4	0	0
		2.5 years	0	2	2	0
		5.9 years	0	1	2	1

c. The combined effect of iliopsoas intervention and pelvic osteotomy (Table III)

Not all possible combinations of the different types of iliopsoas interventions and pelvic osteotomies had been carried out. Some combinations, such as the Pemberton osteotomy with lengthening of the iliopsoas or the Salter osteotomy alone were performed in one case only. Thus these data are not conclusive. The combinations that were carried out more frequently were looked at in detail.

After the Chiari osteotomy combined with iliopsoas transfer, only 1 hip joint remained centered. Out of 4 hips, 1 had dislocated and 2 had subluxed at last check-up 5.9 years postoperatively.

The combination of the Pemberton osteotomy with the iliopsoas transfer carried out in 21 hips resulted in 1 subluxation in 4 cases 2.5 years after surgery. The redislocation rate was 4 out of 21.

No redislocations occurred after a Salter osteotomy with an iliopsoas transfer. This combination was carried out in 3 hips. The Salter osteotomy in combination with the elongation of the iliopsoas was carried out in 3 cases and resulted in resubluxation of 1 hip joint (redislocation rate 1 out of 3).

If only the Pemberton or the Salter osteotomies combined with the iliopsoas transfer were analyzed, the redislocation rate was 4 out of 24.

The average lateralization index deteriorated although the hips were well centered immediately

after surgery. The lateralization index increased to + 10.9% on average with the iliopsoas transfer alone (max. + 50%, min. -16.7%), and to + 25% (range + 48% to 3.8%) in combination with the Pemberton osteotomy. After the Pemberton osteotomy alone the lateralization index deteriorated by + 21.3% (range + 50% to -7.6%). With the Chiari osteotomy combined with an iliopsoas transfer all hip joints deteriorated. The lateralization index increased by + 32% on average (range + 50% to + 11%).

The course of the center-edge angle (CE angle) was similar. The iliopsoas transfer combined with the Pemberton osteotomy was best without any deterioration on average (change of CE-angle: mean 0.0°, range -25° to + 37°). The iliopsoas transfer alone led to a deterioration. The CE-angle decreased by -1.9° on average (range -28° to + 30°). With the Pemberton osteotomy alone the CE-angle decreased by -7.2° (range 42° to + 15°). With a Chiari osteotomy all hip joints deteriorated (decrease in lateralization index: mean -15.8°, range -25° to -3°).

DISCUSSION

The risk for a hip to dislocate is high in severely handicapped patients with cerebral palsy. A morbidity up to 59% has been reported (7). The dislocated hips are unstable and can become painful and stiff (1, 6, 8). These conditions will impair the patient's ability to walk, to stand and even to sit. The handicap of the patient is increased. Surgery is indicated to improve the patient's function, his quality of life and the preconditions for further rehabilitation.

A typical complex of anatomical deformities is present in these hip joints. The joint is decentered (subluxed or dislocated). The acetabulum shows a channel-like deformation of the acetabular roof (4). The femur is anteverted and the neck shaft angle is increased. The femoral head is deformed, presenting a groove in the cranio-lateral part in older patients or a head-in-neck deformity in younger ones. Some muscle groups like the adductors, the flexors and the hamstrings are short. The activity of the muscles acting on the hip is imbalanced. The correction of this complex

pathological anatomy requires an extensive surgical repair combining different procedures.

In 1972 Samilson (12) presented his results combining soft tissue surgery to balance the muscle forces with a corrective femoral osteotomy and reported an overall redislocation rate of 33%. To improve these results and to decrease the number of redislocations, further surgical steps were included in one intervention: the rationale for the pelvic osteotomy as the acetabular deformity was described by several authors (4, 5). In 1975 Sharrard (13) added a pelvic osteotomy but only in one case. Sherk (14) did not have any redislocations when performing a combination of a femoral osteotomy, a pelvic (Salter or Chiari) osteotomy and an anterior iliopsoas transfer in 15 patients with a follow-up time between 1 and 10 years. Mubarak in 1992 (10) described his surgical procedure combining a femoral shortening and varus derotation osteotomy, a pericapsular pelvic osteotomy and an extensive soft tissue release and reported a redislocation rate of 6% (1 of 18) after 6 to 12 years. Root (11), however, presented his review after a surgical approach combining an open reduction, pelvic osteotomy (Salter 26, Chiari 5, Sutherland double 3, Pemberton 1), an iliopsoas recession and an open reduction. Hips that were only subluxed before surgery showed a good outcome with a redislocation rate of 6% (1/17 cases), whereas redislocations were much more common in cases of dislocations (61%, 11/18 cases). Although the overall redislocation rate (lateralization index over 25%) was 34%, the patients had improved clinically. Similar findings were made in our patients: our overall redislocation rate was 18% at 2.5 years and 29% at 5.9 years, 52 out of 58 hips being dislocated preoperatively. Our clinical results published in detail in 1993 (including 6 patients with poor radiological follow-up), however, showed an overall improvement: all the hips were painfree or pain was substantially reduced, sitting was improved in 47% and walking in 21% of the patients (2). The present data show an increase in the redislocation rate over time, which is not unexpected, because only the secondary effects of the primary neurological disease are addressed, when the hip joint is reconstructed. The basic

disease remains unaffected and continues to produce pathological forces. Thus it is not appropriate to summarize data from follow-up visits performed over a wide range in time under a "last follow-up". The effects of surgery in this condition have to be studied in relation to time.

In the present retrospective study the indications for a procedure or combinations of procedures varied. The effect of a pelvic osteotomy and an iliopsoas intervention may influence each other. Some combinations have only been done in a small number, sometimes even in isolated cases. These facts make a conclusive statistical analysis impossible. Nevertheless, conclusions can be drawn to optimize the repair of dislocated hip joints in cerebral palsy.

In principle, three groups of pelvic osteotomies can be distinguished :

- The acetabulum can be reorientated within the pelvis (Salter, Triple, Sutherland Double) ;
- The acetabulum can be shaped (Pemberton) ;
- The acetabular cover can be increased (Chiari, shelf procedure).

In our patients one of each of basically different types of pelvic osteotomy was carried out. Therefore we were able to study the effect of different pelvic osteotomies.

In mild acetabular deformities where the prognosis regarding the risk for recurrences is better anyway, no pelvic osteotomy was carried out, or the Salter osteotomy was added alternatively. Without any pelvic osteotomy we had a redislocation rate of 2 out of 8, which is better than the redislocation rate of Samilson (33%) (12). The difference can be explained by the iliopsoas transfer which was carried out additionally in our hip repairs. The Salter osteotomy to reorientate the acetabulum was carried out only when the acetabulum was still concave. Root (11) described 11 out of 18 redislocations after dislocations of the hip joints and only 1 out of 17 after subluxations only. In our study the redislocation rate with the Salter osteotomy was higher with 1 out of 7. Nevertheless, we see an indication for this osteotomy in hip joints with still concave acetabula. Severely deformed acetabula were corrected by a Chiari or a Pemberton osteotomy alternatively. The Chiari

osteotomy carried out to increase the femoral head coverage was not very helpful to maintain hip centration. Four out of 6 hips had dislocated by the final follow-up. The acetabulum could be shaped by the Pemberton osteotomy. The sliding channel rolled in the acetabulum by the femoral head was mobilized and bent down over the femoral head. In this way the original acetabular cartilage in the contact area of the hip joint was preserved. The results were much better with a redislocation rate of 25%. According to these results the Pemberton osteotomy is superior to the Chiari.

Another subject of discussion is the importance of iliopsoas surgery and especially the need for transfer. The elongation or recession of the iliopsoas, however, is commonly added to the repair of the hip joint (10, 11). The recession must be considered as a massive elongation. The continuity between both ends of the tendon of the iliopsoas muscle will be maintained by the iliacus part. A connection will be formed again. The final result is a much longer psoas tendon. The insertion, however, will be at the original point. Again, cases with different interventions at the iliopsoas muscle were distinguished : either no intervention was carried out at all or the muscle was elongated. These procedures were indicated in the neurologically less affected patients. The direction of pull of the muscle remained unchanged after this intervention. Without any surgery on the iliopsoas we had a rate of redislocation of 4 out of 9. The number of psoas lengthenings (4) is too small to allow any conclusion about the effect. One out of 4 hips had redislocated before the last follow-up, however. In patients with more severe cerebral palsy the iliopsoas was transferred anteriorly according to Mustard. By this procedure the muscle became an internal rotator and pulled along the femoral neck. The redislocation rate with the iliopsoas transfer was 25% after 5.9 years. Although these patients suffered from more severe neurological damage, the redislocation rate was not higher than in the less severely affected patients without any psoas surgery, indicating the stabilizing effect of the iliopsoas transfer. Sherk (14) in his paper, too, indicated that an iliopsoas transfer would reduce the redislocation

rate. Unfortunately he did not clearly note the follow-up period. From his results and ours it was concluded that the iliopsoas transfer helped to stabilize the hip joint, and was superior to the elongation or recession.

Our data showed that by a procedure correcting the shape of severely deformed acetabula (as with the Pemberton osteotomy) or reorienting the acetabulum in mild deformities (as with the Salter osteotomy) in combination with a muscle-balancing procedure as the anterior iliopsoas transfer performed in addition to a femoral corrective osteotomy and an open reduction, the redislocation rate can be reduced. The redislocation rate was 11%. On the basis of the preliminary data after 2.5 years we set the procedure to reconstruct the hip joints in patients with cerebral palsy: since 1990 we combine a femoral derotation varus shortening osteotomy, a Pemberton osteotomy (Salter in mildly deformed hip joints only), an open reduction and an anterior iliopsoas transfer and, if necessary, additional muscle lengthenings. Our redislocation rate currently is 5% (4 out of 82 hip joints, mean follow-up time 1.9 years, not included in this study) and coincides with Mubarak (10), who had a similar redislocation rate after almost 7 years with a comparable approach. Our current redislocation rate underscores the soundness of our present combined surgery.

The combination of the Pemberton osteotomy in severe cases, the Salter osteotomy in mild deformities and the iliopsoas transfer in addition to an open reduction and a corrective osteotomy of the femur is the most favorable procedure according to our results.

A small number of hip joints in the present study remained uncentered (subluxed or dislocated) in spite of any surgery at the pelvis or the iliopsoas muscle. None of these hip joints improved during the later course. Thus whatever procedure is carried out in order to repair a dislocated or a subluxed hip joint in a patient with cerebral palsy, the intervention needs to result in a concentric reduction of the hip joint.

As the basic neurological disorder is incurable and only secondary problems may be treated, studies should present comparable results over time. Deterioration with time must be calculated.

CONCLUSION

A concentric reduction of the hip joint is mandatory. A subluxed or dislocated hip joint will not center spontaneously.

Complex pathological anatomy is present in dislocated hip joints in cerebral palsy patients. A combined surgical procedure to repair as many of these deformities as possible gives the best results. It should include an open reduction, a pelvic osteotomy, a femoral shortening varus derotation osteotomy and an anterior iliopsoas transfer with optional additional muscle lengthening in case of contractures. If the acetabulum is still concave, a reorientation (such as the Salter osteotomy) can improve the femoral head coverage. In more severe acetabular deformities surgery is needed to correct the shape. The Pemberton type of osteotomy is most appropriate. A procedure to increase the acetabular cover (the Chiari osteotomy) was not successful. Iliopsoas transfer increases the stability of the hip over the long term. It is superior to lengthening or recession only.

REFERENCES

1. Bleck E. E. The hip in cerebral palsy. *Orthop. Clin. N. Am.*, 1980, 11, 79-104.
2. Brunner R., Baumann J. U. Clinical benefit of reconstruction of dislocated or subluxated hip joints in patients with spastic cerebral palsy. *J. Pediatr. Orthop.*, 1994, 14, 290-294.
3. Brunner R., Döderlein L. Pathological fractures in patients with cerebral palsy. *J. Pediatr. Orthop. Part B*, 1996, 5/4, 232-238.
4. Brunner R., Picard C., Robb J. Morphology of the acetabulum in hip dislocations caused by cerebral palsy. *J. Pediatr. Orthop.*, part B, 1997, 6 : 207-211.
5. Buckley S. L., Sponseller P. D., Magid D. The Acetabulum in congenital and neuromuscular hip instability. *J. Pediatr. Orthop.*, 1991, 1, 498-501.
6. Coopermann D. R., Bartucci E., Dietrick E., Millar E. A. Hip dislocation in spastic cerebral palsy: Long term consequences. *J. Pediatr. Orthop.*, 1987, 7, 268-276.
7. Howard C. B., McKibbin B., Williams L. A., Mackie I. Factors affecting the incidence of hip dislocation in cerebral palsy. *J. Bone Joint Surg.* 1985, 67-B, 530-532.
8. Lonstein J. E., Beck K. Hip dislocation and subluxation in cerebral palsy. *J. Pediatr. Orthop.*, 1986, 6, 521-526.
9. Massie W. K., Howorth M. B. Congenital dislocation of the hip. Part 1: Method of grading results. *J. Bone Joint Surg.*, 1950, 32-A, 519-531.

10. Mubarak J. S., Valencia G. F., Wenger R. D. One-stage correction of the spastic dislocated hip. Use of pericapsular acetabuloplasty to improve coverage. *J. Bone Joint Surg.*, 1992, 74-A, 1347-1357.
11. Root L., Laplaza F. J., Brouman S. N., Angel D. H. The severely unstable hip in cerebral palsy. Treatment with open reduction, pelvic osteotomy and femoral osteotomy with shortening. *J. Bone Joint Surg.*, 1995, 77-A, 703-712.
12. Samilson R. L., Tsou P., Aamoth G., Green W. M. Dislocation and subluxation of the hip in cerebral palsy. *J. Bone Joint Surg.*, 1972, 54-A, 863-873.
13. Sharrard W. J. W., Allen J. M. H., Heaney S. H., Prendiville G. R. G. Surgical prophylaxis of subluxation and dislocation of the hip in cerebral palsy. *J. Bone Joint Surg.*, 1975, 57-B, 160-166.
14. Sherk H. H., Pasquariello P. D., Doherty J. Hip dislocation in cerebral palsy: Selection for treatment. *Dev. Med. Child Neurol.*, 1983, 25, 738-746.

SAMENVATTING

R. BRUNNER. Welke procedure geeft de beste resultaten voor de reconstructie van heupluxaties in infantiele encephalopathie.

Een retrospectieve studie van het chirurgisch herstel van geluxeerde of gesubluxeerde heupen bij patiënten met infantiele encephalopathie werd uitgevoerd om te bepalen welke procedure het geringste recidief vertoonde. Een open reductie en een correctieve femurosteotomie werden vaak gecombineerd met verschillende types bekkenosteotomies en verschillende interventies op de m.iliopsoas in de meeste gevallen. Het radiologisch resultaat van 58 heupen in 42 patiënten werd nagekeken na een gemiddelde follow-up van 5,9 jaar (gemiddeld 2,8 tot 11 jaar). Niettegenstaande bepaalde combinaties slechts zelden werden uitgevoerd, kunnen we toch enkele conclusies trekken. De resultaten waren beter wanneer een bekkenosteotomie en een interventie op de iliopsoas werden uitgevoerd. Een additionele iliopsoastransfer maakte de heup stabiel over lange periode, ten opzichte van verlenging van deze pees. Voor ernstig vervormde acetabula was de Pemberton-osteotomie superieur aan de Chiari-osteotomie. De Salter-osteotomie was een goed alternatief in gevallen met matige subluxatie. Bij bepaalde combinatieprocedures was de redislocatie 66%. Bij de combinatie van een heup

open reductie, femurosteotomie, iliopsoastransfer en een Pemberton- of Salter-osteotomie gaf een redislocatie van ongeveer 11%. Een concentrische reductie van de heup was absoluut noodzakelijk. Primair niet gecentreerde heupen verbeterden niet in het latere tijdsverloop.

RÉSUMÉ

R. BRUNNER. Quel est le traitement chirurgical qui donne les meilleurs résultats dans le traitement des luxations de hanche dans la paralysie cérébrale ?

Les auteurs ont effectué une étude rétrospective de hanches luxées ou sublaxées chez des patients présentant une paralysie cérébrale spastique, dans le but de déterminer quelle était la technique opératoire qui donnait le taux de récurrence le plus faible. Une réduction sanglante et une ostéotomie fémorale de correction ont été combinées avec différents types d'ostéotomie pelvienne et différents gestes sur le muscle psoas iliaque dans la plupart des cas. Les résultats radiologiques ont été évalués pour 58 hanches chez 42 patients, avec un recul moyen de 5,9 années (2,8 à 11,0). Bien que certaines associations de techniques chirurgicales n'aient été utilisées que dans un petit nombre de cas, les auteurs tirent cependant certaines conclusions de leur étude. Les résultats ont été meilleurs si l'on a associé une ostéotomie pelvienne et un geste sur le psoas iliaque. L'association d'un transfert du psoas iliaque a donné une meilleure stabilité à long terme que l'allongement de ce muscle. L'ostéotomie de Pemberton s'est révélée supérieure à l'ostéotomie de Chiari pour traiter des déformations acétabulaires graves. L'ostéotomie de Salter s'est avérée être une bonne technique dans les cas avec sublaxation discrète. Avec certaines associations de techniques, le taux de reluxation s'élevait jusqu'à 66%, tandis que l'association d'une réduction sanglante, d'une ostéotomie fémorale et d'un transfert du psoas iliaque et d'une ostéotomie de Pemberton ou de Salter a donné un taux de reluxation de 11% seulement. Il s'est avéré nécessaire d'obtenir une réduction concentrique des articulations. Les hanches non recentrées d'emblée ne se sont pas améliorées à plus long terme.