

LATE INFECTION AFTER TOTAL KNEE ARTHROPLASTY
CAUSED BY *PASTEURELLA MULTOCIDA*

S. A. ANTUÑA, J. G. MÉNDEZ, J. L. CASTELLANOS, J. P. JIMENEZ

The authors report a case of *Pasteurella multocida* infection in a total knee arthroplasty as a result of a dog bite. The patient was treated with one-stage reimplantation of a new prosthesis and with intravenous antibiotics, resulting in complete relief of symptoms with no evidence of recurrence of infection after 24 months.

Keywords : pasteurella ; infection ; total knee arthroplasty.

Mots-clés : pasteurella ; infection ; prothèse totale de genou.

INTRODUCTION

Late infection of total joint prostheses is an uncommon but devastating complication. Several causes of such late infection have been proposed, including delayed activation of bacteria inoculated intraoperatively, transient bacteremias secondary to dental or urogenital manipulation and hematogenous spread from a distant primary focus (1). The majority of these infections are caused by Staphylococcal and Streptococcal organisms. We report an unusual case of *Pasteurella multocida* infection of a total knee replacement secondary to a dog bite.

CASE REPORT

A 73-year-old woman with a history of severe seropositive rheumatoid arthritis underwent left total knee arthroplasty in May 1993. She had excellent knee function postoperatively until July 1994, when she presented to the emergency department complaining of intense knee pain and

functional incapability. She had had no direct trauma to the joint, but she revealed that she had been bitten on her left calf by a dog two months before. At that time she was treated with wound debridement and antibiotics for three days. She developed local swelling and erythema with regional adenopathy in the following days that resolved spontaneously in two weeks.

On physical examination, she had a temperature of 38°C with no signs of septicemia. Her left knee was warm and erythematous with a moderate tender effusion. Erythrocyte sedimentation rate (ESR) was 45 mm/h, and the white blood cell count was 13,000/mm³. Roentgenographic study of the knee showed no evidence of loosening of the implant (fig. 1). Bone scintigraphy with galium 67 was strongly positive with focal fixation of the left knee (fig 2).

The knee was aspirated and no organisms were seen on the Gram stain. Cultures of the joint fluid showed heavy growth of a pure isolate of *Pasteurella multocida*, sensitive to penicillin, ciprofloxacin and cefotaxime.

The patient was taken to the operating room for joint debridement. A small purulent collection was found medially, between the tibial component and the capsular insertion. Intraoperative gram stain revealed the presence of a Gram-negative organism. Tibial, femoral and patellar components with the remaining methylmethacrylate cement were removed, and the joint was irrigated with 4 liters of hypertonic saline. Small amounts of

Department of Orthopedic Surgery, Hospital Central de Asturias, Oviedo 33006, Asturias, Spain.

Correspondance and reprints : Samuel A. Antuña, General Elorza 77B, Oviedo 33001, Spain.

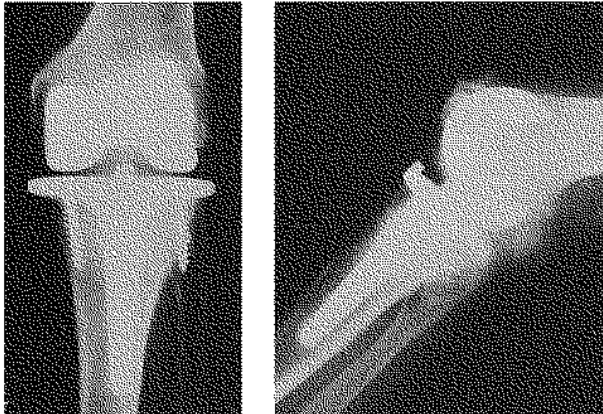


Fig. 1. — Anteroposterior (a) and lateral (b) radiographs of the infected total knee arthroplasty. No signs of loosening are present.

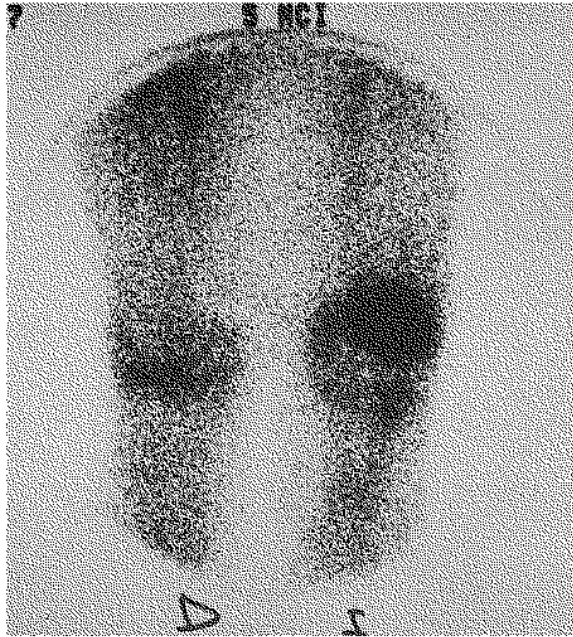

Fig. 2. — Gallium 67 bone scanning image. Intense focal uptake of the left knee can be observed.

bone were removed from the articular surfaces until bleeding was present, and new components were implanted immediately. As the patient was allergic to penicillin, a 6-week course of intravenous ciprofloxacin 750 mg every 12 hours was begun postoperatively; it was followed by intramuscular administration of the same antibiotic for 4 additional weeks.

Antibiotics were discontinued when two consecutive sedimentation rate values were within normal limits and no clinical signs of reactivation were present, as recommended by the infectious disease department. The patient has been followed in the outpatient clinic for 48 months after discharge. She has excellent knee function without pain, and there has been no evidence of prosthetic loosening or recurrence of infection.

DISCUSSION

Late infection of a knee prosthesis is one that develops more than three months after surgery. Hematogenous spread from a distal focus has been recognized as the primary pathogenic mechanism. Ainscow and Denham (1) found in a prospective study of 1000 patients with total joint replacements that transient bacteremia secondary to dental or urogenital manipulation was not likely to infect a replaced joint in a healthy patient. However, skin lesions producing secondary bacteremia might well do so in patients with increased susceptibility, such as patients with rheumatoid arthritis. The pathogenic organisms most frequently found are Staphylococci, although Gram-negative and anaerobic pathogens have also been reported (5).

Pasteurella multocida is a small, nonmotile Gram-negative coccobacillus identified and characterized by Pasteur in 1880. It is responsible for epidemic cholera in fowl and hemorrhagic septicemia in cattle and domestic animals. As a pathogen in humans, it is responsible of a wide variety of local and systemic disease. Most commonly infection follows trauma involving an animal, especially cat or dog bites or cat scratches. Local tenderness, erythema and purulent discharge are followed by regional adenopathy. In immunocompromised patients it may progress to septicemia, meningitis and septic arthritis. In reviewing the literature reporting infection of total knee prostheses by *Pasteurella multocida* we have found ten other cases (2, 3, 4, 6). Seven patients developed the infection after a cat bite or scratch, one after a dog scratch, one after licking of the surgical wound by a pet dog, and in the last one the initial focus was a foot ulcer. Our patient seems to be the first reported case after a dog bite. Several

features are common in the published cases. Seven of the ten patients had underlying rheumatoid arthritis. This condition is a well-known risk factor in patients undergoing joint replacements: 15 to 50% of patients with septic arthritis suffer from rheumatoid arthritis. As mentioned by Guion and Sculco (4), susceptibility to *Pasteurella multocida* infection in patients with rheumatoid arthritis may represent a systemic abnormality of granulocyte chemotaxis resulting in a predisposition to bacterial infection. All previously reported cases occurred in women. The higher frequency of knee arthroplasty in women and the fact that more women than men are primary caretakers of pets may be possible explanations of this finding. All cases occurred in prosthetic knees as opposed to prosthetic hips. Given that most bites or scratches occur in the distal parts of the lower extremity and that the organism tends to spread by local contiguity, it may be postulated that local defences are able to contain the infection before it reaches the hip but not the knee.

Treatment of an infected joint arthroplasty remains to some point controversial. Although early operative débridement and antibiotic administration have been advocated for acute haemogenous infections with securely fixed implants, the effectiveness when a Gram-negative organism is present has been very low (5). In this situation, removal of the implants seems to be indicated. The decision whether to perform a one- or two-stage reimplantation depends on the surgeon's criteria. We believe that one-stage reimplantation can be attempted safely when the microorganism is very sensitive to antibiotics, the infection has been detected early and the joint is not severely affected, especially if the patient has good soft tissue and bone stock.

In conclusion, the present and previously reported cases should make the surgeon aware of the importance of preventing intimate contact of patients with domestic pets; in the event of traumatic contact, prompt prophylaxis with penicillin must be considered.

REFERENCES

1. Ainscow D. A. P., Denham R. A. The risk of haemogenous infection in total joint replacements. *J. Bone Joint Surg.*, 1984, 66-B, 580-582.
2. Arvan G. D., Goldberg V. A case report of total knee arthroplasty infected by *Pasteurella multocida*. *Clin. Orthop.*, 1978, 132, 167-169.
3. Gabuzda G. M., Barnett P. R. *Pasteurella* infection in a total knee arthroplasty. *Orthop. Rev.*, 1992, 21, 601-605.
4. Guion T. L., Sculco T. P. *Pasteurella multocida* infection in total knee arthroplasty. Case report and literature review. *J. Arthroplasty*, 1992, 7, 157-160.
5. Morrey B. F., Westholm F., Schoifet S., Rand J. A., Bryan R. Long-term results of various treatment options for infected total knee arthroplasty. *Clin. Orthop.*, 1989, 248, 120-128.
6. Orton D. W., Fulcher W. H. *Pasteurella multocida*: Bilateral septic knee joint prostheses from a distant cat bite. *Ann. Emerg. Med.*, 1984, 13, 1065-1066.

SAMENVATTING

S. A. ANTUÑA, J. G. MÉNDEZ, J. L. CASTELLANOS, J. P. JIMENEZ. *Infectie van de knie ten gevolge van Pasteurella Multocida.*

De auteurs melden een geval van infectie van een totale knie-artroplastie met *Pasteurella multocida* na een hondeteet. De patiënt werd behandeld met een previsieoperatie in één tijd waarbij een nieuwe prothese werd ingeplant met intraveneus antibiotische therapie. Het resulteerde in een volledig verdwijnen van de symptomen met geen enkel argument voor infectie na 24 maanden.

RÉSUMÉ

S. A. ANTUÑA, J. G. MÉNDEZ, J. L. CASTELLANOS, J. P. JIMENEZ. *Infection du genou à Pasteurella multocida après arthroplastie prothétique.*

Les auteurs présentent un cas d'infection de prothèse totale de genou par *Pasteurella multocida* résultant d'une morsure de chien. Le patient a été traité par réimplantation immédiate d'une nouvelle prothèse et antibiothérapie intraveineuse avec guérison complète sans signe de récurrence infectieuse après 24 mois.