

# ALTERNATIVE BEARING SURFACES IN TOTAL HIP ARTHROPLASTY : ZIRCONIA-ALUMINA PAIRING. CONTRIBUTION OR CAVEAT ?

R. P. PITTO<sup>1</sup>, D. BLANQUAERT<sup>2</sup>, D. HOHMANN<sup>3</sup>

The aim of the present study was to evaluate the zirconia and alumina articulation in total hip arthroplasty in regard to clinical and radiological outcome. This is the first report concerning the clinical application of a hybrid ceramic articulation. Owing to ethical reasons, a limited number of patients was enrolled in the study.

Ten consecutive patients with degenerative arthritis were randomly allocated after informed consent to hybrid total hip arthroplasty treatment using an alumina femoral head and an alumina acetabular liner (5 hips), or using a zirconia femoral head and an alumina acetabular liner (5 hips). The median age of patients at index operation was 57.8 years. Current criteria were used for clinical and radiological assessment.

The mean follow-up was 5.1 years (5 to 5.3 years). No hip required revision, and no clinical and radiological differences were observed between the two groups of hips. The median preoperative Harris hip score was rated 55.3 points in the control group of hips with alumina head, and 55.6 in the group of hips with zirconia head. The median Harris hip score increased to 94.9 points at the time of follow-up in the control group, and 96 points in the zirconia group. No radiological signs of cup loosening or focal acetabular osteolysis were detected at follow-up. All stems showed stable fixation without radiolucent lines or focal osteolysis.

Zirconia femoral heads and alumina acetabular liners have been successfully used in the present series of 5 total hip arthroplasties with a mean follow-up of 5.1 years. Nevertheless, the use of femoral heads made of zirconia in total hip arthroplasties remains an important clinical concern due to the potential genesis of wear microparticles which can lead to progressive osteolysis. Further *in-vitro* and

*in-vivo* investigations are required to define the value of this alternative bearing surface.

---

## INTRODUCTION

Alumina and zirconia femoral heads articulating against acetabular liners made of polyethylene are currently used in total hip arthroplasty. The application is based on their excellent tribological properties (19, 23, 29). An even better tribological combination *in vitro* and *in vivo* is represented by an alumina femoral head and an alumina acetabular liner (24). On the other hand, the wear properties *in vitro* of the zirconia-zirconia combination have generally been considered to be disastrous (27, 31). An attractive alternative seems to be the mating of a zirconia femoral head with an alumina acetabular liner. An extremely low wear rate is expected when this combination is used (4). Nevertheless, the tribological performance *in vitro* and *in vivo* of the

---

<sup>1</sup> Department of Orthopaedic Surgery, University of Auckland, Middlemore Hospital, Auckland, New Zealand.

<sup>2</sup> Laboratoires Ostéal Médical, Paris, France.

<sup>3</sup> Department of Orthopaedic Surgery, Friedrich-Alexander University Erlangen-Nuremberg, Germany

Correspondence and reprints : Rocco P. Pitto, M.D., Ph.D. Associate Professor of Orthopaedic Surgery, University of Auckland, Department of Orthopaedic Surgery, Middlemore Hospital, Private Bag 93 311, Otahuhu, Auckland 6, New Zealand. E-mail : RPitto@middlemore.co.nz.

zirconia and alumina pairing remains quite controversial (9, 32). Potential genesis of wear microparticles and biodegradation products from femoral heads made of zirconia may lead to progressive osteolysis.

The aim of this study was to evaluate the zirconia and alumina pairing in total hip arthroplasty in regard to middle-term clinical and radiological outcome. To our knowledge, this is the first report concerning the *in vivo* performance of a hybrid ceramic articulation.

### MATERIALS AND METHODS

The study was approved by an institutional investigation committee, but the number of study patients was restricted to 25. The reason for this restriction was based on the controversial *in vitro* performance of zirconia and alumina pairing. Five orthopaedic centres were initially enrolled in the study, but only our unit completed the investigation. The reason for withdrawal was unrelated to the scientific topic of the study. Thus, 10 consecutive patients with unilateral degenerative arthritis were randomly assigned to elective treatment with a hybrid total hip arthroplasty using an alumina femoral head and an alumina acetabular liner (control group, alumina), or using a zirconia head and an alumina liner (study group, zirconia). Randomization was done the day of operation using random number sheets. All patients signed an informed-consent form. The median age of patients at index operation was 57.8 years (table I).

Hybrid total hip arthroplasty was performed under general anesthesia with the patient placed in the supine position. All operations were carried out by one surgeon. The hip joint was exposed through the direct lateral approach. A press-fit acetabular component (Cerafit, Céramer, Paris, France) was inserted after exposure with reamers of the subchondral bone surface. A satisfactory initial stability was obtained in all hips, and no acetabular dome screws were used to augment the quality of fixation. An alumina liner was inserted in all cups after cleaning of the shell. The femoral canal was opened using an osteotome and the medullary cavity was prepared with chip tooth broaches after the aspiration of fat and bone marrow. A bone plug was placed into the distal part of the femur and the bone surface was washed with normal saline pulsatile high-volume lavage. A vacuum-mixed standard viscosity polymethyl-methacrylate (Palacos-R, Biomet-Merck, Darmstadt, Germany) was inserted and pressurized with a cement gun (Biomet-Merck) before the insertion of the stem (Osteal, Céramer). An intramedullary teflon-tube was used to vent the femoral canal during the stem insertion. Autologous bone was placed underneath the stem collar in order to seal the femoral neck osteotomy and to avoid migration of wear debris along the interface between implant and femoral bone. In 5 hips an alumina femoral head with a diameter of 32 millimeters (Céramer) was inserted. The remaining 5 hips received a zirconia femoral head with a diameter of 32 millimeters (Céramer and Céramiques et Composites, Rhone Poulenc, France). The material composition and manufacturing procedures of the heads were different that those used by

Table I. — Data on the patients

Parameter *	Group 1 (Alumina) 5 Patients (5 hips)	Group 2 (Zirconia) 5 Patients (5 hips)
Gender (Male / Female)	M = 1, F = 4	M = 1, F = 4
Age (years)	57 (min 56, max 67)	59 (min 53 max 66)
Body-Mass Index (kg/m <sup>2</sup> )	25.1 (min 24.5, max 26.2)	24. (min 24, max 26.5)
Functional status (Charnley rating)	A= 5 hips	A= 5 hips
Level of activity (AAOS SICOT rating)		
Light labor	2	2
Moderate manual labor	3	3
Bone stock (Singh rating)		
5 (Ward triangle is empty)	1 hip	1 hip
6 (inferior Ward triangle well defined)	2 hips	1 hip
7 (normal)	2 hips	3 hips

The values are given as the median, minimum and maximum.

Benoit-Desmarquet. Zirconia femoral heads produced by this company have been recently removed from the market place because of a high rate of fractures (33). The 5 zirconia femoral heads (all medium length) used in this study had been previously matched in the laboratory with the alumina acetabular liners, in order to ensure an optimal clearance of the articulation. Postoperatively, touch weight bearing up to 15 kg was allowed over the first 2 weeks, then progressively increased loading to full weight bearing within the next 4 weeks. Patients were clinically assessed using the Harris Hip Score. Radiological evaluation of the femoral and acetabular components was performed by an independent observer using current criteria (15). Radiolucent lines were assessed according to the suggestions of Freeman (11). Location of radiolucent lines, osteolysis and cortical hypertrophy was defined according to the Gruen criteria (12). For evaluation of heterotopic ossification the Brooker classification was used (7). The quality of the cement mantle was graded based on the A-B-C<sub>1</sub>-C<sub>2</sub>-D classification of Berger *et al.* (2).

## RESULTS

Clinical and radiological follow-up was obtained in all hips. The mean follow-up was 5.1 years (5 to 5.3 years). The median preoperative Harris Hip Score was rated 55.3 points (min. 42, max. 60) in the control group of hips with alumina femoral

heads, and 55.6 points (min. 45, max 58) in the study group of hips with zirconia femoral heads. Severe preoperative pain was present in 8 hips, marked pain in 2 hips. Range of joint motion was limited to less than 110° in 9 hips, and only one patient was able to walk without a cane or crutches.

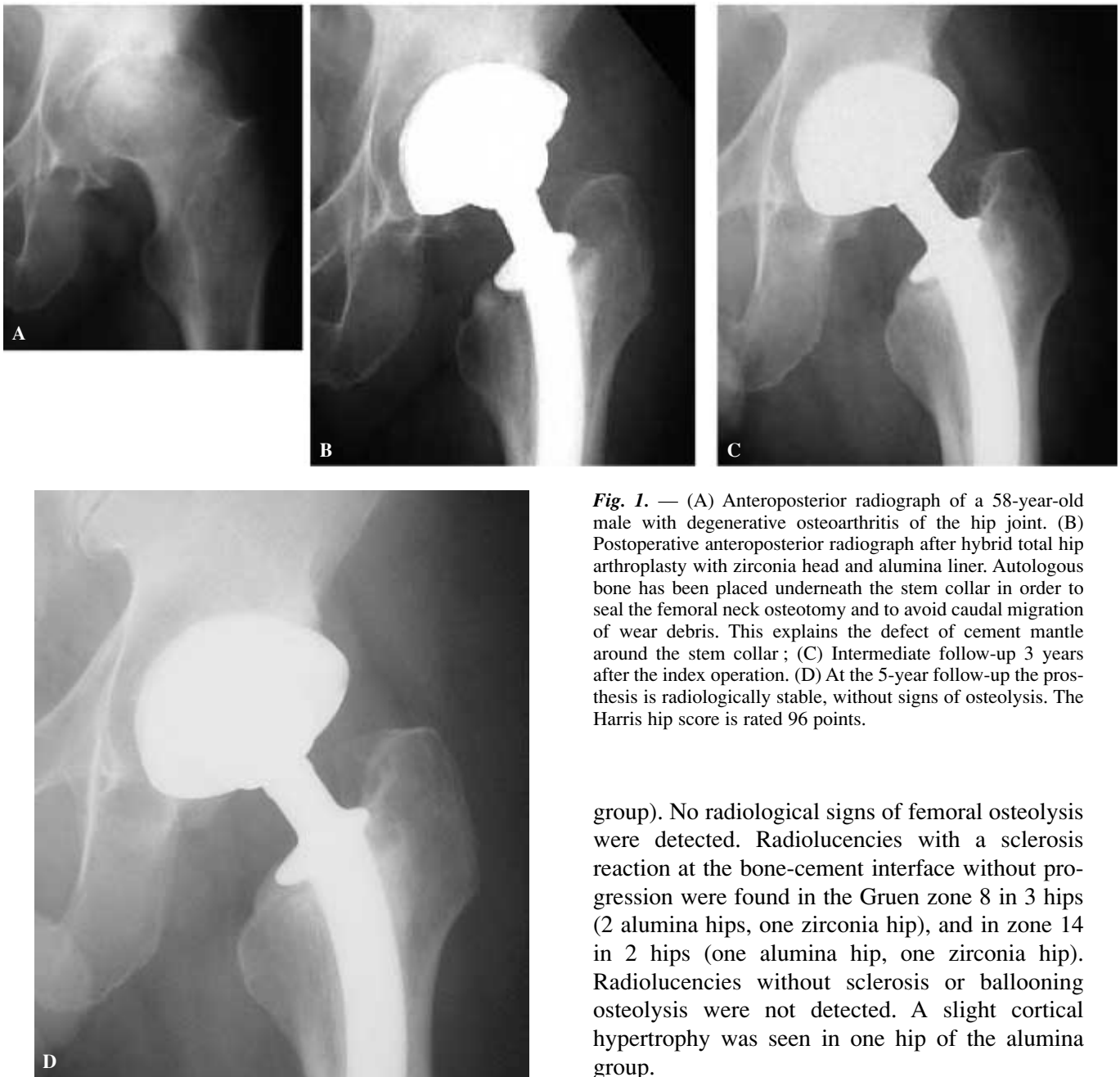
No difference in clinical results was observed between the two groups of hips at follow-up. The median Harris Hip Score had improved to 94.9 points (min. 89, max. 99 points) in the control group and had improved to 96 points (min. 90, max. 98 points) in the study group. Range of joint motion was more than 110° in all hips. All patients were able to walk without a cane or crutches. One patient in the zirconia group complained at follow-up about a sporadic audible squeak during gait and at rest. Squeaking was not reproducible during clinical investigation. Similar experience was not reported by the other patients.

No differences in radiological results were observed between the two groups of hips (Table II). All cups were considered radiologically stable with complete bone ingrowth. No radiological signs of focal osteolysis were detected at follow-up (fig. 1 and 2). Acetabular radiolucencies with a periprosthetic sclerosis reaction and without progression were found at follow-up in the DeLee-Charnley zone 3 in one hip of the alumina group

Table II. — Radiological findings

Parameter *	Group 1 (Alumina) 5 Patients (5 hips)	Group 2 (Zirconia) 5 Patients (5 hips)
Acetabular angle	38° (min. max)	36° min. max)
Stability of acetabular cup		
Bony ingrowth	5 hips	5 hips
Radiolucent lines without progression (cup)		
DeLee-Charnley	Zone 3 (one hip)	None
Bone resorption	None	None
Migration of cup	None	None
Tilting of cup	None	None
Axis of femoral stem	Neutral (± 5°)	Neutral (± 5°)
Migration of stem	None	None
Radiolucent lines without progression (stem)		
Gruen	Zone 8 (2 hips) Zone 14 (one hip)	Zone 8 (one hip) Zone 14 (one hip)
Heterotopic ossification		
Brooker	None	Brooker I (one hip)

The values are given as the median, minimum and maximum.



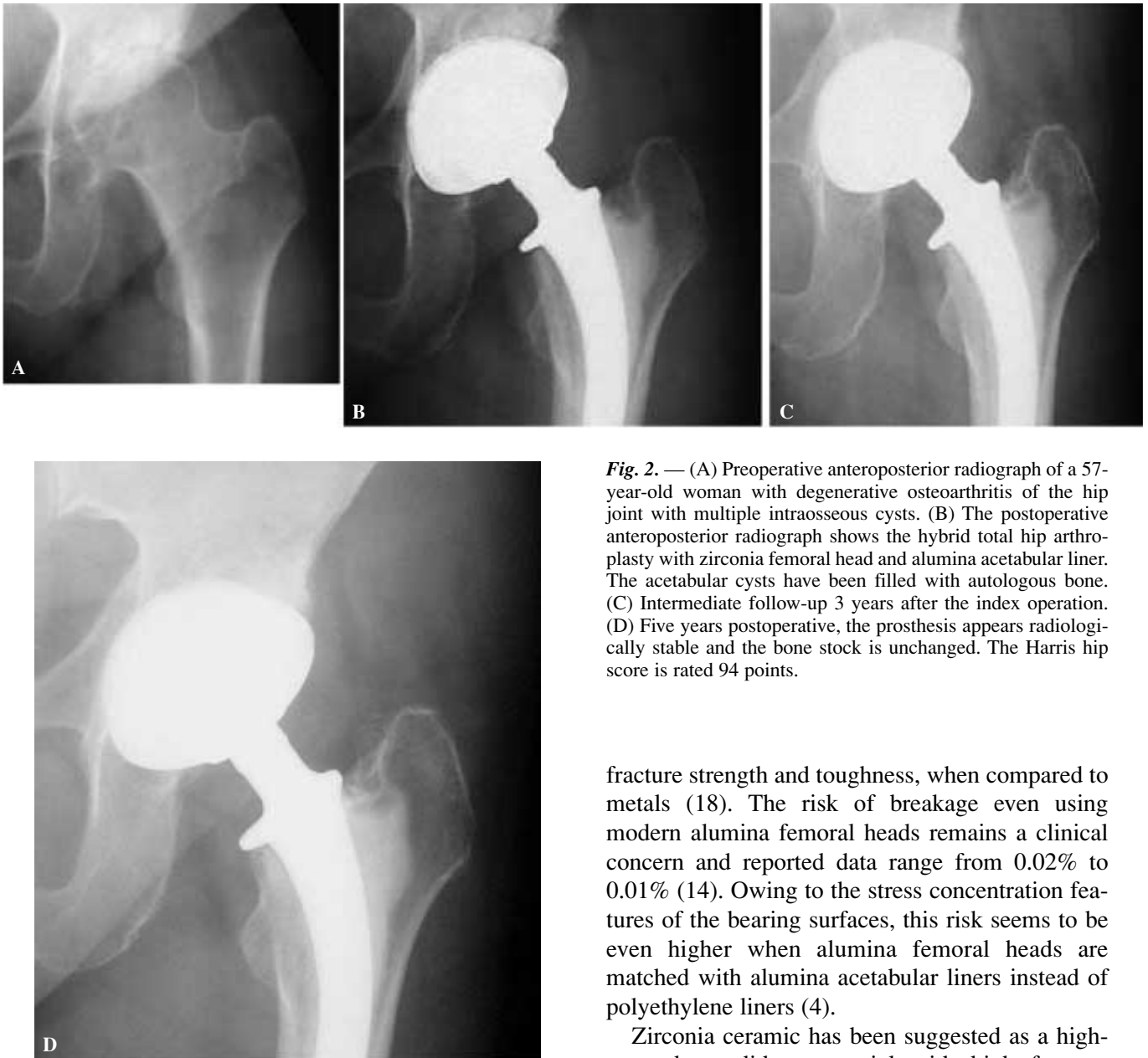
*Fig. 1.* — (A) Anteroposterior radiograph of a 58-year-old male with degenerative osteoarthritis of the hip joint. (B) Postoperative anteroposterior radiograph after hybrid total hip arthroplasty with zirconia head and alumina liner. Autologous bone has been placed underneath the stem collar in order to seal the femoral neck osteotomy and to avoid caudal migration of wear debris. This explains the defect of cement mantle around the stem collar ; (C) Intermediate follow-up 3 years after the index operation. (D) At the 5-year follow-up the prosthesis is radiologically stable, without signs of osteolysis. The Harris hip score is rated 96 points.

group). No radiological signs of femoral osteolysis were detected. Radiolucencies with a sclerosis reaction at the bone-cement interface without progression were found in the Gruen zone 8 in 3 hips (2 alumina hips, one zirconia hip), and in zone 14 in 2 hips (one alumina hip, one zirconia hip). Radiolucencies without sclerosis or ballooning osteolysis were not detected. A slight cortical hypertrophy was seen in one hip of the alumina group.

## DISCUSSION

The aim of the present study was to assess the middle-term clinical and radiological outcome of the zirconia and alumina articulation in total hip arthroplasty. To our knowledge, this is the first report concerning the clinical outcome of a hybrid ceramic pairing. The first total hip arthroplasty

No radiological signs of wear were detected using conventional measurement methods in the two groups of hips. All stems showed stable fixation at follow-up. Quality of femoral cement mantle assessed in the postoperative radiographs was rated good in all hips (8 hips grade A and 2 hips grade B). Two hips presented small voids in the cement mantle underneath the tip of the stem (zirconia



**Fig. 2.** — (A) Preoperative anteroposterior radiograph of a 57-year-old woman with degenerative osteoarthritis of the hip joint with multiple intraosseous cysts. (B) The postoperative anteroposterior radiograph shows the hybrid total hip arthroplasty with zirconia femoral head and alumina acetabular liner. The acetabular cysts have been filled with autologous bone. (C) Intermediate follow-up 3 years after the index operation. (D) Five years postoperative, the prosthesis appears radiologically stable and the bone stock is unchanged. The Harris hip score is rated 94 points.

with a zirconia femoral head and an acetabular liner was implanted in our institution in June 1996.

Total hip arthroplasty is now entering its fourth decade and a number of alternate bearing surfaces have been developed or improved for use with modern implants to enhance the wear characteristics of these devices (25, 28, 32). Alumina ceramics, even with fine microstructure and high chemical purity, remain brittle with a relatively low

fracture strength and toughness, when compared to metals (18). The risk of breakage even using modern alumina femoral heads remains a clinical concern and reported data range from 0.02% to 0.01% (14). Owing to the stress concentration features of the bearing surfaces, this risk seems to be even higher when alumina femoral heads are matched with alumina acetabular liners instead of polyethylene liners (4).

Zirconia ceramic has been suggested as a high-strength candidate material with high fracture toughness and good material resistance to abrasion (29). However, the initial *in vitro* wear studies with zirconia on zirconia articulations were not encouraging (27, 31). On the other hand, catastrophic breakdown of zirconia heads paired with alumina liners did not materialize in recent hip simulator investigations, and revealed an extremely high wear resistance. Clarke *et al.* (9) found low wear rates after 5.7 millions cycles using zirconia - alumina pairing from two different manufacturers, and

surprisingly wear was lower than with alumina - alumina pairing in the same experimental conditions. The most important limitation of this simulator investigation is a too short testing time. Rieker (22) found excellent tribological behaviours of zirconia and alumina pairing, and reported a rate of wear markedly lower than in metal on metal articulations. In this study the period of testing was limited to 3 millions cycles. Heretofore, we observed in a previous study (6) low rates of wear after 10 millions of cycles in articulations made of alumina acetabular liners and zirconia femoral heads, but in contrast, the wear was more pronounced than in articulations made of alumina acetabular liners and alumina femoral heads. Hip simulator testing was performed under the same experimental conditions, and using the same femoral head diameter.

It must be pointed out, that the value of simulator testing for investigation of wear rates remains unclear. Laboratory tests usually show wear rates of bearing surfaces lower than those observed during *in vivo* studies. Thus, laboratory simulator testing seems to be inappropriate to predict the true *in vivo* value of alternative bearing surfaces, and requires further improvement and validation of data. For instance, microseparation of the femoral head and the acetabular liner during physiological gait seems to play an important role in generating wear. Recently, Nevelos *et al.* (17) performed hip simulator studies with additional microseparation and reported rates of wear which are similar to those observed *in vivo*, demonstrating a higher predictive value, and clinically relevant information.

The sensitivity of zirconia to cristallographic phase transformation represents an important issue. The thermodynamically stable phase of zirconium oxide at room temperature is the monoclinic structure. The most commonly used biomedical grade zirconia is doped with yttrium oxide, which stabilizes zirconia in a tetragonal phase. The outstanding mechanical properties of zirconia derive from this metastable tetragonal phase. The unfavourable transformation from the tetragonal to the monoclinic phase is time dependent, and is particularly accelerated by the combination of high temperature and aqueous environment. Ageing of zirconia

femoral heads characterized by phase transformation has been described in steam autoclave, in water, and in the human body (30). Blaise *et al.* (5) recently investigated the influence of artificial ageing on the mechanical and wear properties of zirconia heads (heating ranging 60° to 134°C, during a period of time ranging from one hour to 80 days). The results of the study showed a significant slowing down of the phase transformation kinetics when zirconia heads were processed with hot isostatic pressure (HIP). Non-HIPed zirconia heads presented a monoclinic phase content of about 10% after a theoretical implantation time of 20 years, whereas HIPed heads needed 35 years to reach the same rate of monoclinic phase content. This can be explained by the higher density of the ceramic structure and the reduction of microstructural flaws such as pores. It must be pointed out that the HIP process was introduced in the mid 1990's in the manufacturing procedure of the majority of ceramic heads (14). Villermaux (30) investigated in a hip joint simulator study the wear behaviours of aged zirconia femoral heads articulated with alumina liners. The HIPed heads were artificially aged in steam autoclave, and showed a monoclinic content of 40%, corresponding to more than 50 implantation years in the human body. She found that after 5 millions cycles of testing ageing did not significantly influence the wear rate, in comparison to articulations with non-aged zirconia femoral heads. Recently, a new ceramic composite made of zirconia toughened alumina has been investigated. *In vitro* testing showed a more stable bearing surface, a marked increase in burst strength in comparison to pure alumina, with similar tribological properties (18). Recently, an increasing number of fractures of zirconia femoral heads paired with polyethylene liners has been reported (33). The cause of these events remains unclear, but the distribution and marketing of zirconia heads has been stopped worldwide.

Ceramic articulations can lead to release of wear debris in the submicrometer and micrometer range. Alumina and zirconia debris have demonstrated excellent biocompatibility in bulk form (32), but their tolerance in particulate form is still controversial. Harmand (13) and Rader (21) found some

inflammatory reaction in the presence of submicrometer zirconia wear particles *in vitro*. In contrast, submicrometer zirconia wear particles showed a lower inflammatory potential than alumina wear particles in another experimental study (20). Catelas *et al.* (8) found no difference in cell mortality rate and TNF- $\alpha$  release between alumina and zirconia particles with the same diameter of 0.6  $\mu\text{m}$ . Meunier (16) investigated the acute inflammatory potential of ceramic particles in the rat air-pouch model and found a positive correlation between the number and size of particles, and the intensity of inflammatory reaction, but he did not find any difference in intensity of inflammatory reaction when alumina or zirconia particles were used. It must be pointed out, that the *in vitro* model of the study do not necessarily represents the ideal condition to address the biotolerance of zirconia wear debris.

From the experimental point of view, there are still no grounds for optimism concerning zirconia femoral heads in total hip arthroplasty. Nevertheless, Banon (1) suggested the use of femoral heads made of zirconia and acetabular liners made of alumina in total hip arthroplasty in patients with long life expectancy and high functional demand. This suggestion is based on the results of a maximum one-month to 2-year follow-up clinical investigation of 163 hips operated on consecutively. In our opinion, further laboratory studies and cautious preclinical testing are necessary before the introduction on the market place of zirconia heads designed for articulation with an alumina acetabular liner.

In the present series no hip with a zirconia femoral head and an alumina liner required revision. All prostheses were radiologically stable, with a median Harris Hip Score of 96 points at a mean 5.1-year follow-up. Pain requiring pharmacological or physical treatment was not present in any of the patients. No signs of osteolysis were observed. Clinical and radiological results are similar to those achieved using the same prosthesis with an alumina on alumina articulation. Moreover, the findings of the present investigation do not contrast with data reported by other authors using total hip arthroplasty with hard-hard pairing (3, 19, 24, 28),

or using total hip arthroplasty with soft-hard pairing (2, 10, 23, 26).

One patient in the zirconia group complained at follow-up about a sporadic audible squeak during gait and at rest. Squeaking was not reproducible during clinical investigation. The explanation of this finding is unclear. The prosthesis appears radiologically stable and the alignment is adequate. The clinical relevance of articular squeak, which could be caused by abrasion phenomena within the joint, remains unknown in ceramic-ceramic articulations.

The most important limitation of the present study is the small number of patients. Ethical concern was raised during planning in consideration of the still controversial *in vitro* data related to the zirconia-alumina pairing. The study was initially designed as a multicentre, randomized investigation. Unfortunately, 4 of the 5 centres did not start operating, leaving only 5 hips with a relevant follow-up treated in our institution. With the number available, no attempt was made to perform statistical analysis.

In conclusion, zirconia heads and alumina acetabular liners in total hip arthroplasty have been successfully used in a limited series of patients, but little is known about the middle and long term results. The most important advantage of the zirconia and alumina combination in total hip arthroplasty seems to be the extremely low rate of wear. The potentially higher risk of fracture of the zirconia femoral heads and ageing of their structure which could lead to accelerated wear remains an important clinical concern. Further *in-vitro* investigations and randomized trials are required to define the value of this hybrid ceramic articulation.

## REFERENCES

1. Banon F. A new couple zirconia-alumina. In : Cales B. (ed). Zirconia femoral heads for total hip prostheses. Proceedings of the 6<sup>th</sup> World Biomaterials Congress, 2000, pp. 77-82.
2. Berger R. A., Kull L. R., Rosenberg A. G., Galante J. O. Hybrid total hip arthroplasty. 7- to 10-year Results. Clin. Orthop., 1996, 333, 134-146.
3. Bizot P., Larrouy M., Witvoet J. *et al.* Press-fit metal-backed alumina sockets. A minimum 5-year follow-up study. Clin. Orthop., 2000, 379, 134-142.

4. Blaise L., Villermaux F., Cales F., Evreux C. Zirkonoxyd-Aluminiumoxyd als neue Keramik-Keramik-Gleitpaarung für Hüftgelenk-endoprothesen. *Z. Orthop.*, 1999, 137 (suppl. A), 29-30.
5. Blaise L., Villermaux F., Cales F. Aging of zirconia. Everything you always wanted to know. *Bioceramics*, 2000, 13, 553-556.
6. Blankaert D. Personal communication.
7. Brooker A. E., Bowerman J. W., Robinson R. A., Riley L. H. Ectopic ossification following total hip replacement. Incidence and a method of classification. *J. Bone Joint Surg.*, 1973, 55-A, 1629-1632.
8. Catelas I., Huk O. L., Petit A., *et al.* Flow cytometric analysis of macrophage response to ceramic and polyethylene particles. Effects of size, concentration, and composition. *J. Biomed. Mater. Res.*, 1998, 41, 600-607.
9. Clarke I. C., Good V., Yamamoto K., Schröder D., Gustafson A. High wear resistance of alumina and zirconia ceramic combinations in total hip replacement wear study. In : Cales B (ed). *Zirconia femoral heads for total hip prostheses*. Proceedings of the 6<sup>th</sup> World Biomaterials Congress, 2000, pp. 5-10.
10. Coventry M. B. Lessons learned in 30 years of total hip arthroplasty. *Clin. Orthop.*, 1992, 274, 22-29.
11. Freeman M. A. R. Radiolucent lines. A question of nomenclature. *J. Arthroplasty*, 1999, 14, 1-2.
12. Gruen T. A., McNiece G. M., Amstutz H. C. Mode of failure of cemented stem-type femoral components : a radiographic analysis of loosening. *Clin. Orthop.*, 1979, 141, 17-27.
13. Harmand M. F. Biotolerance of alumina, zirconia and cobalt-chromium wear particles. In Blankaert D. (ed). *Proceedings of the Symposium on Alumina-alumina Combination. 30 years of clinical experience*. Paris, 2000, pp. 25-26.
14. Heros R., Willmann G. Ceramics in total hip arthroplasty. *Seminars in Arthroplasty*, 1998, 9, 114-122.
15. Johnston R. C., Fitzgerald R. H., Harris W. H., Poss R., Müller M. E., Sledge C. B. Clinical and radiological evaluation of total hip replacement. *J. Bone Joint Surg.*, 72-A, 1025-1034.
16. Meunier A. Acute inflammatory potential of ceramic particles in the rat air-pouch model. In : Cales B. (ed). *Zirconia femoral heads for total hip prostheses*. Proceedings of the 6<sup>th</sup> World Biomaterials Congress, 2000, pp. 55-65.
17. Nevelos J., Ingham E., Doyle C., Nevelos A., Walter W., Fischer J. Micro-separation of the centres of alumina-alumina artificial joints during simulator testing produces clinically relevant wear rates and patterns. *Proceedings of the 6<sup>th</sup> World Congress of Biomaterials*, 2000, pp. 861-862.
18. Pfaff H. G., Rack R. A new material concept for bioceramics in orthopaedics. In Willmann G. and Zweymüller K. (eds). *Bioceramics in hip joint replacement*. Stuttgart, New York, Thieme Verlag 2000, pp. 136-140.
19. Pitto R. P., Schwämmlein D., Schramm M. Modular press-fit acetabular components in total hip arthroplasty. In Willmann G. and Zweymüller K. (eds). *Bioceramics in hip joint replacement*. Stuttgart, New York, Thieme Verlag 2000, pp. 19-25.
20. Prudhommeaux F., Meunier A., Villermaux F., Doyle C., Sedel L. Acute inflammatory potential of ceramic particles in the rat air-pouch model. In : Cales B. (ed). *Zirconia femoral heads for total hip prostheses*. Proceedings of the 6<sup>th</sup> World Biomaterials Congress, 2000, pp. 35-39.
21. Rader M. Biotolerance of alumina, zirconia and cobalt-chromium wear particles. In Blankaert D. (ed). *Proceedings of the Symposium on Alumina-alumina Combination. 30 years of clinical experience*. Paris, 2000, pp. 29-30.
22. Rieker C. Comparison of two hard-hard bearing systems on a hip simulator. In : Cales B. (ed). *Zirconia femoral heads for total hip prostheses*. Proceedings of the 6<sup>th</sup> World Biomaterials Congress, 2000, pp. 40-48.
23. Schramm M., Keck F., Hohmann D., Pitto R. P. Total hip arthroplasty using an uncemented femoral component with taper design : outcome at 10-year follow-up. *Arch. Orthop. Trauma Surg.* 2000, 120, 407-412.
24. Sedel L., Nizard R. S., Kerboul L., Witvoet J. Alumina-alumina hip replacement in patients younger than 50 years old. *Clin. Orthop.*, 1994, 298, 175-183.
25. Sedel L. Evolution of alumina-on-alumina implants. A review. *Clin. Orthop.*, 2000, 379, 48-54.
26. Stringa G., Di Muria G. V., Marcucci M., Pitto R. P. Long term results of Charnley low-friction arthroplasty : A 13-year average follow-up study. *Hip International*, 1, 21-25, 1991.
27. Tucci A., Esposito L. Microstructure and tribological properties of zirconia ceramics. *Wear*, 1994, 172, 111-119.
28. Weber B. G. Pressurized cement fixation in total hip arthroplasty. *Clin. Orthop.*, 1998, 232, 87-95.
29. Villermaux F. Reliability of zirconia hip joint heads. In : Cales B. (ed). *Zirconia femoral heads for total hip prostheses*. Proceedings of the 6<sup>th</sup> World Biomaterials Congress, 2000, pp 59-63.
30. Villermaux F. Zirconia-alumina coupling. Aging of zirconia should be kept out of mind. *Bioceramics*, 2000, 13 :537-540.
31. Willmann G., Früh H. J., Pfaff H. G. Wear characteristics of sliding pairs of zirconia for hip endoprosthesis. *Biomaterials*, 1996, 17, 2157-2162.
32. Willmann G. The evolution of ceramics in total hip arthroplasty. *Hip International*, 2000, 10, 193-203.
33. www.NDFC.saint-gobain.com.

#### SAMENVATTING

*R. P. PITTO, D. BLANQUAERT, D. HOHMANN. Het gebruik van aluminium en zirconium als contact oppervlakte bij totale heuparthroplastie.*



Beperkte klinische en radiologische studie van zirconium en aluminium als geleidingsoppervlak bij totale heuparthroplastiek. Om ethische redenen is het aantal in deze studie betrokken patiënten beperkt. Het gaat om de eerste publicatie omtrent deze hybride keramische combinatie. Tien willekeurig gekozen en degelijk ingelichte patiënten stemden toe tot een hybride heuparthroplastie met ofwel een aluminium heupkop en een aluminium acetabulum bekleding (5 heupen), ofwel een zirconium heupkop en een aluminium acetabulum (5 heupen). De gemiddelde leeftijd op het ogenblik van de ingreep bedroeg 57,8 jaar.

De klinische en radiologische evaluatie gebeurde volgens de gebruikelijke criteria. De gemiddelde follow-up bedroeg 5,1 jaar (5 tot 5,3 jaar). Geen enkele heup diende gereviseerd. Er was geen klinisch of radiologisch verschil tussen beide groepen. De gemiddelde preoperatieve Harris score bedroeg 55,3 en 55,6 respectievelijk bij de aluminium kop en de zirconium kop. Postoperatief steeg de Harris score bij follow-up respectievelijk tot 94,9 en 96. Radiografische beelden bij controle onderzoek brachten geen tekens aan het licht van cuploslating of acetabulaire focale osteolysis. De schaftfixatie bleek stabiel en er waren evenmin tekens van radioluentie of focale osteolysis rond de stem.

Een zirconium heupkop gecombineerd met een aluminium dakbekleding is in deze studie, met een gemiddelde opvolging van 5,1 jaar, 5 maal met succes gebruikt. Dit belet niet dat vrees blijft bestaan voor progressieve osteolysis door deeltjes slijtage bij heupkoppen uit zirconium. Doorzetting van in-vitro en in-vivo studies moet de termijn waarde bepalen van deze alternatieve bekledingsmaterialen.

### RÉSUMÉ

*R. P. PITTO, D. BLANQUAERT, D. HOHMANN. Le couple de frottement zircone-alumine dans l'arthroplastie totale de hanche.*

Cette étude avait pour but d'évaluer le couple de frottement zircone-alumine dans l'arthroplastie totale de hanche sur les plans clinique et radiologique. Aucun résultat clinique n'avait été publié à ce jour concernant ce couple céramique hybride. Pour des raisons éthiques, cette étude a porté sur un nombre restreint de patients. Dix patients successifs présentant une coxarthrose ont été répartis de façon aléatoire, après avoir donné leur consentement éclairé, entre deux groupes : dans le premier (5 hanches), le couple de friction associait une tête fémorale en alumine et un insert acétabulaire en alumine, dans le second (5 hanches), il associait une tête fémorale en zircone et un insert acétabulaire en alumine. L'âge médian des patients était de 57,8 ans. L'évaluation clinique et radiologique s'est faite sur base de critères classiques.

Le suivi moyen était de 5,1 ans (5 à 5,3 ans). Aucune hanche n'a dû être réopérée ; aucune différence n'a été observée entre les deux groupes sur le plan clinique ou radiologique. Le score de Harris préopératoire était de 55,3 points dans le groupe recevant une tête en alumine, et de 55,6 points dans le groupe recevant une tête en zircone. Le score de Harris médian était de 94,9 points au suivi dans le groupe témoin et de 96 points dans le groupe zircone. Les radiographies n'ont montré aucun signe de descellement de la cupule ou d'ostéolyse focale au niveau du cotyle. Les tiges montraient toutes une fixation stable sans ligne radiotransparente et sans ostéolyse focale.

Dans cette série de 5 arthroplasties totales de hanche, avec un suivi moyen de 5,1 ans, on a utilisé avec succès un couple de friction associant une tête fémorale en zircone et un insert acétabulaire en alumine. Cependant, l'utilisation de têtes en zircone dans l'arthroplastie totale de hanche reste un sujet de préoccupation en clinique, en raison du risque théorique de production de micro-particules d'usure à l'origine d'une ostéolyse évolutive. D'autres recherches in vitro et in vivo sont nécessaires pour définir l'intérêt de ce couple de frottement.