

AN UNUSUAL TRIGGER FINGER

T. PAMPLIEGA, A. J. ARENAS

A case of trigger finger due to a lipoma of the tendon sheath at the wrist is presented. Lipoma of the tendon sheath is a very rare tumor. In the case reported, the symptoms disappeared after surgical treatment.

Keywords : trigger finger ; lipoma ; tendon sheath.
Mots-clés : doigt à ressaut ; lipome ; gaine synoviale.

INTRODUCTION

Few cases of tumors causing trigger finger have been published. We present a case of trigger finger caused by a lipoma of the tendon sheath. Lipoma of the tendon sheath is a very rare tumor, which is more likely to appear in the upper limb than in the lower limb and is also more frequent in the extensor tendons than in the flexor tendons (5).

CASE REPORT

A 16-year-old girl complained that she could not fully stretch out her left-hand middle finger after she bent it. On attempting to extend it, she heard it snap and felt pain in the anterior aspect of the wrist. When the transverse carpal ligament was divided, we observed a uniform enlargement of the tendon sheath located on the superficial flexor tendons of the second and third fingers, which was removed. The pathological study disclosed an endovaginal lipoma (3) (fig. 1).

Eighteen months later the patient complained of pain in the most proximal area of the scar when she bent her fingers and wrist. Surgery was performed on the grounds of a possible tumoral recurrence. A mass of scar tissue, the size of a small chickpea (fig. 2), was observed on the superficial flexor tendons of the index and long fingers.

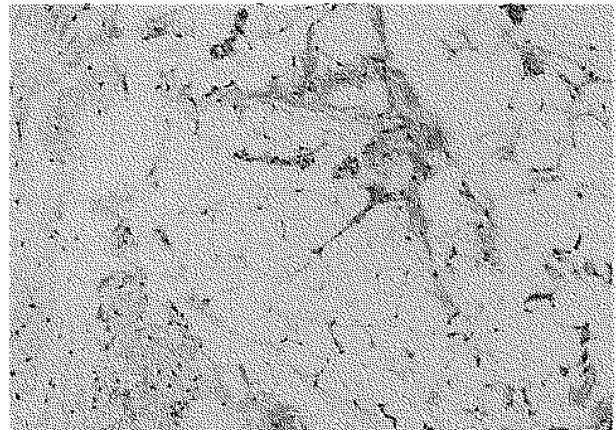


Fig. 1. --- Characteristic aspect of mature fibrofatty tissue lined by synovium (H-E, $\times 100$).

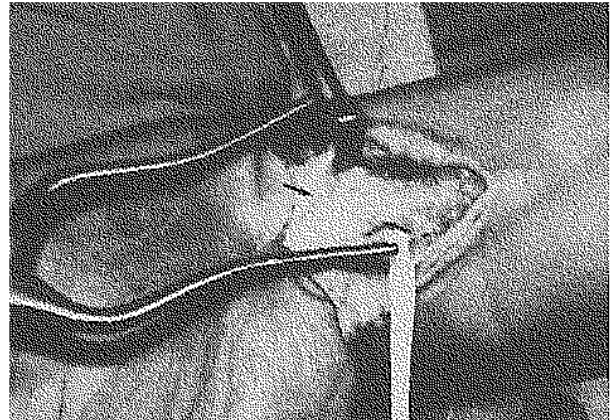


Fig. 2. — Fibrous scar hampering proper tendinous sliding.

Department of Orthopedic Surgery, "Reina Sofía" Hospital, Tudela-31500, Navarra, Spain.

Correspondence and reprints : T. Pampliega, c/ Ronda San Cristobal, 136, Urbanización Cizur Mayor-31180, Navarra, Spain.

A catheter was placed over the operated area through which 5 ml of 0.125% Bupivacaine were administered 30 minutes before each physiotherapy session, to allow active physiotherapy and prevent recurrent adhesions (2).

DISCUSSION

Trigger finger caused by tumors is not only quite rare (4), but it hardly ever requires further surgery. In spite of the tumors being located at the wrist, locking occurred when the patient bent her fingers ; therefore we cannot talk about trigger wrist as Aghasi *et al.* do (1).

REFERENCES

1. Aghasi M. K., Rzetelny V., Axer A. The flexor digitorum superficialis as a cause of bilateral carpal-tunnel syndrome and trigger wrist. A case report. *J. Bone Joint Surg.*, 1980, 62-A, 134-135.
2. Braun C., Henneberger G., Racenberg E. Technique du bloc continu des nerfs au niveau du poignet. *Ann. Chir. Main*, 1992, 11, 141-145.
3. Enzinger F. M., Weiss S. W. *Soft tissue tumors*. 2nd ed. The CV Mosby Co, St. Louis. 1988, pp. 327-331.
4. Stockley I., Norris S. H. Trigger finger secondary to soft tissue chondroma. *J. Hand Surg.*, 1990, 15-B, 468-469.
5. Sullivan C. R., Dahlin D. C., Bryan R. S. Lipoma of the tendon sheath. *J. Bone Joint Surg.*, 1956, 38-A, 1275-1280.

SAMENVATTING

T. PAMPLIEGA, A. J. ARENAS. Ongewone springvinger.

De auteurs rapporteren een geval van springvinger veroorzaakt door een lipoma van de peesschede aan de pols. Het lipoma van de peesschede is een zeldzaam letsel. In dit geval werd de verwijdering gevolgd door een volledige genezing.

RÉSUMÉ

T. PAMPLIEGA, A. J. ARENAS. Doigt à ressaut inhabituel.

Les auteurs présentent le cas d'une jeune fille qui présentait un doigt à ressaut provoqué par un lipome de la gaine synoviale au poignet. C'est une tumeur peu fréquente des gaines synoviales. L'ablation de la tumeur fut suivie de guérison.