

THE CONTROVERSY OF THE BIOMECHANICS OF THE TRIANGULAR FIBROCARILAGE COMPLEX : A MATHEMATICAL MODEL TO CLARIFY THE PROBLEM

L. DE SMET, G. FABRY

In the recent literature a controversy exists about the tension in the distal radioulnar ligaments during pronation and supination. A mathematical model supports the theory of Schuind and coworkers and indicates that the palmar distal radioulnar ligament is taut in supination.

Keywords : triangular fibrocartilage complex ; biomechanics.

Mots-clés : ligament triangulaire fibrocartilagineux ; biomécanique.

INTRODUCTION

Rotation of the forearm is a complex movement involving two articulations and the intraosseous membrane. For a long time a fixed axis was postulated (4).

Rotation of the radius around the ulna is also accompanied by a translation of the ulna in supination to the palmar side, and in pronation towards the dorsal side. There is no simple center of rotation, but the different rotation centers follow a strict pathway, a centrod (5).

The stability of the distal ulna is largely provided by the Triangular fibrocartilage complex (TFCC). The dorsal and palmar distal radioulnar ligaments (DRU) are the main structures involved. A controversy exists about which of these ligaments is tight during which part of the rotation.

For af Ekenstam and Hagert (3) and Bowers (2) the dorsal DRU ligament is taut in supination and palmar in pronation. In the work of Kuhlman and Vinh (6) the opposite was mentioned. Linscheid (7), Schuind *et al.* (8) and the recent

publication of Acosta *et al.* (1) confirmed the latter hypothesis.

We constructed a mathematical model in order to clarify this dilemma.

METHOD

In fig. 1 the rotation of the radius around the ulna of the left forearm seen in a distal-proximal direction is drawn.

During supination displacement of the radius goes from position 1 to position 2. The dorsal and palmar DRU ligaments have their insertion on the styloid. The

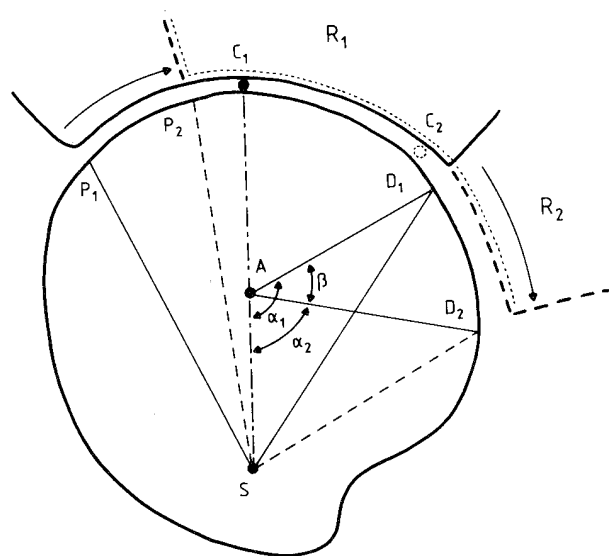


Fig. 1.

Department of Orthopedic Surgery, U.Z. Pellenberg, Katholieke Universiteit Leuven, Belgium.

Correspondence and reprints : L. De Smet.

axis of rotation (A) is localized anteriorly and radially to the styloid process (S). With limited rotations (26°) the axis remains fixed and the distal radioulnar ligaments remain straight (6).

Since both bones form a rigid system with minimal translation, during rotation the distance from A to each point of the radius remains constant (otherwise A cannot be the axis). The point P is the radial insertion of the palmar DRU joint, and D the radial insertion of the dorsal DRU ligament. In supination P moves from P₁ to P₂, and D from D₁ to D₂. This is seen in fig. 2. The point C is a contact point in the radioulnar joint, randomly located between P and D. The triangle SAD₁ changes to SAD₂ during supination. This distance SA is in common, and the distance AD₁ equals the distance AD₂. The length changes over the distance SD₁ to SD₂ (or the dorsal DRU ligament); it depends on the change of the angle α (from α₁ to α₂) and can be calculated according to the formula :

$$SD = \sqrt{(AD)^2 + (AS)^2 - 2(AD)(AS) \cos \alpha}$$

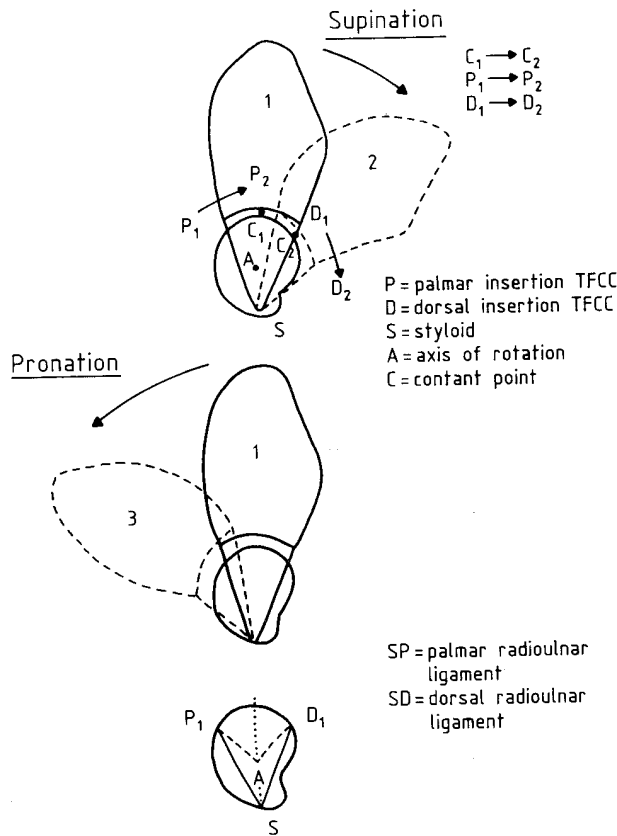


Fig. 2.

When α₁ decreases during supination (α₁ > α₂), the value of cos α increases and SD decreases. This means that during supination the distance SD decreases and the dorsal DRU ligament relaxes.

A similar calculation can be performed for the distance SP, which increases during supination, tightening the palmar DRU ligament. The reverse is true during pronation.

DISCUSSION

This mathematical model supports the hypothesis of Schuind *et al.* (8), Linscheid (7), and Acosta *et al.* (1) : during pronation the posterior DRU ligaments become taut. This is contrary to the findings of af Ekenstam and Hagert (3).

The contradiction in the conclusion of af Ekenstam and Hagert and the others is probably caused by their different experimental approach. Af Ekenstam and Hagert assessed the stability of the distal radioulnar joint (DRU) after sectioning one of the radioulnar ligaments. After the palmar DRU ligament was severed, the DRUJ was stable only in supination. They concluded that the dorsal DRU ligament was essential for stability during supination.

The other studies were done on intact ligaments during controlled passive rotation. From normal motion to the extreme positions where frank dislocations occur, the tension pattern may change (8).

LITERATURE

1. Acosta R., Hnat W., Schecker L. Distal radioulnar ligament motion during supination and pronation. *J. Hand Surg.*, 1993, 18-B, 502-505.
2. Bowers W. H. Distal radioulnar joint arthroplasty : Current Concepts. *Clin. Orthop.*, 1992, 275, 104-109.
3. Af Ekenstam, Hagert C. Anatomical studies on the geometry and stability of the distal radioulnar joint. *Scand. J. Plast. Reconstr. Surg. Hand.*, 1985, 19, 17-25.
4. Kapandji I. A. La radiocubitale inférieure vue sous l'angle de la pronosupination. *Ann. Chir.*, 1977, 31, 1031-1039.
5. King G. J., McMurty R. Y., Rubenstein J. D., Gertzbein S. D. Kinematics of the distal radioulnar joint. *J. Hand Surg.*, 1986, 11-A, 798-804.
6. Kuhlman J. N., Vinh T., Guerin-Surville. Le ligament triangulaire et la partie médiale du poignet. *Bull. Ass. Anat.*, 1985, 69, 305-314.
7. Linscheid D. Biomechanics of the distal radioulnar joint. *Clin. Orthop.*, 1992, 275, 46-55.

8. Schuind F., An K. N., Berglund L., Rey R., Cooney W. P., Linscheid R. L., Chao E. Y. S. The distal radioulnar ligament : a biomechanical study. *J. Hand Surg.*, 1991, 16-A, 1106-14.

SAMENVATTING

L. DE SMET, G. FABRY. De tegenstelling in ligamentspanning tijdens onderarmrotaties : een wiskundig model.

In de recente literatuur bestaat er een tegenstelling over welk distaal radioulnair ligament aangespannen is tijdens welk deel van de pronosupinatie.

Met een wiskundig model kan worden aangetoond dat het palmair distaal radioulnair ligament onder tensie komt tijdens de supinatie en vice versa.

RÉSUMÉ

L. DE SMET, G. FABRY. La controverse à propos de la biomécanique du ligament triangulaire du carpe. Essai de classification à l'aide d'un modèle mathématique.

La littérature fait état de constatations contradictoires en ce qui concerne la tension des deux ligaments radio-ulnaires distaux au cours de la pronosupination.

Un modèle mathématique démontre que c'est le faisceau dorsal qui se détend en supination.

La même formule permet d'établir qu'il se tend en pronation et que le faisceau palmaire se tend en supination et se détend pendant la pronation de l'avant bras.