

# SAGITTAL PLANE CORRECTION IN "KING-CLASSIFIED" IDIOPATHIC SCOLIOSIS PATIENTS TREATED WITH COTREL-DUBOUSSET INSTRUMENTATION

H. HALM, W. H. M. CASTRO, J. JEROSCH, W. WINKELMANN

**Introduction and aim of the study :** Whereas Harrington instrumentation (HI) has demonstrated satisfactory frontal plane correction, sagittal plane realignment is difficult. Sagittal plane control is reported to be easier with Cotrel-Dubousset instrumentation (CDI). This study was undertaken to determine if in our series sagittal realignment was achieved with CDI in idiopathic curves classified according to King.

**Material and methods :** Ninety-seven patients with idiopathic scoliosis classified according to King and treated with CDI underwent coronal and sagittal plane analysis by an unbiased observer. The sagittal curves were measured with the Cobb method from T4-T12 (normals : +25 to +40°) and L1-L5 (normals : -40 to -55°). The thoracolumbar junction (TJ) was divided into an upper TJ (T10-T12) and a lower TJ (T12-L2) with normals between 0 and +10° for the former and 0 and -10° for the latter.

**Results :** In all types of scoliosis with associated thoracic hypokyphosis a significant realignment could be achieved, ranging from 8° in King 1 and 3 curves to 19° in King 4 curves. In normokyphotic curves no significant changes of the thoracic spine were measured postoperatively. Concerning the upper TJ, pathological lordosis was corrected by 7° on the average, whereas correction of kyphosis ranged from 8 to 18° Cobb. Pathologic kyphosis and hyperlordosis of the lower TJ showed a mean correction of 7° and 11°, respectively. There was no significant direct influence of CDI on the sagittal plane of the lumbar spine.

**Conclusion :** The data from this study suggest that correction in the sagittal plane can be achieved with CDI in King-classified scoliotic deformities.

**Keywords :** scoliosis ; Cotrel-Dubousset instrumentation ; sagittal plane.

**Mots-clés :** scoliose ; instrumentation Cotrel-Dubousset ; plan frontal.

## INTRODUCTION

Harrington instrumentation has demonstrated good results in correcting coronal plane deformities, but the distractive forces applied could not normalize the sagittal plane deformities often associated, especially thoracic hypokyphosis and junctional kyphosis (3). In order to maintain sagittal balance, lumbar hypolordosis occurs secondarily in patients with thoracic flat back. This, together with a long lever arm above a few unfused lumbar segments may contribute to a higher incidence of flat back syndrome postoperatively. Cochran has shown that patients with idiopathic scoliosis fused to L3 or lower have an increasing rate of low back pain (4). Reports on Luque instrumentation have shown sagittal realignment as good as with Harrington instrumentation plus sublaminar wiring, but the percentage of neurological complications seems to be significantly higher using wires (6).

This study was undertaken to evaluate whether in our series sagittal realignment could be achieved with CDI in idiopathic scoliosis with a major right convex thoracic curve alone or with an additional major or compensatory curve, as classified by King (7).

## MATERIAL AND METHODS

The radiographs of 97 patients with a major idiopathic right convex thoracic curve with or without an

---

Orthopedic Department Westfälische Wilhelms-University Münster, Albert Schweitzer Straße 33, D-4400 Münster, Germany.

Correspondence and reprints : H. Halm.

associated second primary or secondary curve (King-1 to King-5) treated with CDI were analyzed. The preoperative coronal deformities measured  $38^{\circ}$  to  $105^{\circ}$  Cobb angle. Seven patients had King-1 scoliosis, 36 King-2, 28 King-3, 8 patients King-4 and 18 patients King-5 curves. All patients underwent standing frontal and sagittal plane analysis on long cassette PA and lateral radiographs pre- and postoperatively by an unbiased observer. Preoperative bending films were analyzed too. The type of scoliosis was determined according to the classification of King *et al.* (7). By measuring the sagittal plane, angles were obtained for the thoracic spine from T4 to T12 and the lumbar spine from L1 to L5. The measurement of the thoracic and lumbar sagittal plane was simplified due to the fact that in most types of King-classified scoliosis the vertebrae used are normally almost neutrally rotated (3). According to Bernhardt *et al.* the thoracolumbar junction was divided into an upper part, measured from T10 to T12 and a lower part from T12 to L2 (1). Normal sagittal angles were established. Thoracic kyphosis was considered as normal from  $+25^{\circ}$  to  $+40^{\circ}$  Cobb angle, the upper thoracolumbar junction should measure from  $0$  to  $+10^{\circ}$ , the lower thoracolumbar junction from  $0$  to  $-10^{\circ}$  and the lumbar lordosis from  $-35$  to  $-55^{\circ}$  Cobb angle. All patients were instrumented at least to T12. The majority of patients were treated with a two-rod technique. In 4 patients with a severe curve, a three-rod technique was used. In half of the King-5 curve patients, two rods were used in the concavity to treat each curve alone. According to Shufflebarger (11) a reversal of hooks and a reverse rod bend was used at the thoracolumbar junction in 25 patients with a King-2 curve and in 6 patients with a King-3 curve to either treat an associated junctional kyphosis or avoid spinal decompensation. Statistical analysis was performed with the Student t-test ( $p < 0.05$ ). The mean follow-up was 3 plus 2 years with a range from 1 plus 6 years to 5 plus 2 years.

## RESULTS

### Sagittal thoracic plane

In all types of scoliosis with associated thoracic hypokyphosis ( $n = 53$ ) moderate to excellent realignment was achieved, ranging from a mean correction of  $+8^{\circ}$  in King-1 and King-3 curves to a mean correction of  $+19^{\circ}$  in King-4 curves. King-2 curves had a mean correction of  $+11^{\circ}$ , King-5 curves of  $+9^{\circ}$  Cobb angle. The best re-

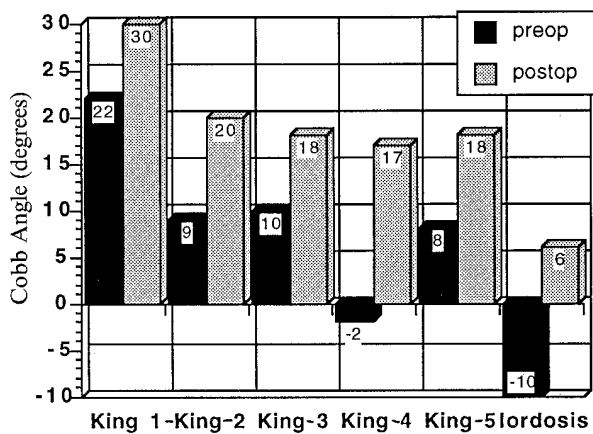
sults were obtained in King-4 curves, where in every case a correction of at least  $+13^{\circ}$  could be obtained. Twenty-four of the 53 patients with a thoracic hypokyphosis finished up with a normal thoracic sagittal plane; in these 24 the mean correction was  $+16^{\circ}$  Cobb angle. Excellent results were obtained in patients with a thoracic lordosis ( $n = 9$ ). In these cases a mean correction of  $+17^{\circ}$  with a maximum of  $+27^{\circ}$  was obtained, although due to the severe sagittal deformity a normal profile of more than  $+25^{\circ}$  Cobb angle could not be achieved in any of these patients. However, there was no statistically significant difference between the groups. The explanation why King-4 curves had the best results is that these were the ones with the most severe hypokyphosis (lordosis).

With correction of the hypokyphosis, lumbar lordosis was normally enhanced secondarily, although due to the wide range of "normals" lordosis was within normal ranges pre- and postoperatively. A significant loss of kyphosis was only noted in two patients, one King-3 and one King-5 deformity. A critical analysis suggests that the rod bending prior to the derotation maneuver was insufficient, so that after the  $90^{\circ}$  rotation of the rod the patients ended up with a visibly flattened thoracic spine.

All patients with a preoperatively normal thoracic kyphosis remained within normal ranges (fig. 1).

Preoperatively hyperkyphotic thoracic curves were rare: they were only seen in 14 cases. No such curve was seen in King-1 scoliosis. Six of seven King-2 curves, all King-3 and King-4 curves and one of two King-5 curves had a substantial correction with a loss of hyperkyphosis of at least  $-8^{\circ}$  and a maximum of  $-24^{\circ}$ . Four of the 14 patients had a normokyphotic thoracic spine postoperatively.

The single King-5 curve with a slight thoracic hyperkyphosis of  $+50^{\circ}$  was not changed at all with CDI. The single King-2 curve had a notable enhancement of hyperkyphosis of  $+13^{\circ}$ . In this patient the right convex thoracic scoliotic curve was severe and measured  $85^{\circ}$ . The two-rod technique was used, and the concave rod had to be sharply bent in order to perform the derotation maneuver, which after the  $90^{\circ}$  rotation of the rod enhanced the thoracic hyperkyphosis. Retrospec-

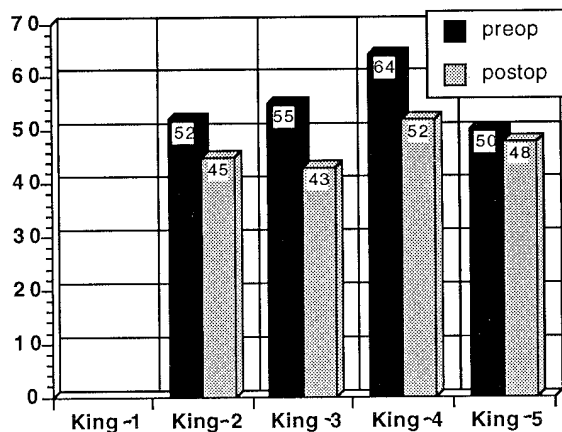


**Fig. 1.** — Mean correction of thoracic hypokyphosis in relation to the type of scoliosis. This is a good correction of preoperatively lordotic thoracic spines and King-4 curves, although the latter represents a small group.

tively it might have been better to have used the 3-rod technique with an initial short rod in the concavity. A relationship between the flexibility of the curves on the side bending films and correction of sagittal planes could not be found (fig. 2).

**Upper thoracolumbar junction**

The influence of CDI on the upper thoracolumbar junction could be analyzed in all cases, because all were instrumented at least to T12. The



**Fig. 2.** — Mean correction of the rare cases of thoracic hyperkyphosis for each type of scoliosis mentioned.

pathologic lordotic junctions accounted for 20 cases and were usually corrected in all types of scoliosis with a mean correction between +6° in King-5 curves and +12° in King-4 curves. No enhancement of pathologic lordosis was seen in any of the patients.

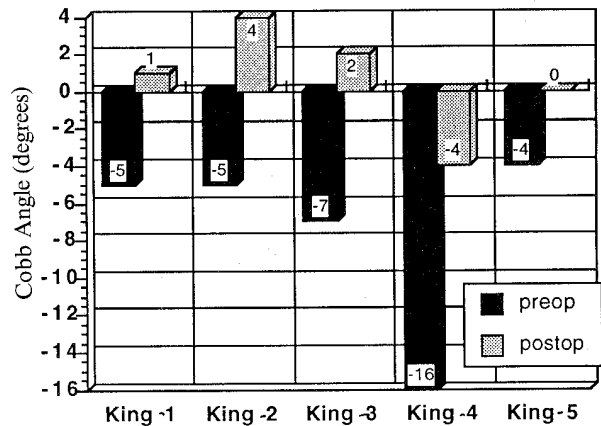
The patients with preoperatively normal junctions (n = 47) remained within normal ranges of 0 to +10° Cobb angle.

Not surprisingly King-2 scoliotic curves accounted for most of the 30 patients with a pathological upper thoracolumbar junctional kyphosis of more than +10° Cobb angle. All of these kyphotic junctions except two without any changes showed a tendency to lordosis of at least -7° and a maximum of -18° Cobb angle.

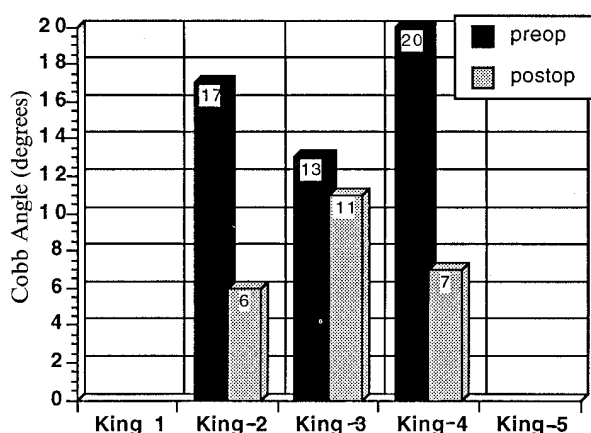
Two-thirds of the either pathologically lordotic or kyphotic upper thoracolumbar junctions were within normal limits postoperatively due to the correcting forces (figs. 3, 4).

**Lower thoracolumbar junction**

The influence of CDI on the lower junction was analyzed in 79 patients, because in the others the instrumentation ended above L2, and therefore these were excluded from this part of the study. An excellent overall correction of all types of scoliosis was seen concerning hyperlordotic junctions of more than -10° Cobb angle. King-3 and King-4 curves (n = 5) accounted for the best



**Fig. 3.** — Mean correction of hyperlordotic upper thoracolumbar junctions in relation to the type of scoliosis. No enhancement of pathologic lordosis was seen in any patient.

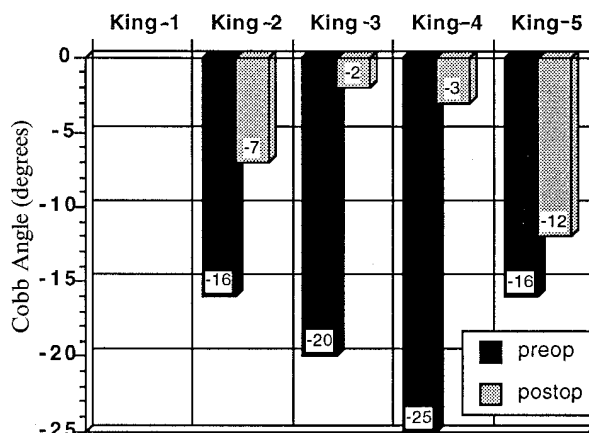


**Fig. 4.** — Mean correction of hyperkyphotic upper thoracolumbar junctions. Most of these were seen in King-2 curves with good realignment.

results with a mean correction of  $+19^\circ$ . In no patients an impairment was seen. All except one of the hyperlordotic junctions were within physiological ranges postoperatively. In all except 2 patients (King-4, slight kyphosis, no changes) a good correction of a junctional kyphosis was obtained with a mean correction from  $-8^\circ$  in King-3 and King-5 curves to  $-11^\circ$  and  $-12^\circ$  in King-1 and King-2 curves. Due to this, half of the patients were corrected to a normal junctional profile. All patients with a junctional kyphosis treated with a reverse rod bend and reversal of hooks had a correction of at least  $-8^\circ$  Cobb angle (figs. 5, 6).

### Sagittal lumbar plane

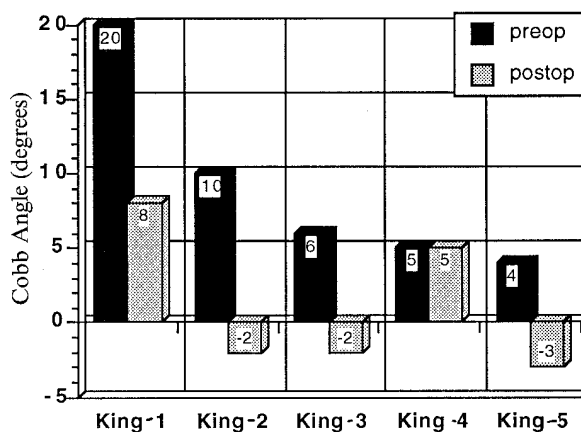
All of the 13 patients instrumented down to L5 or S1 had either severe King-1 or King-2 scolioses. Without exception they were within normal limits pre- and postoperatively, and no notable changes were seen. Another 12 King-1 and King-2 patients and one King-4 patient were instrumented to at least L4 and analyzed separately. No different results were obtained in comparison to the above mentioned 13 patients. In particular, no compensatory secondary reaction was noted below the instrumentation.



**Fig. 5.** — Mean correction of hyperlordotic lower thoracolumbar junctions in relation to the type of scoliosis. All except one King-5 curve were within normal ranges postoperatively. Note the excellent results in King-3 and King-4 curves.

## DISCUSSION

Stagnara was the first to establish a table of references for kyphosis and lordosis and found a wide range of "normals" with a thoracic kyphosis between  $30^\circ$  and  $50^\circ$ , averaging  $37^\circ$  Cobb angle. In his study the lumbar lordosis measured between  $18^\circ$  and  $69^\circ$  from L1 to L5 (12). The use of his reference table, set up by measuring the reciprocal angulation of the sagittal spine with the Cobb



**Fig. 6.** — Mean correction of kyphotic lower thoracolumbar junctions. Most of these were seen in King-2 curves with good realignment due to reverse rod bend and reversal of hooks according to Shufflebarger.

method, is difficult. Moe stated the normal lordosis as  $40^\circ$  to  $60^\circ$  without defining exact measurement levels.

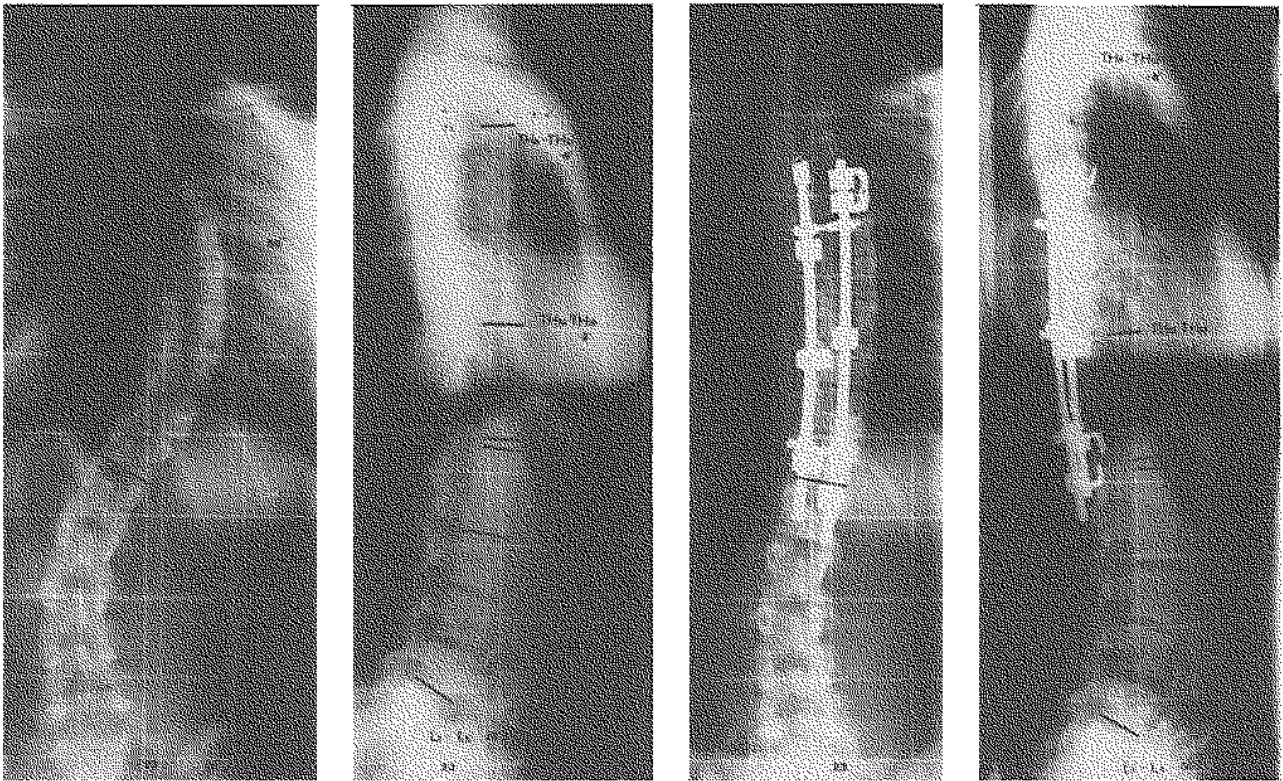
Concerning the thoracolumbar junction Bradford says that any kyphosis in this area is abnormal (2). He stated that the junction is for all purposes straight. In Bernhardt's study group they measured a kyphosis of  $+5.5^\circ$  with a standard deviation of  $+4^\circ$  in the upper junction and a lordosis of  $-3^\circ$  with a standard deviation of  $\pm 7^\circ$  in the lower junctional area. The mean thoracic kyphosis was  $36^\circ$  with a standard deviation of  $\pm 10^\circ$ , and the lumbar lordosis averaged  $-44^\circ$  with a standard deviation of  $\pm 12^\circ$  Cobb angle (1). Regarding these results, especially those of Bernhardt *et al.*, we set up our "normals" for this study, which were already mentioned above. In idiopathic scoliosis with a major right convex thoracic curve three sagittal plane deformities have been noted. These are thoracic hypokyphosis, junctional kyphosis and lumbar hypolordosis (3). To what extent the lumbar hypolordosis frequently seen is secondary as a reaction to thoracic hypokyphosis or is primarily pathological is debatable. Especially in King-1 and King-2 curves the rotation of the lumbar vertebrae implies a primary "rotatory kyphosis".

During the time of Harrington instrumentation (HI) in the nineteen-sixties, -seventies and early-eighties, sagittal plane correction did not play a very important role in scoliosis surgery. According to the literature HI did not normalize these sagittal deformities (3, 4, 6). Additionally there was the consensus that no derotation was possible with this type of operation. Zielke was the first to introduce a system capable of correcting scoliotic deformities in all three dimensions: the VDS, internationally known as Zielke instrumentation (14). Derotation, sagittal plane alignment and curve correction are possible by correct screw and rib graft placement, although others have reported difficulties in controlling the sagittal plane in the lumbar and thoracolumbar spine.

When Cotrel and Dubousset introduced CDI they established a primary stable frame construction, which could correct all three pathological dimensions in scoliosis (5). The derotational ca-

pacities of this system are especially controversial. For instance, Krismer did not find much derotation within the area of the apical vertebra (9), whereas others reported cases of decompensation, especially in King-2 curves, with or without torque enhancement in the uninstrumented lumbar spine (8, 13). A few papers have been published concerning the influence of CDI on the sagittal plane (3, 10, 11). Richards *et al.* did not find significant changes in thoracic kyphosis and lumbar lordosis, but admitted difficulties in treating junctional kyphosis in King-2 and King-3 curves (10). We in our series noted remarkable improvement in the thoracic sagittal plane. Almost half of the patients with hypokyphosis and one-third of the patients with hyperkyphosis ended up with a physiological thoracic profile. Comparable to our results Bridwell found an average  $13^\circ$  improvement in thoracic hypokyphosis preoperatively below  $+15^\circ$  Cobb angle (3), but, as he did, we found some individual cases without any changes. The more severe the hypokyphotic deformity was in his series the better the correction was. We found a mean correction of  $+17^\circ$  with a maximum of  $+27^\circ$  Cobb angle in our patients with thoracic lordosis. However, statistical analysis did not reveal significant differences between the King-classified group. The reason, why King-4 curves had the best results with respect to the thoracic profile, is simply that these were the ones with the most extensive flat back.

Concerning the thoracolumbar junction, early reports on CDI pointed out the risk of producing or maintaining a junctional kyphosis because of using too much distractive force prior to and/or after the derotation maneuver (10). We therefore used the modified hook pattern introduced by Shufflebarger (11) for high-risk cases and placed a reverse bend and reversal of hooks with compression forces across the junction. This procedure gave good results, comparable to the ones of Shufflebarger and Bridwell (3, 11). As in their series, we did not find junctional kyphosis in preoperatively normal junctions, where the "normal" thoracic hook pattern was used. Richards *et al.* noted the development of quite a few junctional kyphotic deformities in King-2 and King-3 cur-



*Fig. 7.* — King-3 scoliosis, frontal plane deformity preoperatively of 65° Cobb angle (A) with a severe lordotic deformity of the thoracic spine and upper thoracolumbar junction (B). Both were well corrected with CDI from T5 to T12, using the normal thoracic hook pattern (C, D).

ves (10). Furthermore, the data from our study show that with CDI the upper and lower thoracolumbar junction can be controlled or improved selectively. Bridwell and Shufflebarger defined only one whole junction, the former from T12 to L2, the latter from T10 to L2 (3, 11).

Discussing the influence of CDI on the lumbar spine is quite difficult for various reasons. First of all in idiopathic scoliosis the instrumentation rarely covers the whole lumbar spine. Secondly this part of the spine especially has an extremely wide range of so-called normal angles, as reported by Stagnara (12). In most of the short instrumented patients with thoracic hypokyphosis or hyperkyphosis we found a compensatory realignment of lumbar lordosis for balancing the sagittal plane. These results correspond well to those of Bridwell and Shufflebarger (3, 11). In patients instrumented down to L4, L5 or S1 we could not

find notable changes in the sagittal plane, but all curves were within normal ranges. This implies that CDI can at least preserve the lumbar sagittal plane, which corresponds to the results of Bridwell. Additionally, he felt that in some cases mild enhancement of lumbar lordosis is possible.

In conclusion, the data from this study show that remarkable improvement of the thoracic plane in idiopathic scoliosis patients with a major right convex thoracic curve with or without an additional major or compensatory curve is usually possible, when there is a pathological deformity preoperatively. The more severe thoracic hypokyphosis (lordosis) is preoperatively, the better the correction is. Hyperkyphosis and lordosis of the upper thoracolumbar junction as well as kyphosis and hyperlordosis of the lower thoracolumbar junction are selectively easily correctable. A preoperatively normal sagittal plane can be preserved.

## REFERENCES

1. Bernhardt M., Bridwell K. H. Segmental analysis of the sagittal plane alignment of the normal thoracic and lumbar spine and thoracolumbar junction. *Spine*, 1989, 7, 717-721.
2. Bradford D. S. Juvenile kyphosis. Moe's textbook of scoliosis and other spinal deformities. W. B. Saunders Company, Philadelphia, 1994, pp. 349-368.
3. Bridwell K. H., Betz R., Capelli A. M., Huss G., Harvey C. Sagittal plane analysis in idiopathic scoliosis patients treated with Cotrel-Dubousset instrumentation. *Spine*, 1989, 7, 644-649.
4. Cochran T., Irstam L., Nachemson A. Long term idiopathic scoliosis treated by Harrington rod fusion. *Spine*, 1983, 8, 576-584.
5. Cotrel Y., Dubousset J., Guillaumat M. New Universal instrumentation in spine surgery. *Clin. Orthop.*, 1988, 227, 10-23.
6. Crawford A. H., Macke J., Caudle R. Sagittal plane correction by contoured Harrington rods and interspinous segmental instrumentation. Proceedings of the Annual Meeting of the Scoliosis Research Society, Vancouver, Canada, 1987, 45.
7. King H. A., Moe J. H., Bradford D. S., Winter R. B. The selection of fusion levels in thoracic idiopathic scoliosis. *J. Bone Joint Surg.*, 1983, 65-A, 1302-1313.
8. Mason D. E., Carango P. Spinal decompensation in Cotrel-Dubousset instrumentation. *Spine*, 1991, 8 (Suppl.), 394-403.
9. Krismer M., Bauer R., Sterzinger W. Scoliosis Correction by CD-instrumentation: The effect of derotation and three dimensional correction. *Spine*, 1992, 17, 8 (Suppl.), 263-269.
10. Richards B. S., Birch J. G., Herring J. A., Johnston C. E. Frontal plane and sagittal plane balance following Cotrel-Dubousset instrumentation for idiopathic scoliosis. *Spine*, 1989, 7, 733-737.
11. Shuffleburger H. L., Clark C. E. Fusion levels and hook patterns in thoracic scoliosis with Cotrel-Dubousset instrumentation. *Spine*, 1990, 9, 916-920.
12. Stagnara P., De Mauroy J. C., Dran G. Reciprocal angulation of vertebral bodies in a sagittal plane: Approach to references in the evaluation of kyphosis and lordosis. *Spine*, 1982, 7, 335-342.
13. Thompson J. P., Transfeldt E. E., Bradford D. S. De-compensation after Cotrel-Dubousset instrumentation of idiopathic scoliosis. *Spine*, 1990, 9, 927-931.
14. Zielke K. Ventrale Derotationsspondylodese. Behandlungsergebnisse bei idiopathischen Lumbalskoliosen. *Z. Orthop.*, 1982, 120, 320-329.

## SAMENVATTING

*H. HALM, W. H. M. CASTRO, J. JEROSCH, W. WINKELMANN. Correctie in het frontale vlak met idiopatische scoliosen volgens King geklassificeerd en behandeld met instrumentarium van Cotrel-Dubousset.*

*Doel van de studie* : ofschoon met behulp van de Harrington-instrumentatie een goede correctie in het frontale vlak mogelijk is bij patiënten die wegens een idiopatische scoliose geopereerd worden, is de correctie in het sagittale vlak moeilijk. Het corrigeren van het sagittale realignment is volgens de literatuur eenvoudiger met behulp van het Cotrel-Dubousset instrumentarium (CDI). Er werd een studie verricht om te onderzoeken of een sagittaal realignment met behulp van CDI, bij onze patiënten met een idiopatische scoliose die volgens King geklassificeerd is, bereikt was.

*Materiaal en methode* : 97 patiënten met een idiopatische scoliose volgens King geklassificeerd en behandeld met CDI werden in het frontale en sagittale vlak door een „unbiased observer” röntgenologisch onderzocht. De sagittale curve met behulp van de Cobb-methode van Th4 tot L2 (normaalwaarden : +25° - +40°) en L1 tot 5 (normaalwaarden : -40° - -55°) gemeten.

De thorakolombale overgang (TO) werd verdeeld in een bovenste TO (Th10-12) en een onderste TO (Th12-L2) met normaalwaarden van resp. 0° - +10° en 0° - -10°. *Resultaten* : bij alle scoliosen met een geassocieerde thorakale hypokyphose werd een goed realignment in het sagittale vlak geconstateerd, variërend van 8° in King 1 en 3 curves tot 19° in King 4 curves. Bij normokyphotische curves werd geen significante verandering van de thorakale wervelkolom postoperatief gemeten. In de bovenste TO werd de pathologische lordose gemiddeld 7° gecorrigeerd, terwijl de correctie van de kyphose varieerde tussen 8°-18° volgens Cobb. Pathologische kyphose en hyperlordose van de onderste TO toonde een gemiddelde correctie van resp. 7° en 11°. Er was geen directe significante invloed d.m.v. CDI op het sagittale vlak van de lumbale wervelkolom.

*Conclusie* : de gegevens suggereren, dat met behulp van Cotrel-Dubousset instrumentarium het sagittale vlak bij de meeste patiënten met een volgens King geklassificeerde scoliose verbeterd kan worden.

## RÉSUMÉ

*H. HALM, W. H. M. CASTRO, J. JEROSCH, W. WINKELMANN. Correction dans le plan sagittal des courbures scoliotiques idiopathiques, classifiées selon King, traitées par instrumentation de Cotrel-Dubousset.*

Si l'instrumentation de Harrington donne une bonne correction dans le plan frontal des courbures scoliotiques idiopathiques, la correction dans le plan sagittal en reste difficile. Le réalignement dans le plan sagittal est, d'après la littérature, nettement facilité par l'instrumentation de Cotrel-Dubousset (CDI).

Les auteurs ont fait une étude de la correction dans le plan sagittal à l'aide du C.D.I. chez des patients qui présentent une scoliose idiopathique classifiée selon King. *Matériel et méthode* : 97 malades présentant une scoliose idiopathique classifiée selon King et traitée par instrumentation CDI ont été radiographiés dans le plan frontal et le plan sagittal par un observateur non prévenu. La courbure sagittale fut évaluée par la méthode de Cobb de T4 à T12 (valeurs normales + 25° + 40°) et de L1 à L5 (valeurs normales -40°

-55°). La jonction dorso-lombaire fut divisée en une jonction supérieure (T10-T12) et une jonction inférieure (T12-L2) avec des valeurs normales de respectivement 0° à +10° et 0° à -10°.

*Résultats* : toutes les scioses avec une hypocyphose associée furent correctement réalignées dans le plan sagittal, variant de 8° dans les courbes King 1 et 3 jusqu'à 19° dans les courbes King 4.

Pour les courbes cyphotiques on ne nota aucune différence significative par rapport à la mesure post-opératoire. A la jonction supérieure la lordose pathologique était corrigée en moyenne de 7°, alors que la correction de la cyphose variait de 8° à 18° selon Cobb. Les cyphoses pathologiques et les hyperlordoses de la jonction inférieure étaient corrigées en moyenne de 7° et 11° respectivement. Il n'y avait pas d'influence significative de l'instrumentation CDI sur la correction dans le plan frontal à la colonne lombaire.

*Conclusion* : ces données suggèrent qu'au moyen de l'instrumentation CDI la correction dans le plan sagittal peut être obtenue chez la plupart des patients qui présentent une scoliose classifiée selon King.