

LATE PRESENTATION OF BILATERAL HABITUAL DISLOCATION OF THE PATELLA ON FLEXION

R. A. MARSTON, G. BENTLEY

We describe the case of a 56-year-old woman who, despite having bilateral habitual dislocation of the patella, remained asymptomatic until an injury to her left knee. We suggest that there is a need for a randomized study to evaluate the results of surgical and nonsurgical treatment.

Keywords : habitual dislocation ; patella.

Mots-clés : luxation habituelle ; rotule.

the outer side of the knee. Therefore Williams (6) advocated quadricepsplasty and relocation of the patella in children with habitual dislocation to prevent painful osteoarthritis in later life. This involves a considerable surgical procedure, which is not always successful, and may result in further instability and pain.

A recent case calls this approach into question.

INTRODUCTION

Habitual dislocation of the patella in flexion implies that dislocation occurs every time the knee is flexed. This must be distinguished from recurrent dislocation which may or may not be of traumatic origin but only occurs intermittently. In addition the displacement in patients who have habitual dislocation of the patella is painless. The average age at presentation has been reported as 9 years, with a range of 13-15 years (2). This accords with the stage at which growth of the femur is disproportionate to that of the quadriceps. Quadriceps fibrosis in association with intramuscular injection (1, 4), abnormal attachment of the iliotibial tract to the patella (5) and quadriceps contraction (6) have all been implicated as causes of habitual dislocation.

There are no published data on the long-term outcome of untreated habitual dislocation. However in Williams' review of 35 children (2) he also examined a number of untreated affected parents. He noted that they all had significant disabilities consisting of a flexion deformity, marked patello-femoral arthritis, and pain and instability. In some, the patella was barely reducible, being fixed to

CASE REPORT

A 56-year-old woman presented to a related hospital with a history of pain in her left knee following a fall 4 years previously. Her initial treatment had been a 6-week period with the knee bandaged and mobilization on crutches. Shortly after this period an arthroscopic washout was performed to drain a large persistent hemarthrosis.

When referred, in addition to suffering from intermittent pain aggravated by exercises and climbing stairs, the patient complained that the knee was "giving way" up to 3 times per week. She had had to relinquish her job as a school cleaner and required a walking stick.

On examination she was noted to walk slowly with an antalgic gait on the affected side. When the patient was recumbent, both knees had small effusions. She had bilateral retropatellar tenderness

The Institute of Orthopaedics, The Royal National Orthopaedic Hospital Trust, Brockley Hill, Stanmore, Middlesex, HA7 4LP, United Kingdom.

Correspondence and reprints : R. A. Marston, Dept. of Orthopaedics, Middlesex Hospital, Mortimer Street, London, W1N 8AA, United Kingdom.

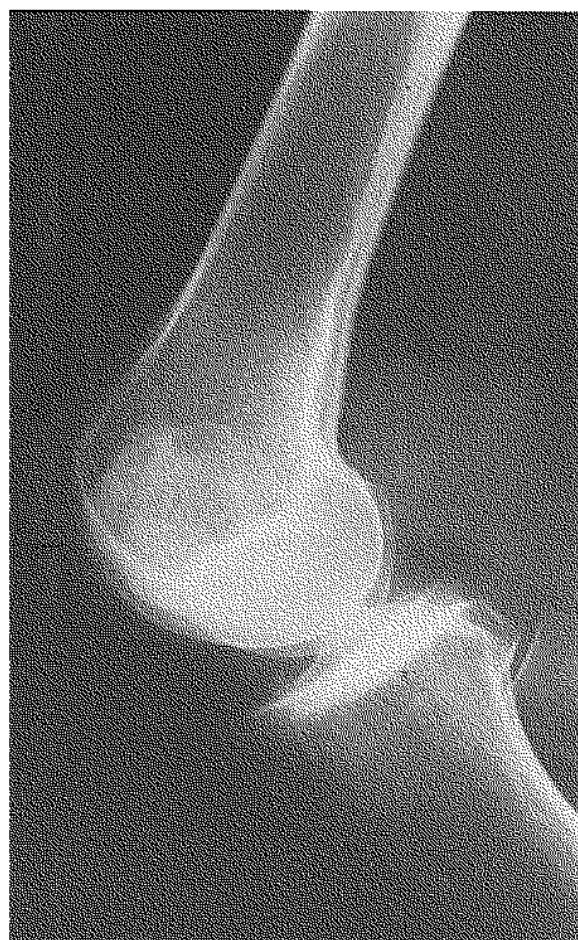
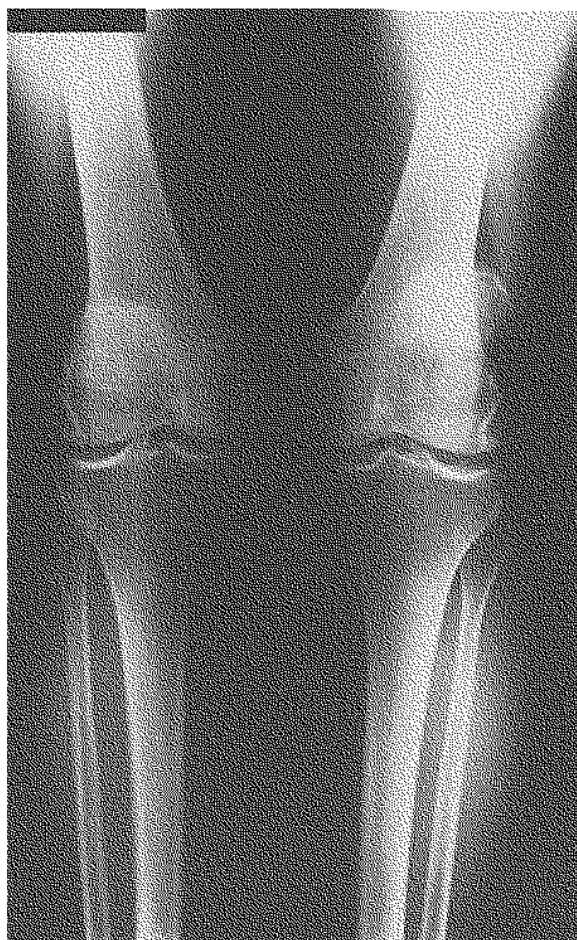

Fig. 1. -- Anteroposterior radiograph of both knees (standing film).

Fig. 2. -- Lateral radiograph of the left knee illustrating dislocation of the patella.

Fig. 3. -- 30° tangential radiograph (left knee on left of film) illustrating bilateral lateral dislocation.

but no difference in quadriceps girth on each side. The left knee had a 1+ anterior drawer sign. The range of flexion in both knees was 0-130°, accompanied by crepitus, with no extensor lag. It was noted that both patellae painlessly dislocated laterally at 30° of flexion.

Tangential xrays taken in 30° of flexion showed the patellae to be dislocated laterally around hypo-

plastic lateral femoral condyles, associated with gross degenerative change of the patello-femoral joints which was much more marked on the right than the left (fig. 1-3).

Examination of the left knee under general anesthesia confirmed lateral dislocation on flexion beyond 30° in addition to the slight anterior cruciate laxity. Arthroscopic examination revealed

early degenerative change in both tibial plateaus and degenerative menisci. A 50% midsubstance tear of the anterior cruciate ligament was noted. There were severe degenerative changes on the posterior surface of the patella with deep cartilage fibrillation and exposure of subchondral bone. The contiguous surface of the rudimentary femoral groove was similarly affected. A lateral retinacular release was performed in addition to a washout with one liter of saline.

DISCUSSION

It is generally accepted that habitually dislocating patellae, while often asymptomatic in the young, will produce painful degenerative change and disability in adult life. This case does not support that thesis. While there is no doubting the abnormal degenerative changes which occurred following habitual dislocation in this patient, she was asymptomatic until the age of 52 and only developed symptoms after a significant injury. In addition, it is notable that she was asymptomatic in the uninjured right knee which exhibited more severe radiographic changes of osteoarthritis. Great difficulty is sometimes experienced in achieving stability of the patella when, because it has never been located, the femoral groove is very flat and poorly developed. Moreover, the establishment of an ill fitting and incongruous patello-femoral joint in the mid-teens which is often achieved only by increasing the tension in the quadriceps, is likely to produce an increased incidence of early degenerative change and pain (3). This patient demonstrated good results from nonoperative management and illustrates the need for a prospective randomized trial between surgical and nonsurgical management of this difficult problem.

REFERENCES

1. Alvarez E. V., Munters M., Lavine L. S., Manes H., Waxman J. Quadriceps Myofibrosis : A complication of intra-

muscular injections. *J. Bone Joint Surg.*, 1980, 62-A, 58-60.

2. Bergman N. F., Williams P. F. Habitual dislocation of the patella in flexion. *J. Bone Joint Surg.*, 1988, 70-B, 415-419.
3. Crosby E. B., Insall J. Recurrent dislocation of the patella. Relation of treatment to osteoarthritis. *J. Bone Joint Surg.*, 1976, 58-A, 9-13.
4. Gunn D. R. Contracture of the quadriceps muscle. A discussion on the aetiology and relationship to recurrent dislocation of the patella. *J. Bone Joint Surg.*, 1964, 46-B, 492-497.
5. Jeffreys T. E. Recurrent dislocation of the patella due to abnormal attachment of the iliotibial tract. *J. Bone Joint Surg.*, 1963, 45-B, 740-743.
6. Williams P. F. Quadriceps contracture. *J. Bone Joint Surg.*, 1968, 50-B, 278-284.

SAMENVATTING

R. A. MARSTON, G. BENTLEY. Laattijdige ontdekking van een bilaterale, habituele dislocatie van de patella.

De auteurs rapporteren het geval van een 56 jarige vrouw, die asymptomatisch was, ondanks een bilaterale, habituele patellaxulatie, tot wanneer zij een trauma opliep thv de li-knie.

De auteurs suggereren een gerandomiseerde studie, ter evaluatie van de resultaten van chirurgische en orthopedische behandeling.

RÉSUMÉ

R. A. MARSTON, G. BENTLEY. Manifestation tardive d'une luxation habituelle bilatérale de la rotule.

Les auteurs décrivent le cas d'une femme de 56 ans qui présentait de façon bilatérale une luxation habituelle de la rotule et resta cependant asymptomatique jusqu'à ce qu'elle subisse un traumatisme au niveau du genou gauche.

Ils suggèrent qu'une étude randomisée serait nécessaire pour évaluer de façon comparative les résultats du traitement chirurgical et du traitement conservateur.