

ULNAR VARIANCE : FACTS AND FICTION REVIEW ARTICLE

L. DE SMET¹

The relative length of the ulna compared to the radius, or ulnar variance, appears to be an important element in wrist pathology. The length is determined by age, genetic factors, load (i.e. gymnasts) and gross elbow pathology. The negative ulnar variance or short ulna has been associated with Kienböck's disease, avascular necrosis of the scaphoid and scapholunate dissociations. This could not be confirmed in our observations. On the contrary, a long ulna (positive ulnar variance) is harmful for the ulnar compartment of the wrist as it causes degeneration and perforation of the triangular fibrocartilage complex (TFCC) and cartilaginous wear of the carpal bones (ulnar impaction syndrome). The ulnar variance is also determinant for the morphology of the sigmoid notch of the radius. With wrist arthroscopy a more precise diagnosis of ulnar wrist pain has become possible.

Keywords : ulna ; variances.

Mots-clés : cubitus ; variance.

INTRODUCTION

The DRUJ (distal radioulnar joint) is phylogenetically a "young" joint. In most primates a real synovial joint exists between ulna, triquetrum and pisiform bone. In the hominoid a transition occurs towards the situation in *Homo sapiens* (6, 51, 52). In men the DRUJ became a complex articulation with meniscus-like structures (TFCC — triangular fibrocartilage complex — and meniscus homologue) between ulna and carpus (10, 12, 47, 54, 72). Numerous anatomical variations exist, and especially the length of the ulna compared to the radius (ulnar variance or UV) can differ between individuals, and may even change during

one's lifetime (14, 17, 25, 37, 45, 49, 62). The influence on the UV and the effect of the UV on the wrist joint, the pathologies around the DRUJ and the TFCC, and the appropriate solutions are currently under investigation. This paper comments on these interrelationships and relates them to the author's experience.

ULNAR VARIANCE

The length of the ulna compared to the radius is not constant among individuals, nor during lifetime. This relative length is expressed as the ulnar variance (UV) (45). When the ulnar length differs by less than 1 mm from the radius, this is a neutral UV or ulna zero.

Measurement of UV requires a standardized technique of radiography and a reliable and reproducible measurement technique. As has been noted by Epner (30), Kristensen (49) and Nakamura (62), the length of the ulna changes during pronation and supination (9). In supination the radius is parallel to the ulna and at its maximal length the UV decreases. The opposite is true during pronation.

To overcome this phenomenon, the "zero-position" exposure is recommended (shoulder abducted to 90° and elbow flexed at 90°, with neutral position of the forearm and the hand aligned with the forearm axis) (30). As pointed out by Kristensen (49), none of the measurements

¹ University Hospital Pellenberg, Department of Orthopedics, K.U. Leuven, B-3212 Pellenberg, Belgium.

Correspondence and reprints : L. De Smet.

of UV before 1983 can be interpreted since no details about the rotational state of the forearm are known. Palmer (69) described a technique of measurement with concentric circles, but other methods have been reported (37), with reliable and comparable results (87).

There is a wide distribution of UV in the population (fig. 1) ranging from -4 to $+2$ mm, the mean being (in our population) -0.42 mm. Other values have been found by different authors (14, 17, 21, 25, 37, 45, 49, 55, 62) (see table I). Black and asian populations seem to have more positive values (37, 62).

Only Nakamura (62) found a significant difference between males and females. Furthermore his observation of an increasing UV with advancing age has now been confirmed. Hafner and Poznanski (40) noted a similar finding in growing children, De Smet *et al.* found the same in adults (21, 25), and Fortems *et al.* (35) confirmed it in an elderly population.

The mechanism of this lengthening of the ulna (or shortening of the radius) has not yet been resolved. Murata *et al.* (60) claimed the degeneration of the radial head to be responsible for this pseudo-lengthening of the ulna. We were not able to confirm this in a cadaver dissection of 38 elbows and wrists.

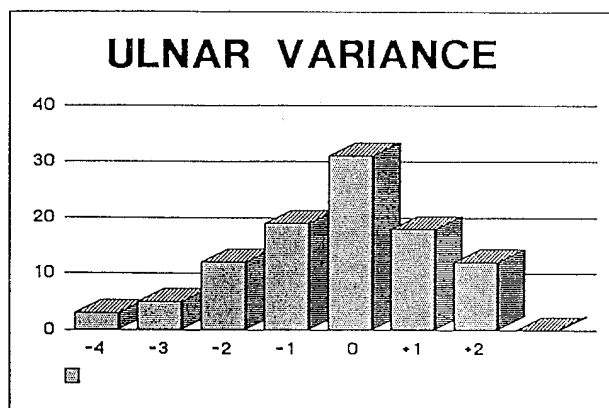


Fig. 1. — Distribution of UV among a normal population.

Table I. — Normal UV

| Author | Year | Ref. | N | Mean UV | U ₊ | U ₀ | U ₋ |
|------------|------|------|--------------|---------------|----------------|----------------|----------------|
| Hulten | 1928 | 45 | 400 | - 0.7 | 16 | 61 | 23 |
| Gelberman | 1975 | 37 | 419 bl wh | + 0.7 0.27 | | | 21 13 |
| Chan | 1980 | 14 | 400 | 0.83 | 48.2 | 41.8 | 10 |
| Kristensen | 1986 | | 100 | - 0.84 | | | |
| Czitrom | 1987 | 17 | 65 | - 0.38 | | | 41.5 |
| Mandelbaum | 1989 | | 25 | - 0.54 | | | |
| Nakamura | 1991 | 62 | 325 | 0.2 | 32.2 | 39.3 | 27.4 |
| D'Hoore | 1991 | 25 | 125 | - 0.42 | 38 | 18 | 43 |

FACTORS DETERMINING THE UV

It is obvious that genetic factors determine the phenotype ; also in the determination of UV, the genes are major contributors. The striking parallelism between left and right wrists is an argument for genetic determination, even in professions or sports with a significant overuse of one upper limb.

Förstner, Tolat *et al.* and the present authors (33, 34, 93) were able to distinguish 3 types of sigmoid notches of the radius, each of them

correlated with the UV (fig. 2). Increasing UV is also correlated with decreased thickness of the TFCC (35, 70) (fig. 3). These two morphological correlations are additional arguments for genetic determination of UV.

Of course with twin studies this should be conclusive, but the limited series of adult twins with radiographs of their wrists in zero position prevents detailed statistic evaluation.

Besides (normal) genetic determination, other external influences cannot be denied. Submitting the immature wrist to prolonged compression

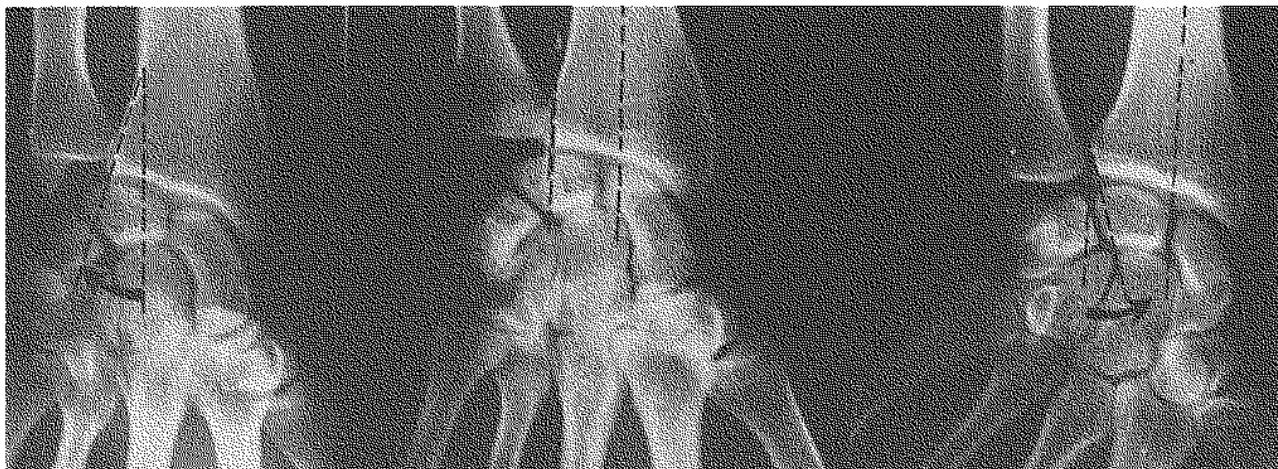


Fig. 2. — 3 types of sigmoid notch.

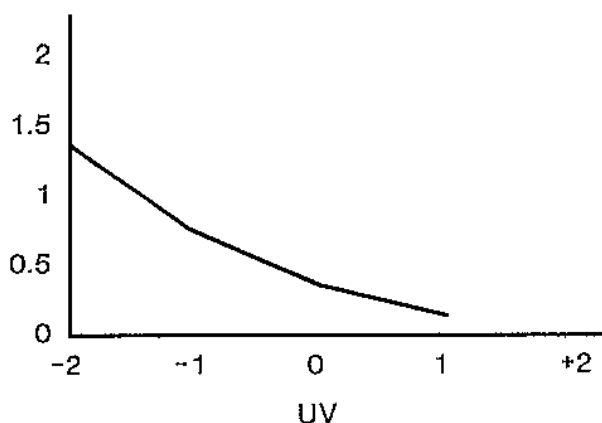


Fig. 3. — Correlation between UV and TFCC thickness.

and/or repetitive (micro)traumata, as is seen in (female) gymnasts (3, 24, 27, 55, 93, 99), leads to ulnar overgrowth, due to a premature arrest of the radial growth plate. Fracture dislocations (Essex-Lopresti) or removal of the radial head (12, 31, 56, 57, 91) lead to proximal migration of the radius with an important ulna plus in a high percentage of the cases.

INFLUENCE OF ULNAR VARIANCE ON THE WRIST

The variability of the ulnar length would not be more than a curiosity if differences in UV had not been associated with wrist pathology.

a) Ulna minus

Attention was drawn to this form of UV by Hulten in 1928 (45), who associated a negative UV with Kienböck's disease. This was confirmed later, and the clinically good results of radial shortening or ulnar lengthening (the so-called leveling procedures) were additional arguments to explain the etiology of avascular necrosis of the lunate (4, 5, 7, 8, 11, 29, 37, 45, 49, 61, 64, 68, 76, 82, 85, 86, 88, 92, 106, 109) (tables II, III, IV). The recent observations by Kristensen (49, 50), Nakamura (62) and D'Hoore (24, 25), however, could not correlate ulna minus with Kienböck's disease when scx/age-matched controls were used, and when careful radiographic techniques (zero-position) were respected.

These papers cannot provide enough evidence for Kienböck's disease as being caused by uneven pressure on the lunate by the longer radius. Leveling procedures therefore are not more than osseous decompressive techniques. Other procedures such as trisicaphe-arthrodeses can give similar effects (5, 44, 94, 102, 104, 105).

Our personal review of 17 radial shortenings (100) demonstrated the ineffectiveness of leveling procedures on the morphology of the lunate and the impairment of DRUJ functioning. Pressures in the DRUJ increase considerably after ulnar shortening (107).

Parkinson *et al.* (75) suggested nontraumatic avascular necrosis of the scaphoid (Preiser's disease) (78) to result from negative UV. Cumulative data of published cases (18, 22) and the series of the Mayo Clinic were able to rule out this suggestion (101) (table V).

Table II. — UV and Kienböck's disease

| Author | Ref. | Year | UV |
|------------|------|------|--------|
| Hulten | 45 | 1928 | - 2.04 |
| Gelberman | 37 | 1975 | - 1.40 |
| Armistead | 7 | 1982 | - 3.01 |
| Sundberg | 88 | 1983 | - 2.04 |
| Kristensen | 49 | 1986 | - 1.42 |
| Kristensen | 50 | 1987 | - 1.04 |
| Wun-schen | 108 | 1990 | - 1.22 |
| Nakamura | 62 | 1991 | - 0.37 |

Table III. — Effect of ulnar lengthening on Kienböck's disease

| Author | Ref. | Year | N | % Good results |
|--------------|------|------|----|----------------|
| Tilbert | 92 | 1968 | 10 | 100 |
| Armistead | 7 | 1982 | 20 | 90 |
| Sundberg | 88 | 1983 | 19 | 95 |
| Schattenkerk | 85 | 1987 | 15 | 70 |

Table IV. — Effect of radial shortening on Kienböck's disease

| Author | Ref. | Year | N | % Good results |
|--------------|------|------|----|----------------|
| Calandriello | 11 | 1966 | 10 | 90 |
| Axelson | 8 | 1973 | 19 | 100 |
| Rosemeyer | 82 | 1976 | 19 | 68.5 |
| Eiken | 29 | 1980 | 8 | 87 |
| Ovesen | 68 | 1981 | 8 | 87 |
| Almqvist | 4 | 1982 | 12 | 91 |
| Schattenkerk | 85 | 1987 | 20 | 70 |
| Nakamura | 61 | 1990 | 23 | 83 |
| Weiss | 105 | 1991 | 29 | 87 |

Table V. — UV and Preiser's disease

| Cumulative data of Preiser | D'Hoore | Nakamura |
|----------------------------|---------|----------|
| positive : 5 | 39% | 32% |
| neutral : 10 | 19% | 39% |
| negative : 8 | 43% | 27% |

Since no avascular necrosis of the lunate nor of the scaphoid was ever published after a Darrach's resection of the ulnar head, we think that negative UV has limited or no influence on carpal vascularity.

Czitrom *et al.* (17) correlated negative UV and recent scapholunate dissociation. Although his series is similar to ours, we could not find a similar correlation in a group of 43 cases of scapholunate dissociations, compared to 125 controls.

b) Ulna plus

The degenerative changes in the ulnar compartment of the wrist due to increased ulnar length have been called the "ulnar impaction syndrome" (36).

Palmer's biomechanical investigations (71) have demonstrated a considerable pressure shift to the ulnar side of the wrist when the ulna is lengthened by 2 mm (or more). The effect of this increased pressure in the ulnar part of the wrist, is expressed as more frequent perforations of the TFCC (35, 72, 73, 74), degenerations of the ulnar head (95), the lunate and triquetrum (72, 92). Also ruptures of the lunotriquetral ligaments have been associated with ulna plus.

The recommended treatments for this phenomenon have been debated. Although shortening of the ulna seems obvious (53), the different types of sigmoid notches (33, 34, 93) can make the outcome hazardous. Decompression of the ulnar compartment by resection of the ulnar head (totally, partially or only a "wafer" removed) have failed in our hands to provide reproducible results (9, 16, 32, 59, 103). Leveling with an arthrodesis of the DRUJ, associated with a cuff resection proximal to the DRUJ (Sauvé Kapandji's procedures) (fig. 4) gave us the most reliable outcome with 80% good results (15, 20, 23, 38, 39, 46, 58, 63, 83, 84, 90, 96, 110).

The ulna plus with osteoarthritis of the DRUJ can be the cause of rupture of extensor tendons. Not only in rheumatoid arthritis, but also in Madelung's deformity and constitutional or post-traumatic ulna plus, the attrition of the ulnar head has been held responsible for sequential rupture

of the extensor tendons of the long fingers (13, 19, 28, 42, 65, 79, 89, 98).

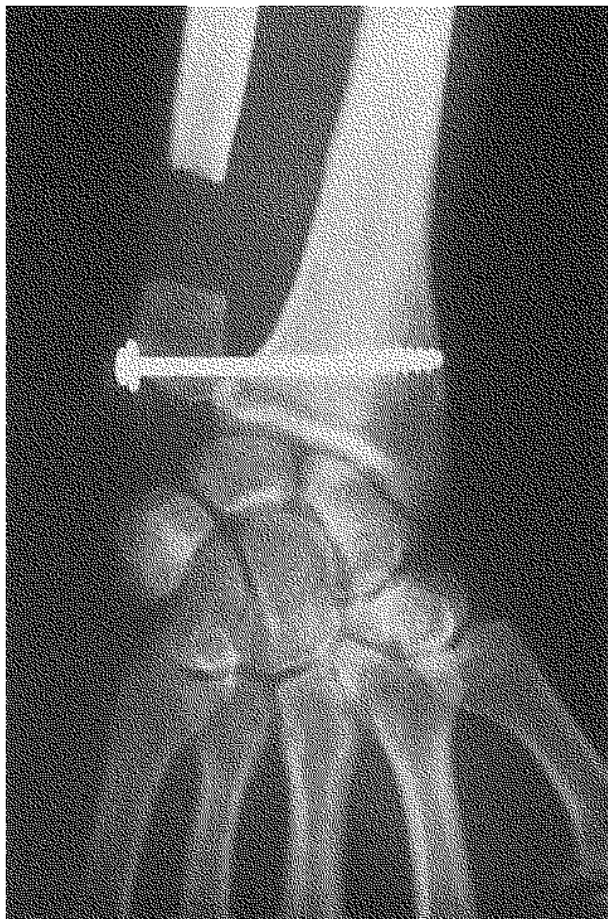


Fig. 4. — Sauvé-Kapandji procedure.

ARTHROSCOPY AND UV-RELATED PATHOLOGY

After the knee and shoulder, the wrist is probably the third most frequent joint to be arthroscoped. Since the development of smaller instruments, inspection of the interior of the wrist became possible. But what is the value?

From the therapeutic point of view, only a few procedures (107) are possible: removal of a loose body (112), suturing the TFCC (111) and "ectomy" procedures. The results of these "ectomy" procedures are still open to discussion, and transporting

the good results in knee arthroscopy to the wrist would be overly optimistic. More critical and long-term follow-up results are required (41, 66, 67, 80).

For the diagnosis, on the contrary, we can be more affirmative, since we found in a considerable percentage of wrists with negative arthroscopy, additional information leading to further (usually surgical) treatment (16, 43, 48, 88, 81, 97). We (97) dare to conclude that diagnostic arthroscopy of the wrist is an important achievement in the evaluation of ulnar-sided pathology of the wrist, as has been mentioned by several other authors (48, 81).

CONCLUSIONS

In reviewing the literature we were surprised by the lack of "hard data" to support statements. A careful selection of papers, and personal experience and investigations concerning ulnar variance have led to the following conclusions:

- Ulnar variance is determined by age, genetics, loading and elbow pathology.
- Determination of the UV requires a standardized technique of radiography.
- Negative ulnar variance is not an important etiological factor in Kienböck's disease, in Preiser's disease, or in scapholunate dislocations.
- Positive ulnar variance leads to the "ulnar impaction syndrome" with perforation of the TFCC, cartilaginous degeneration of the lunate, triquetrum and ulnar head.
- The morphotype of the sigmoid notch of the radius and the thickness of the TFCC is correlated with ulnar variance.

REFERENCES

1. Af Ekenstam J., Hagert C. Anatomical studies on the geometry and stability of the distal radioulnar joint. *Scan. J. Plast. Reconstr. Surg. Hand Surg.*, 1985, 19, 17-25.
2. Af Ekenstam F. Anatomy of the distal radioulnar joint. *Clin. Orthop.*, 1992, 275, 14-18.
3. Albanese S. A., Palmer A. K., Kerr D. R., Carpenter C. W., Lisi D., Livinsohn E. M. Wrist pain and distal growth plate closure of the radius in gymnasts. *J. Ped. Orthop.*, 1989, 9, 23-28.

4. Almquist E. Radial shortening for the treatment of Kienböck's disease: 5-10 years follow-up. *J. Hand Surg.*, 1982, 7, 384-352.
5. Almquist E. Kienböck's disease. *Hand Clin.*, 1987, 3, 141-148.
6. Almquist E. Evolution of the distal radioulnar joint. *Clin., Orthop.*, 1992, 275, 5-13.
7. Armistead R., Linscheid R., Dobyns J., Beckenbaugh J. Ulnar lengthening in the treatment of Kienböck's disease. *J. Bone Joint Surg.*, 1982, 64-A, 170-178.
8. Axelson R. Niveau Operationen bei Mondbeinnekrose. *Handchirurgie*, 1973, 5, 187-196.
9. Bowers W. Distal radioulnar joint arthroplasty: the hemiresection-interposition technique. *J. Hand Surg.*, 1985, 10-A, 169-178.
10. Bowers V. Distal radioulnar joint. Green D. (ed.): *Operative Hand Surgery*. Churchill Livingstone, New York, 1988.
11. Calandriello B., Palandie C. Die Behandlung der Lunatum-Malacie durch Speichenverkürzung. *Z. Orthop.*, 1966, 101, 531-534.
12. Campbell C., Waters P., Emans J. Excision of the radial head for congenital dislocation. *J. Bone Joint Surg.*, 1992, 74-A, 726-733.
13. Carr A., Burge P. Rupture of extensor tendons due to osteoarthritis of the distal radioulnar joint. *J. Hand Surg.*, 1992, 17-B, 694-696.
14. Chan K., Huang P. Anatomic variations in radial lengths in the wrists of Chinese. *Clin. Orthop.*, 1971, 80, 17-20.
15. Condamine J., Leburton L., Aubriot J. L'intervention de Sauvé-Kapandji. *Ann. Chir. Main*, 1992, 11, 27-30.
16. Cooney W. P., Dobyns J. H., Linscheid R. L. Arthroscopy of the wrist: anatomy and classification of carpal instability. *Arthroscopy*, 1990, 6, 133-140.
17. Czitrom A., Dobyns J., Linscheid R. Ulnar variance in carpal instability. *J. Hand Surg.*, 1987, 12-A, 205-212.
18. De Smet L., Fabry G. Preiser's disease. Paper presented at the V^e IFSSH Meeting, Paris, 1992.
19. De Smet L. Sequential rupture of the extensor tendons 34 years after a Colles fracture, (personal communication).
20. De Smet L., Fabry G. Treatment of Madelung's deformity with radial osteotomy and the Sauvé-Kapandji procedure. *J. Ped. Orthop.* (accepted for publication).
21. De Smet L., D'Hoore K., Fabry G. Kienböck's disease and ulnar variance. VIII^e SICOT Trainees Meeting, Amsterdam, 1992.
22. De Smet L., Aerts P., Fabry G. Avascular necrosis of the carpal scaphoid. *J. Hand Surg.*, 1992, 17-A, 907-909.
23. De Smet L., Zachee B., Fabry G. The Sauvé-Kapandji procedure for non-rheumatoid disorders of the distal radioulnar joint. Paper presented at the XXIst Annual Meeting of the Am. Assoc. Hand Surg., Washington, 17-19, 1992.
24. De Smet L. The gymnast wrist. Paper presented at the Belgian Hand Group Meeting, Liège, Nov., 1992.
25. D'Hoore K., De Smet L., Verellen K., Fabry G. The rationale for leveling procedures for Kienböck's disease. Paper presented at the Belgian Hand Group Meeting, Dec., 1991.
26. Di Benedetto M., Lubbers L., Coleman C. Long-term results of the minimal resection Darrach procedure. *J. Hand Surg.*, 1991, 16-A, 445-450.
27. Dobyns J. H., Gabel G. T. Gymnast's wrist. *Hand Clin.*, 1990, 6, 493-505.
28. Ducloyer P., Leclercq C., Lisfranc R., Saffar P. Spontaneous ruptures of the extensor tendons of the fingers in Madelung's deformity. *J. Hand Surg.*, 1991, 16-B, 329-333.
29. Eiken O., Niechajev I. Radius shortening in malacia of the lunate. *Scand. J. Plast. Reconstr. Surg.*, 1980, 14, 191-196.
30. Epner R., Bowers W., Guilford W. Ulnar variance — the effect of wrist positioning on roentgen filming technique. *J. Hand Surg.*, 1982, 7, 298-305.
31. Essex-Lopresti P. Fractures of the radial head with distal radioulnar dislocations. *J. Bone Joint Surg.*, 1951, 33-B, 244-247.
32. Feldon P., Terrono A., Blsky M. The "Wafer" procedure. *Clin. Orthop.*, 1992, 275, 124-129.
33. Forstner H. Das distale Radio Ulnar Gelenk. *Unfallchirurg*, 1987, 90, 512-517.
34. Forstner H. The morphology of the distal radioulnar joint: aspects and implications for orthopaedic surgery. *Hand Chir. Microchir. Plast. Chir.*, 1990, 22, 296-303.
35. Fortems Y., De Smet L., Fabry G. Cartilaginous and ligamentous lesions of the wrist in old-aged population: an anatomical survey. Paper presented at the Belgian Hand Group Meeting, April, 1992.
36. Friedman S., Palmer A. The ulnar impaction syndrome. *Hand Clin.*, 1991, 7, 295-310.
37. Gelberman R., Salamon P., Jurist J., Posch J. Ulnar variance in Kienböck's disease. *J. Bone Joint Surg.*, 1975, 57-A, 674-676.
38. Goncalves D. Correction of disorders of the distal radioulnar joint by artificial pseudarthrosis of the ulna. *J. Bone Joint Surg.*, 1974, 56-B, 462-464.
39. Gordon L., Levinsohn D., Moore S., Doods J., Castleman L. The Sauvé-Kapandji procedure for the treatment of posttraumatic distal radioulnar joint problems. *Hand Clin.*, 1991, 7, 397-403.
40. Hafner R., Poznanski A. K., Donovan J. M. Ulnar variance in children — standard measurements for evaluation of ulnar shortening in juvenile rheumatoid arthritis, hereditary multiple exostosis and other bone or joint disorders in childhood. *Skel. Radiol.*, 1989, 18, 513-516.
41. Hanker G. J. Diagnostic and operative arthroscopy of the wrist. *Clin. Orthop.*, 1991, 263, 165-174.

42. Harvey F., Harvey P. Three rare causes of extensor tendon rupture. *J. Hand Surg.*, 1989, 14-A, 957-962.
43. Hempfling H., Schäfer H. Arthroscopy and arthrography. *Surg. Endosc.*, 1989, 3, 203-211.
44. Horri E., Garcia Elias M., An K., Bishop A., Cooney W., Linscheid R., Chao E. Effect on force transmission across the carpus in procedures used to treat Kienböck's disease. *J. Hand Surg.*, 1990, 15-A, 393-400.
45. Hulten O. Über anatomische Variationen der Handgelenkknochen. *Acta Radiol.*, 1928, 9, 155-169.
46. Kapandji I. Opération de Kapandji-Sauvé : techniques et indications dans les affections non rhumatismales. *Ann. Chir. Main*, 1986, 5, 181-193.
47. Kauer J. The distal radioulnar joint : anatomic and functional considerations. *Clin. Orthop.*, 1992, 275, 37-45.
48. Koman L. A., Poehling G. G., Toby E. B., Kammire G. Chronic wrist pain : indications for wrist arthroscopy. *Arthroscopy*, 1990, 6, 116-119.
49. Kristensen S., Thomassen E., Christensen F. Ulnar variance and Kienböck's disease. *J. Hand Surg.*, 1986, 11-B, 255-260.
50. Kristensen S., Soballe K. Kienböck's disease. The influence of arthrosis on ulnar variance measurements. *J. Hand Surg.*, 1987, 12-B, 301-305.
51. Lewis O. Evolutionary change in the primate wrist and inferior radioulnar joint. *Anat. Rec.*, 1965, 151, 275-286.
52. Lewis O. The development of the human wrist joint during the fetal period. *Anat. Rec.*, 1970, 166, 499-516.
53. Linscheid R. L. Ulna lengthening and shortening. *Hand Clin.*, 1987, 3, 69-79.
54. Linscheid D. Biomechanics of the distal radioulnar joint. *Clin. Orthop.*, 1992, 275, 46-55.
55. Mandelbaum B. R., Bortolozzi A. R., Dary C. A., Teurlings L., Bragonier B. Wrist pain syndrome in the gymnast. *Am. J. Sports Med.*, 1989, 17, 305-317.
56. McDougall A., White J. Subluxation of the inferior radioulnar joint complicating fracture of the radial head. *J. Bone Joint Surg.*, 1957, 39-B, 278-287.
57. Mikic Z., Vukadinovic S. Late results in fractures of the radial head treated by excision. *Clin. Orthop.*, 1983, 181, 220-228.
58. Millroy P., Coleman S., Ivers R. The Sauve Kapandji operation technique and results. *J. Hand Surg.*, 1992, 17-B, 411-414.
59. Minami A., Ogino T., Minami M. Treatment of distal radioulnar disorders. *J. Hand Surg.*, 1987, 12-A, 189-196.
60. Murata M., Ikuta Y., Mrakami T., Ikeda A. Degenerative changes in ulnar variance, presented at the Vth IFSSH Congress, Paris, 25-28 May 1992.
61. Nakamura R., Imeda T., Miura T. Radial shortening for Kienböck's disease : factors affecting the operative result. *J. Hand Surg.*, 1990, 15-B, 40-45.
62. Nakamura R., Tanaka Y., Umaeda T., Miura T. The influence of age and sex on ulnar variance. *J. Hand Surg.*, 1991, 16-B, 84-88.
63. Nakamura R., Tsunoda K., Watanabe K., Horii E., Miura T. The Sauvé Kapandji procedure for chronic dislocation of the distal radioulnar joint with destruction of the articular surface. *J. Hand Surg.*, 1992, 17-B, 127-132.
64. Nathan P., Meadowq K. Ulna-minus variance and Kienböck's disease. *J. Hand Surg.*, 1987, 12-A, 77-79.
65. Oshio L., Ogino T., Minami A., Kato M., Miyake A. Extensor tendon rupture due to osteoarthritis of the distal radioulnar joint. *J. Hand Surg.*, 1991, 16-B, 450-453.
66. Osterman A. L. Arthroscopic debridement of triangular fibrocartilage complex tears. *Arthroscopy*, 1990, 6, 120-124.
67. Osterman A. L., Terrill R. G. Arthroscopic treatment of TFCC lesions. *Hand Clin.*, 1991, 7, 277-281.
68. Ovesen J. Shortening of the radius in the treatment of lunatomalacia. *J. Bone Joint Surg.*, 63-B, 231-232.
69. Palmer A., Glisson R., Werner F. Ulnar variance determination. *J. Hand Surg.*, 1982, 7, 376-379.
70. Palmer A., Glisson R., Werner F. Relationship between ulnar variance and triangular fibrocartilage complex thickness. *J. Hand Surg.*, 1984, 9-A, 681.
71. Palmer A., Werner F. Biomechanics of the distal radioulnar joint. *Clin. Orthop.*, 1984, 187, 26-35.
72. Palmer A. The distal radioulnar joint. *Hand Clinics*, 1987, 3, 31-40.
73. Palmer A. K. Triangular fibrocartilage complex lesions : a classification. *J. Hand Surg.*, 1989, 14-A, 594-606.
74. Palmer A. K. Triangular fibrocartilage disorders : injury patterns and treatment. *Arthroscopy*, 1990, 6, 125-132.
75. Parkinson R., Noble J., Bale R., Freemont. Rare abnormalities of the scaphoid in association with congenital radial ray defects of the hand. *J. Hand Surg.*, 1991, 16-B, 208-221.
76. Person M. Causal treatment of lunatomalacia. *Acta Chir. Scand.*, 1950, 100, 531-544.
77. Ponsel T., Kreuzsch-Brinker R., Ahamadi A. Die arthroskopische Diagnostik der Handgelenksdiscusverletzung. *Z. Orthop.*, 1989, 127, 331-335.
78. Preiser G. Eine typische posttraumatische und zur spontanen Fraktur führende Osteitis des Naviculare Carpi. *Fortschr. Geb. Röntgenstr.*, 1910, 15, 189-197.
79. Rondier J., Cirotteau Y., Eftymion T., Premont M. Maladie de Madelung et lésions des tendons extenseurs. *Rev. Chir. Orthop.*, 1990, 76, 204-208.
80. Roth J., Poehling G. Arthroscopic "ectomy" surgery of the wrist. *Arthroscopy*, 1990, 6, 331-335.
81. Roth J. H., Haddad R. G. Radiocarpal arthroscopy and arthrography in the diagnosis of ulnar wrist pain. *Arthroscopy*, 1986, 2, 234-243.
82. Rosenmeyer B., Artman M., Vierstein K. Lunatumalacie : Nachuntersuchungsergebnisse und therapeutische Erwägungen. *Arch. Orthop. Unfall. Heilk.*, 1976, 85, 119-127.

83. Sanders R., Frederick H., Hontas R. The Sauvé-Kapandji procedure : a salvage operation for the distal radioulnar joint. *J. Hand Surg.*, 1991, 16-A, 1125-1129.
84. Sauve L., Kapandji M. Une nouvelle technique de traitement chirurgical des luxations récidivantes isolées de l'extrémité cubitale inférieure. *J. Chir.*, 1936, 47, 589-594.
85. Schattenkerk M., Nollen A., Van Hussen F. The treatment of lunatomalacia : radial shortening or ulnar lengthening ? *Acta Orthop. Scand.*, 1987, 58, 652-654.
86. Stahl S., Reis N. Traumatic ulnar variance and Kienböck's disease. *J. Hand Surg.*, 1986, 11-A, 95-96.
87. Steyers C., Blair W. Measuring ulnar variance : a comparison of techniques. *J. Hand Surg.*, 1989, 14-A, 607-612.
88. Sundberg S., Linscheid R. Kienböck's disease : results of treatment with ulnar lengthening. *Clin. Orthop.*, 1984, 187, 43-51.
89. Tada H., Hirayama T., Takemitsu Y. Extensor tendon rupture after osteoarthritis of the wrist associated with non-rheumatoid positive ulnar variance. *Clin. Orthop.*, 1991, 262, 141-147.
90. Taleisnik J. The Sauve Kapandji procedure. *Clin. Orthop.*, 1992, 275, 110-123.
91. Taylor T., O'Connor B. The effect upon the inferior radioulnar joint of excision of the head of the radius in adults. *J. Bone Joint Surg.*, 1964, 46-B, 83-88.
92. Tilberg B. Kienböck's disease treated with osteotomy to lengthen ulna. *Acta Orthop. Scand.*, 1968, 39, 359-368.
93. Tolat A., Sanderson P., De Smet L., Stanley J. The gymnast's wrist : acquired positive ulnar variance following chronic epiphyseal injury. *J. Hand Surg.*, 1992, 17-B, 678-681.
94. Trumble T., Glisson R., Seaber A., Urbaniak J. A biomechanical comparison of the methods for treating Kienböck's disease. *J. Hand Surg.*, 1986, 11-A, 88-93.
95. Uchiyama S., Terayama K. Radiographic changes in wrists with ulnar plus variance observed over a ten-year period. *J. Hand Surg.*, 1991, 16-A, 45-48.
96. Vanden Berghe A., De Grootte W., Vandekerckhove B. Traumatic radioulnar disorders treated with the Sauvé-Kapandji procedure. Presented at the BHG meeting. December 1991.
97. Van Den Eynde S., De Smet L., Fabry G. Comparison of arthrography and arthroscopy of the wrist. *J. Arthroscopy* (accepted for publication).
98. Vaughan-Jackson O. Rupture of extensor tendons by attrition of the inferior radio ulnar joint. *J. Bone Joint Surg.*, 1948, 30-B, 528-530.
99. Vender M., Watson H. Acquired Madelung-like deformity in a gymnast. *J. Hand Surg.*, 1988, 13-A, 19-21.
100. Verellen K. Personal communication. Presented at the "Pellenberg Orthopaedic Conference" 15 May 1992.
101. Vidal M., Linscheid R., Amadio P., Dobyns J. Preiser's disease. *Ann. Hand Surg.*, 1991, 10, 227-236.
102. Voche P., Bour C., Merle M. Scaphotrapezoid arthrodesis in the treatment of Kienböck's disease. *J. Hand Surg.*, 1992, 17-B, 5-11.
103. Watson H., Ruy J., Burgess R. Matched distal ulnar resection. *J. Hand Surg.*, 1986, 11-A, 812-817.
104. Watson H., Rijn J., Di Bella A. An approach to Kienböck's disease : triscapho arthrodesis. *J. Hand Surg.*, 1985, 10-A, 179-187.
105. Watson H., Hempton R. Limited wrist arthrodesis. I. The triscaphoid joint. *J. Hand Surg.*, 1980, 5, 320-327.
106. Weiss A., Weiland A., Moore J., Wilgis E. Radial shortening for Kienböck's disease. *J. Bone Joint Surg.*, 1991, 73-A, 384-391.
107. Werner F., Murphy D., Palmer A. Pressures in the distal radioulnar joint : effect of surgical procedures used for Kienböck's disease. *J. Orthop. Research*, 1989, 7, 445-450.
108. Whipple T. L., Marotta J. J., Powell J. h. Techniques of wrist arthroscopy. *Arthroscopy*, 1986, 2, 244-252.
109. Wun-Shen C., Chun-Hsiung S. Ulnar variance and Kienböck's disease. *Clin. Orthop.*, 1990, 225, 124-127.
110. Zachee B., De Smet L., Fabry G. The Sauvé Kapandji procedure. Paper presented at the Belgian Hand Group Meeting, Liège, Nov. 1992.
111. Zachee B., De Smet L., Fabry G. Arthroscopic suturing of TFCC lesions. *J. Arthroscopy*, 1993, 9, 242-243.
112. Zachee B., De Smet L., Fabry G. A snapping wrist due to a loose body : arthroscopic diagnosis and treatment. *J. Arthroscopy*, 1993, 9, 117-118.

SAMENVATTING

L. DE SMET. Overzicht artikel. Ulnar variance : feiten en verzinsels.

De relatieve lengte van de ulna of "ulnar variance" ten opzichte van de radius blijkt een belangrijke parameter te zijn. Deze ulnar variance wordt bepaald door erfelijkheidsfactoren, leeftijd, belasting van de pols (o.a. bij turners) en ernstige elleboogafwijkingen. Het bepalen van deze ulnar variance vereist gestandaardiseerde radiografieën en een reproduceerbare meettechniek. De korte ulna werd als etiologie geopperd voor het ontstaan van de ziekte van Kienböck, aseptische nekrose van het scaphoïd en scapholunaire dissociaties. Dit konden wij *niet* bevestigen. Daarentegen heeft een lange ulna wel een nefaste invloed op het ulnaire polscompartiment met degeneratie en perforatie van het ligamentum triangulare en kraakbeenletsels van de carpus. De ulnar variance bepaalt de morfologie van de sigmoid notch van de radius. Arthroscopie van de pols is een nuttig technisch onderzoek voor ulnaire polspijn.

RÉSUMÉ

L. DE SMET. Article de synthèse. Variantes morphologiques du cubitus : faits et fiction.

La longueur relative du cubitus par rapport au radius, ou la variance cubitale est un paramètre important. Cette longueur est déterminée par des facteurs génétiques héréditaires, l'âge, les sollicitations (p. ex. les gymnastes) et une éventuelle pathologie grave du coude. Pour déterminer cette variance cubitale, il faut disposer de radiographies standardisées et d'une technique

de mesure reproductible. Le cubitus court a été mis en rapport avec la maladie de Kienböck, la nécrose du scaphoïde et la dissociation scapho-lunaire. La statistique ne confirme pas cette hypothèse. Par contre le cubitus long induit une pathologie importante dans le compartiment cubital du poignet : perforation et dégénérescence du ligament triangulaire, lésions cartilagineuses des os du carpe. La variance cubitale détermine la morphologie de la facette articulaire interne du radius. L'arthroscopie du poignet est une technique fiable dans la mise au point d'une souffrance cubitale.