

OPERATIVE TREATMENT OF HUMERAL SHAFT FRACTURES

T. MULIER¹, D. SELIGSON¹, W. SIOEN², J. VAN DEN BERGH², P. REYNAERT²

The results of the operative treatment of 27 humeral shaft fractures treated at the University of Louisville during a 2-year period were reviewed. The aim of this study was to analyze 1) the indications and results of surgical treatment, 2) the indications for nailing versus plating, and 3) the failures and their treatment (especially surgical nonunions).

Indications for surgery were polytrauma patients (including open fractures, associated neurovascular injuries, associated ipsilateral forearm injuries) and isolated unstable fractures in which closed reduction failed. Plate and screw osteosynthesis was used in patients with proximal and distal fractures, in the presence of neurovascular injuries, progressive radial nerve palsy and failure of closed reduction due to interposition of soft tissue. Intramedullary antegrade nailing was preferentially used in polytrauma patients. Seven patients (25%) needed further surgery because of nonunion. The frequency was higher after plating (30%) than after nailing (20%), it was more common in comminuted fractures, middle third fractures and after insufficient distal locking. Exchange nailing resulted in union in 5 of the 7 cases.

Although excellent results with low complication rates are reported in the recent literature following plate and screw osteosynthesis or locked intramedullary nailing, we found that operative treatment of difficult humeral shaft fractures is still fraught with a high complication rate.

Keywords : humeral shaft fracture ; complications.

Mots-clés : fracture de l'humérus ; complications.

INTRODUCTION

The treatment of simple humeral shaft fractures is conservative as a rule (3, 4, 18, 25). Numerous studies report excellent functional results after careful nonoperative treatment, and the role of

surgical treatment in isolated humeral fractures remains controversial (18, 20, 25). Fracture fragments are well vascularized, and according to different authors malunions with angulations up to 20° are functionally well tolerated (18, 25). The incidence of nonunion after open reduction has been reported to be from 0 to 20% compared with 0 to 8% after conservative treatment (4, 8). Furthermore, in the patients where conservative treatment fails, even operative intervention is not very successful (26). Schwartz noted only a 66% union rate after operative treatment in patients where initial nonoperative treatment failed.

However, in a trauma center one has to deal with multiple trauma patients, unstable transverse fractures ; fractures in association with limb-threatening injuries and associated ipsilateral forearm fractures. These types of injuries are difficult to manage with conservative treatment and are considered an indication for operative treatment (3, 10, 11, 17, 21, 23, 24, 27-31).

Comparison between conservative and operative treatment methods may be difficult, since operative treatment is often reserved for problem fractures (28). Furthermore the natural history after conservative treatment of complex humeral shaft fractures may not be as favorable as previously reported, and in one recent retrospective report a nonunion rate of more than 20% was noted after conservative treatment (9). With recent advances in fracture fixation techniques (32) and biomate-

¹ Department of Orthopedic Surgery, University of Louisville, South Jackson Street, 40292 KY, USA.

² Orthopedic Surgery, H. Hartziekenhuis, Naamsestraat 105, 3000 Leuven, Belgium.

Correspondence and reprints : T. Mulier.

rials (6,32), most of the studies report success rates between 90 to 100% after surgical treatment with few complications, and union after a mean of 12 weeks (25, 27).

Plate and screw osteosynthesis is considered to be an appropriate choice with good final results reported by many authors in acute fractures as well as in nonunions (3, 7, 8, 15, 18, 19, 24). It allows for anatomical reposition of most fractures with little risk of mechanical problems or failure of healing. In a multicenter study Foster and Dixon reported a 100% union rate in 27 multiple-injury patients and above 80% union rate in 10 patients with a nonunion (8).

There is however danger to the radial nerve which must be exposed at the time of primary surgery and during elective removal of the plate after union. Plate fixation may also be difficult in complex fractures (17, 18, 25, 26).

Other authors advocate the use of locked antegrade or retrograde intramedullary nailing in acute humeral shaft fractures as well as in nonunions (6, 10, 11, 14, 22-32). It provides semirigid fixation depending on the size, location and comminution of the fracture. Most of the recent studies, using intramedullary nailing, report success rates from 94 to 100% provided that proper techniques and reasonable nail designs are used (25, 27). Some studies report less favorable results, owing to problems of nail design (26). Violation of the rotator cuff in an antegrade insertion, encroachment of the olecranon fossa with extension block in retrograde insertion, or possible malalignment and shortening may be the major drawbacks of intramedullary nailing (25, 29).

Nonunion after surgical treatment of acute humeral shaft fractures is not infrequent. However the treatment of nonunions after failed surgery has been addressed only anecdotically in the literature (7, 8).

According to some authors plating is considered the treatment of choice in nonunion after conservative treatment (1, 2) and nonunion after surgery (1, 7). With the development of the Seidel nail, two reports have described the treatment of nonunions after surgery with this device with a mixed

outcome (22, 26). Locked intramedullary nails and ring external fixators (17) have been used in humeral nonunions after surgery, but no results of these methods have been found in literature.

In light of these recent advances in operative fracture care, the aim of this study was primarily to review the indications and results of patients treated with locked intramedullary nailing and compression (transverse fractures) or bridging plating (comminuted fractures) at the University of Louisville Hospitals.

Secondarily, the study also addressed the failures (nonunions) after surgical treatment and the salvage procedures which were used.

MATERIAL AND METHODS

During a 2-year period (1991 to 1993) 55 patients were seen with a humeral shaft fracture (fracture line ending at least 3 cm above the elbow diaphysis-metaphysis and 4 cm below the surgical neck). Twenty-seven of these fractures were surgically treated. None of the patients was lost to follow-up. All fractures included in the study were treated by the senior author (D. S.). Open Gustilo type 3 fractures, proximal fractures within 4 cm of the surgical neck, distal fractures within 3 cm of the diaphysis-metaphysis junction and shaft fractures extending into the greater tubercle were excluded from this series. The indications for operative treatment were multiple trauma patients (n=18), including associated ipsilateral forearm fractures (n=3), open fractures (n=5), and unstable isolated fractures with failure of closed treatment (n=9). Three polytrauma patients with nonprogressive radial paresis (9%) were operated because of associated injuries.

The fractures were unilateral in 23, and bilateral in 2 cases. Associated upper limb fractures included three double forearm, three elbow, one radial head and one proximal humerus fracture. Fractures were classified as transverse (27%), oblique (24%), spiral (12%), segmental (10%) and comminuted in 27%.

The mechanism of injury reflects the patient population at a level-one trauma center ; 75% were high injury trauma (including 70% motor vehicle

injuries), 11% gunshots, 11% falls and 3% sports-related injuries. Eighteen percent (5 cases) were open fractures (Gustilo grade 1 : 3 cases, grade 2 : 2 cases).

Primary internal fixation or nailing was performed in 10 patients within 48 hours of injury. Twelve patients had their fractures stabilized after two days and 5 patients were stabilized after failure of first treatment between three days and six weeks.

Generally nailing was the method of choice in polytrauma patients with midshaft and comminuted fractures. Plating was used in long spiral fractures, shaft fractures closer to the humeral neck (5cm) and the elbow (5cm) and in fractures with soft tissue interposition.

Patients were closely followed during the rehabilitation period with clinical and radiographic review at 1, 2 and 6 weeks, 3 months, 6 months and 1 year until solid bony union could be determined. The average follow-up was 24 months (range 14 to 47 months).

OPERATIVE TECHNIQUE

Plating

A posterior approach was used in a prone position; the humeral shaft was exposed by splitting the triceps in its middle third. After identification and careful retraction of the radial nerve, an anatomical reduction was performed and provisionally stabilized. Plate and screw osteosynthesis was done in all 12 cases with compression or bridging plating with primary bone grafting. Tibial plates with a minimum of 7 holes were used and fixed with at least 3 cortical screws above and below the fracture. After definitive stabilization radiographic confirmation was obtained intraoperatively.

Nailing

Closed antegrade nailing was performed with Russell-Taylor humeral nails (Richards, Smith and Nephew, Memphis, Tennessee, USA). The

patients were positioned supine with the upper arm on a radiolucent side table. A 2-cm split was made in the deltoid in line with its fibers. Access to the medullary canal was sought through the greater tuberosity, and with a hand reamer, the medullary canal was prepared to 10 mm. An 8- or 9-mm appropriately sized nail was inserted over a guide wire and locked with two self-tapping screws under fluoroscopic guidance, the distal from anterior to posterior. Particular efforts were made to avoid the use of a hammer to prevent any further fracture comminution. Postoperatively a sling was used for 2 weeks, and active external rotation was restricted until early callus formation was seen.

RESULTS

We studied 27 fractures; all but 2 finally obtained bony union. The mean healing time (radiologically) for all fractures was 16 weeks (range 8 to 65 weeks).

Functional assessment (5) demonstrated decreased abduction and flexion of the shoulder after antegrade nailing compared to the plated patients (mean abduction 115° compared with 135°, flexion 125° compared with 150°). External rotation of the shoulder, pronation and supination and flexion/extension of the elbow were slightly decreased (less than 10°) in 30% of the patients.

Radiographic examination at final review demonstrated a 1.3-cm shortening of the humerus in 2 patients, and malunion in internal rotation in one patient after nailing.

Complications

Transient radial nerve paresis was seen in 3 patients, and secondary radial nerve paresis in 2 cases after plating of long spiral fractures.

Failures

In the plating group 4 nonunions were seen (30%); in the nailing group nonunions were observed in 3 cases (20%).

SALVAGE PROCEDURES AND CASE REPORTS

The 4 cases of nonunion following plating were treated by plate removal, cancellous grafting and locked nailing.

In 2 cases with nonunions after nailing, removal of the nail and compression plating was performed. In these cases nailing did not provide sufficient stability (8-mm nails). In the third case, the nail was exchanged for a thicker, overreamed nail. Finally healing was observed in 5 of the 7 cases, 1 to 6 months after revision surgery. In 2 patients union was never achieved (respectively after 2 and 4 years) after revision of a plating to a nailing procedure.

No further treatment is planned in these 2 patients. The first patient (case 1) refuses further operative treatment ; the second patient, is asymptomatic (case 2).

Case 1

A 46-year-old female with bilateral midshaft fractures and an associated elbow fracture was treated with bilateral plate and screw osteosynthesis. Excellent stability and compression were obtained on both sides.

After 9 months union was seen on the left side, but a nonunion resulted on the right side (fig. 1a ; b). A 9 mm intramedullary nail (supplemented with bone grafts) was placed after removal of the plate and screws. Distal locking was performed with one screw owing to the distal localization of the fracture. The screw backed out after 3 weeks resulting in severe pain and instability. After revision of the distal interlocking with a Kuntschner bolt technique (fig. 1c), stability was achieved. Healing was however not observed in the following months. After 18 months extraction of the nail, bone grafting and plating had to be performed. Complete union of the fracture was not achieved after 26 months.

Case 2

A 47-year-old man with a transverse isolated

humerus fracture was treated initially with plate and screw osteosynthesis and bone grafting.

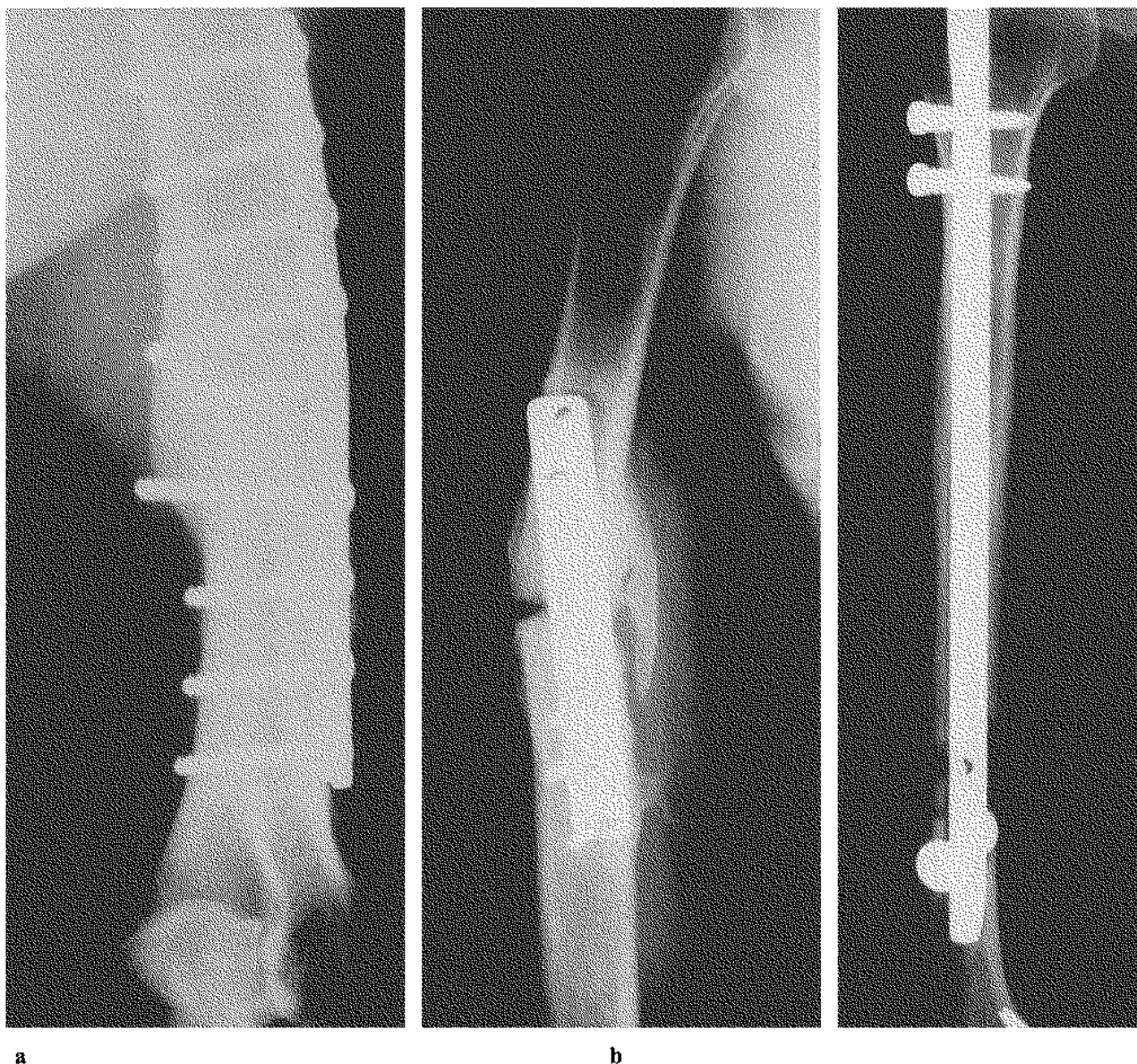
At 7 months supplementary grafts were added (fig. 2a). A persistent nonunion was seen, and 7 months later a Russell-Taylor nail was placed (10 mm). This nail was exchanged 11 months later. An 11 mm Huckstep nail was placed with slow healing of the fracture side. At present however no solid union can be observed (fig. 2b).

DISCUSSION

Operative treatment of humeral shaft fractures has been associated with a significantly higher complication rate than conservative treatment owing to infection, nonunion, radial or axillary nerve injury, and the need for additional procedures (4, 15, 21, 23, 25, 28, 29). This higher complication rate can be partially explained by unsatisfactory stability (Ender and Rush pins), and unsatisfactory nail design (Seidel nail), but also by invalid comparison between different treatment methods (28). Operative treatment was often reserved for problem fractures or polytrauma patients (28).

Currently the treatment of choice in simple humeral shaft fractures is conservative (3, 4, 8, 25). Compression plating and locked intramedullary nailing are considered in unstable fractures, polytrauma patients, or patients with ipsilateral or associated neurovascular injuries (3, 11, 15, 22, 24, 25, 27, 28, 29).

Indications for surgery in our series were the same as those described by Foster(8) ; fractures in polytrauma patients (open fractures, bilateral fractures, ipsilateral fractures on the upper limb or associated vascular injuries) and in patients with an inadequate reduction of the humerus shaft after closed reduction. Polytrauma in our series was by far the most frequent indication : patients with associated lower extremity injuries, head or spine injuries need a stable arm for walking with crutches or using a wheelchair. Inadequate closed reduction of the fracture due to muscle or nerve interposition, severe comminution and failure to align fracture fragments by closed reduction was the next most frequent indication.



a

Fig. 1. — Bilateral broad plates with primary bone grafts were applied for midshaft humeral fractures in a polytrauma patient. Excellent stability was obtained on both sides (a). A nonunion resulted on the right side (b), which was treated with a 9-mm intramedullary nail. Distal locking was difficult

b

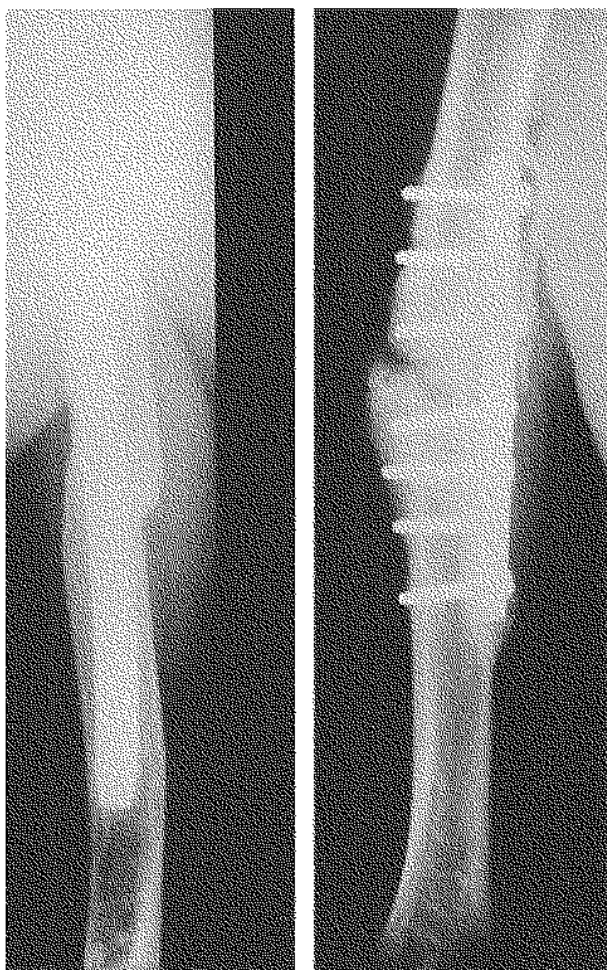
owing to the localization of the fracture. The distal screw backed out and was replaced with a Kuntschner bolt (c). Rotational stability was not achieved. A further revision to a plate had to be performed.

c

Plates were used in more distal or proximal fractures, soft tissue interposition or in fractures with associated neurovascular lesions. Open fractures with neurovascular lesions were treated with open reduction, plating and microsurgical repair. Total radial nerve palsy in closed fractures was

not an absolute indication for open reduction, while progressive radial nerve palsy was considered a primary indication for open reduction and plating.

Nailing was performed in comminuted, midshaft, osteoporotic or open grade I fractures and



a **b**
Fig. 2. — This 47-year-old male sustained a right humerus fracture, which was plated (8-hole tibial plate). A nonunion resulted which was bone grafted (a). Seven months later the plate was removed, and an antegrade nailing was performed with placement of a 9-mm Russell-Taylor nail. This was exchanged 11 months later for an 11-mm Huckstep nail because of persistent nonunion. Slow subsequent healing was seen; however solid union cannot be observed after 51 months (b). These two cases demonstrate the mixed outcome after treatment of a surgical nonunion with intramedullary nailing (and bone grafting).

in polytrauma patients. Patients with associated lower limb fractures were able to use crutches that axially loaded the humeral shaft resulting in a higher union rate (8).

By analyzing our results and complications, we found a high (25%) nonunion rate. In the literature the incidence of nonunions after surgery varies

between 5 and 25% (1, 2, 14, 19). An explanation for our nonunion rate is not clearly found. According to the literature causes of aseptic nonunion after surgical treatment are unstable osteosynthesis, muscle interposition, and avascular bone (1, 2, 19). Inferior fixation methods with damage to the vascular supply are probably the most important factor associated with nonunions (19). In our series all procedures were performed by or under supervision of the senior author (D. S.), with bone grafting and careful soft tissue handling. Postoperative roentgenograms were satisfactory, demonstrating a stable osteosynthesis. An explanation may be that surgical treatment in our patients was reserved for difficult fractures and patients with multiple injuries. In some complex comminuted fractures uneventful healing could probably not be expected. Unstable transverse fractures of the middle third were more prone to nonunion than fractures in more distal or proximal parts (fig. 1, 2).

Only a few studies address the problem of nonunion after surgery (7, 8, 12, 17, 22, 26). Most authors report 80-100% union rates after rigid internal fixation in humeral nonunions. Fattah (7), Foster (8) and Healy *et al.* (12) recommend the use of rigid internal fixation with compression plates (with at least 6 cortices above and below the nonunion), decortication and autologous bone grafting as the best solution in nonunions after conservative and operative treatment. According to Healy *et al.* (12), intramedullary nailing is not a good method to achieve adequate fixation in long bones of the upper limb (only 70% union rate).

On the other hand, Pietu *et al.* (22) reported 5 cases of delayed unions treated with a locking nail. Exchange interlocking nailing appeared to be the most useful salvage procedure in their series. It obviated the need for bone grafting and avoided local injury to the radial nerve. Union occurred in all cases despite distal unscrewing in some cases. In our 5 exchange nailings for nonunions (fig. 1, 2) no complications were seen, but only 3 fractures healed quickly and uneventfully. A recent report by Schwartz *et al.* (26), using intramedullary nails as a treatment for surgical nonunions, confirmed our mixed results using this treatment method (66% union rate).

Recently Lammens *et al.* (17) reported their experience with ring external fixators in 31 humeral nonunions after failed (conservative and operative) treatment and in infected nonunions. Union was achieved in all cases.

CONCLUSIONS

1. The operative treatment of acute humeral shaft fractures is still fraught with a high complication rate, even with current fracture fixation techniques.

2. The ideal treatment plan of a surgical nonunion of the humeral shaft is still open for considerable debate. Compression plating and ring external fixators (in infected nonunions) seem to be the treatment of choice.

REFERENCES

1. Barquet A., Fernandez A., Luvizio J., Masliah R. A combined therapeutic protocol for aseptic nonunion of the humeral shaft : A report of 25 cases. *J. Trauma*, 1989, 29, 95-98.
2. Beguin J. M., Plenevaux P., Poilvache G. Considérations à propos du traitement des pseudarthroses de l'humérus. *Acta Orthop. Belg.*, 1991, 57, 114-122.
3. Brug E., Westphal T., Schafers G. : Differenzierte Behandlung der Humerusdiaphysenfrakturen. *Unfallchirurg.*, 1994, 97, 633-638.
4. Christensen S. Humeral shaft fractures : Operative and conservative treatment. *Acta Chir. Scand.* 1967,133, 455-460.
5. Constant C. R., Murley A. H. G. A clinical method of functional assessment of the shoulder. *Clin. Orthop.*, 1987, 214, 160-164.
6. Dalton J. E., Salkeld S. L., Satterwhite Y. E., Cook S. D. A biomechanical comparison of intramedullary nailing systems for the humerus. *J. Orthop. Trauma*, 1993, 7, 367-374.
7. Fattah A., Halawa E., Shafy T. A. Nonunions of the humeral shaft : A report on 25 cases. *Injury*, 1985, 14, 256-262.
8. Foster R. J., Dixon G. L., Bach A. *et al.* Internal fixation of fractures and nonunions of the humeral shaft *J. Bone Joint Surg.* 1985, 67-A, 6, 857-864.
9. Foulk D. A., Szabo R. M. Diaphyseal humerus fractures : Natural history and occurrence of nonunion, *Contemp. Orthop.*, 1995, 18, 31-36.
10. Gallagher J. E., Keogh P., Black J. Humeral medullary nailing - A new implant. *Injury* 1988, 19, 254-256.
11. Habarnek H., Orther E. A locknail for fractures of the humerus. *J. Bone Joint Surg.*, 1991, 73 B, 651-653.
12. Healy W., White G., Mick C., Brooker J., Weiland A. Nonunion of the humeral shaft. *Clin. Orthop.*, 1987, 219, 207-212.
13. Henley M. B., Monroe M., Tencer A. F. Biomechanical comparison of the methods of internal fixation of a mid-shaft osteotomy of the humerus. *J. Orthop. Trauma*, 1991, 5, 14-20.
14. Ingman A. M., Waters D. A. Locked intramedullary nailing of humeral shaft fractures. *J. Bone Joint Surg.* 1994, 76 B, 23-29.
15. Jupiter J. B. Complex non-union of the humeral diaphysis, treatment with a medial approach, an anterior plate, and a vascularised fibular graft. *J. Bone Joint Surg.* 1990, 76 A, 701-707.
16. Kùntscher G. Practice of intramedullary nailing, Springfield, IL, C. C. Thomas, 1967, pp. 5-72.
17. Lammens J., Baudoin P. Driessen R., Desmet L., Fabry G. Treatment of complex humeral shaft nonunions with ring fixators, *Clin. Orthop.* (in press), 1996.
18. Link W., Henning F. Indikation und Osteosyntheseverfahren bei Humerusschaftfrakturen. *Akt. Traumatol.*, 1988, 18, 120-124.
19. Loomer R., Kokan P. Non-union in fractures of the humeral shaft. *Injury*, 1976, 7, 274-278.
20. Mc Kee D. Retrograde locked nailing of humeral shaft fractures. Letter to the editor. *J. Bone Joint Surg.*, 1995, 77-B, 667.
21. Mast J. W., Spiegel P. G., Harvey J. P. Fractures of the humeral shaft. A retrospective study of 240 adult fractures. *Clin. Orthop.*, 1975, 112, 254-262.
22. Pietu G., Raynaud G., Letenneur J. Treatment of delayed and nonunions of the humeral shaft using the Seidel locking nail : A preliminary report of five cases. *J. Orthop. Trauma*, 1994, 8, 240-244.
23. Robinson C. M., Bell K. M., Court-Brown C. M., Macqueen M. M. Locked nailing in humeral shaft fractures, experience in Edinburgh over a two year period. *J. Bone Joint Surg.*, 1992, 74-B, 558-562.
24. Rommens P. M., Vansteenkiste F., Stapperts K. H., Broos P. L. O. Indikationen, Gefahren und Ergebnisse der operativen Behandlung von Oberarmschaftfrakturen. *Unfallchirurg* 1989, 92, 565-567.
25. Rommens P. M., Verbruggen J., Broos P. L. Retrograde locked nailing of humeral shaft fractures. *J. Bone Joint Surg.*, 1995, 77-B, 84-89.
26. Schwartz N., Posch E. Seidel interlocking nailing for healing problems in humeral shaft fractures. *Injury*, 1995, 26, 13-16.
27. Seidel H. Humeral locking nail : A preliminary report. *Orthopedics*, 1989, 12, 219-226.
28. Vander Griend R. A., Ward E. F., Tomasin J. Closed Kùntscher nailing of the humerus. *J. Trauma*, 1985, 25, 1167-1169.
29. Varley G. W. The Seidel locking humeral nail : The Nottingham experience. *Injury*, 1995, 26, 155-157.
30. Ward E. F., White J. L. Interlocked intramedullary nailing of the humerus. *Orthopedics* 1989, 12, 135-141.

31. White P., Ward E. F. Küntscher nailing of the humerus. In : Concepts in Intramedullary Nailing, ed. Seligson D., Philadelphia, Lea & Febiger, 1987, 319-323.
32. Zimmerman M., Waite A., Deehan M., Tovey J., Oppenheim W. A biomechanical analysis of four humeral fracture fixation systems. J. Orthop. Trauma, 1994, 8, 233-239.

SAMENVATTING

T. MULIER, D. SELIGSON, W. SIOEN, J. VAN DEN BERG, P. REYNAERT. Operatieve behandeling van humerus schaft fracturen : Indicaties, resultaten en complicaties.

We hebben de resultaten van zeven en twintig operatief behandelde patienten met een humerusschaf fractuur, gezien gedurende 1992 en 1994 in de trauma ziekenhuizen van Louisville, geanalyseerd.

Het doel van onze studie was voornamelijk gericht op het bestuderen van de indicaties en resultaten na operatieve behandeling, en de respectievelijke indicaties voor plaat versus nagel behandeling.

Verder werd een analyse gemaakt van de complicaties, *in casu* nonunions, en van hun behandeling.

De voornaamste indicaties voor een chirurgische behandeling waren polytrauma patiënten en geïsoleerde instabiele fracturen waarbij gesloten reductie faalde.

Plaatosteosynthese werd voornamelijk gebruikt in patienten met meer proximale en distale fracturen, in de aanwezigheid van neurovasculaire letsels, progressieve uitval van de nervus radialis en falen van een gesloten reductie door weke weefsel interpositie.

Intramedullaire nagels werden bij voorkeur gebruikt in polytrauma patienten.

Zeven patienten (25%) hadden verdere chirurgie nodig omwille van een nonunion.

De frequentie was hoger :

- 1) bij plaatosteosynthese (30%) dan bij intramedullaire nagel,
- 2) in communitieve fracturen,
- 3) middenste derde fracturen,
- 4) en onvoldoende distale vergrendeling.

Als conclusie kunnen we stellen dat, hoewel in de literatuur uitstekende resultaten worden beschreven na plaatosteosynthese of vergrendelde nageling, in onze serie de operatieve behandeling van humerus schaft fracturen nog steeds een hoge complicatiegraad heeft.

RESUME

T. MULIER, D. SELIGSON, W. SIOEN, J. VAN DEN BERG, P. REYNAERT. Traitement opératoire des fractures de la diaphyse de l'humérus : indications, résultats et complications.

Les auteurs présentent les résultats du traitement opératoire de vingt-sept fractures de la diaphyse de l'humérus, traitées à l'Université de Louisville pendant une période de deux ans. Le but de cette étude est essentiellement une revue des indications et des résultats du traitement chirurgical ainsi que des indications respectives de l'enclouage et de la fixation par plaque. D'autre part les auteurs analysent les échecs de la chirurgie et leur traitement. L'indication chirurgicale fut posée chez les patients polytraumatisés (incluant les fractures ouvertes, les traumatismes neurovasculaires ainsi que les lésions homolatérales de l'avant-bras) et les fractures instables isolées où la réduction fermée avait échoué. L'ostéosynthèse par plaque vissée fut utilisée chez des blessés présentant une fracture proximale ou distale, en cas de traumatisme neurovasculaire, de paralysie nerveuse radiale progressive et d'échec de réduction à foyer fermé en raison de l'interposition de tissu mou. L'enclouage intramédullaire antérograde a été utilisé de façon préférentielle chez les polytraumatisés.

Sept patients (25%) nécessitèrent une chirurgie ultérieure par suite de pseudarthrose.

La fréquence des pseudarthroses fut plus élevée :

- 1) après l'utilisation d'une plaque (30%) que d'un clou (20%),
- 2) en cas de fracture comminutive,
- 3) en cas de fracture du tiers moyen,
- 4) après verrouillage distal insuffisant.

Le réenclouage après pseudarthrose sur clou donna un résultat favorable dans cinq cas sur sept.

Malgré les excellents résultats rapportés dans la littérature récente après ostéosynthèse par plaque vissée ou par clou intramédullaire verrouillé, nous constatons que le traitement opératoire des fractures diaphysaires de l'humérus est encore grevé d'un taux élevé de complications.