

AVASCULAR NECROSIS OF THE CARPAL SCAPHOID : PREISER'S DISEASE REPORT OF 6 CASES AND REVIEW OF THE LITERATURE

L. DE SMET¹, P. AERTS², M. WALRAEVEN³, G. FABRY¹

Six cases of nontraumatic avascular necrosis of the scaphoid are reported. Two cases were due to chronic steroid intake with several other sites of bone necrosis ; for the other 4 cases no etiology could be established. Four were treated with a proximal row carpectomy, 3 with a very satisfying result, whereas one had to be converted into a wrist arthrodesis.

Keywords : wrist ; scaphoid ; avascular necrosis ; proximal row carpectomy ; Preiser's disease ; resection arthroplasty.

Mots-clés : poignet ; scaphoïde ; nécrose aseptique ; résection de la première rangée ; maladie de Preiser.

INTRODUCTION

Idiopathic avascular necrosis of bone in the hand and wrist usually involves the lunate. Despite the frequency of necrosis of the proximal pole in scaphoid fractures, and its vascularity at risk (8), the scaphoid is rarely involved in idiopathic bone necrosis. On several occasions the condition has been related to systemic disease and/or steroid ingestion (12, 19) chemotherapy (10) and hypoplasia of the scaphoid (15, 19). This paper reports 6 additional cases.

MATERIAL

Preiser's disease was diagnosed when no history of trauma was present, and when radiological alterations of the entire scaphoid, or MRI and/or histological

evidence of necrosis in the distal part of the scaphoid were seen. We have seen 6 patients fulfilling these criteria.

The important features are summarized in table I. All presented with pain in the radial compartment of the wrist. None recalled even a minor injury, and none was a manual labourer exposed to repetitive and/or severe mechanical stress.

Cases 4 and 5 had an MRI investigation that confirmed the diagnosis.

Radiographs revealed condensation, cyst formation and fragmentation of the scaphoid. Ulnar variance ranged from - 4 mm to + 1 mm (mean - 0.67) with 3 ulnar minus variants, 2 ulnar plus variants and 1 neutral variant.

Four required surgical treatment. A proximal row carpectomy (9, 14) was our first choice (4). Three had an excellent result, whereas one had a poor outcome, requiring further surgery (wrist fusion).

DISCUSSION

The blood supply of the scaphoid has been studied by Taleisnik and Kelly (18) and Gelberman *et al.* (7, 8). Both could demonstrate a blood supply at risk, irrigated by a dorsolateral branch of the radial artery.

¹ Department of Orthopaedics, University Hospital Pellenberg, K.U. Leuven, B-3212 Pellenberg.

² Department of Orthopaedics, Maria Middelaars Ziekenhuis, Lommel, Belgium.

³ Department of Rheumatology, University Hospital Pellenberg, K.U.L.

Correspondence and reprints : L. De Smet.

Table I

	scx/age	side affected	UV	treatment	Results	Risk factors
1.	F 27	R	- 4	PRC	Good	None
2.	F 37	L	- 1	PRC	Good	None
3.	F 33	L	+ 1	PRC	Good	Renal Transplant
4.	M 60	L	+ 1	1. PRC 2. A-desis	Poor	Steroid Intake
5.	F 65	R	- 3	-	Fair	None
6.	M 40	L	0	-	-	None

PRC : proximal row carpectomy ; A-desis : arthrodesis ; UV : ulnar variance.

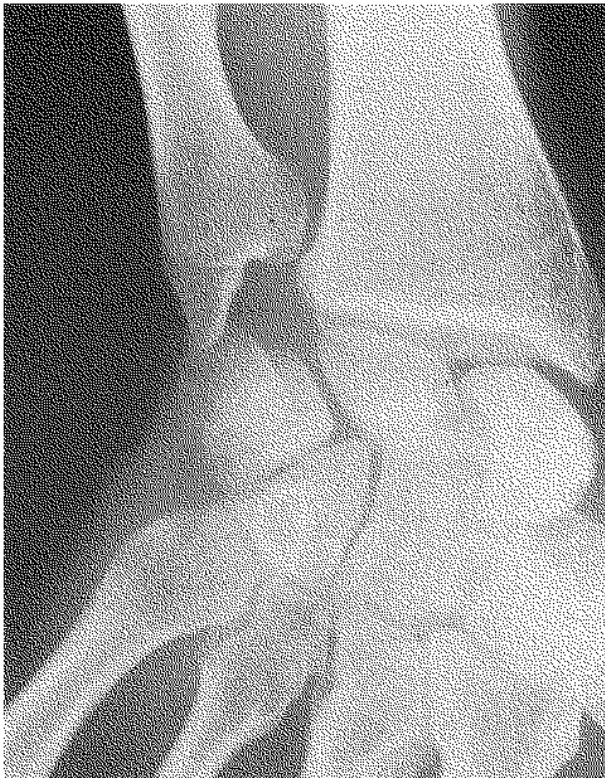

Fig. 1a

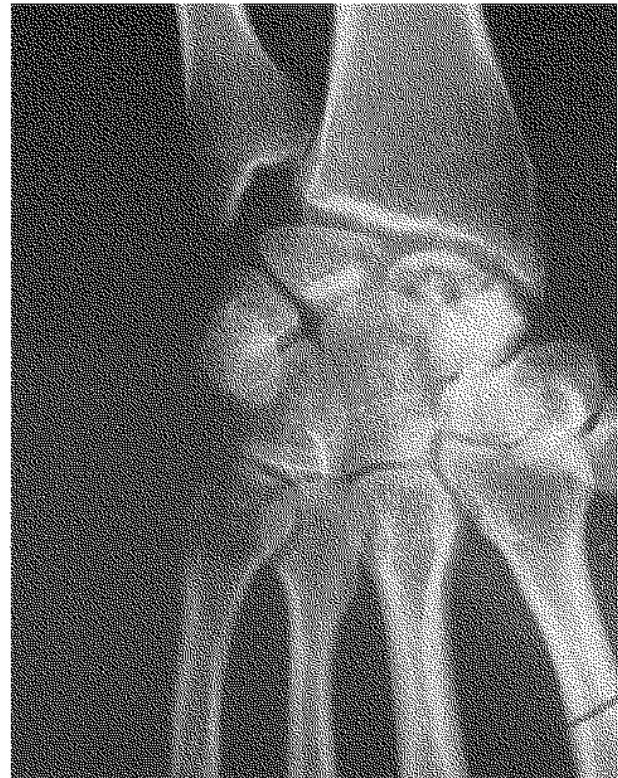


Fig. 1b

Fig. 1. — Case 1, a : in 1988, b : in 1991.

The distal pole has supplementary vascularization and is better protected against bone infraction. Avascular necrosis of the scaphoid has been called Preiser's disease, based on his publications in 1910 and 1911 (16, 17). Since then only a limited number of cases has been reported (1-6, 10-12).

Vidal *et al.* in 1991 (19) published the largest series (9 cases) so far ; however one had a mal-united scaphoid.

The association in 3 cases (15, 19) with a hypoplastic scaphoid cannot be coincidental and must be looked for. Such hypoplastic scaphoids may

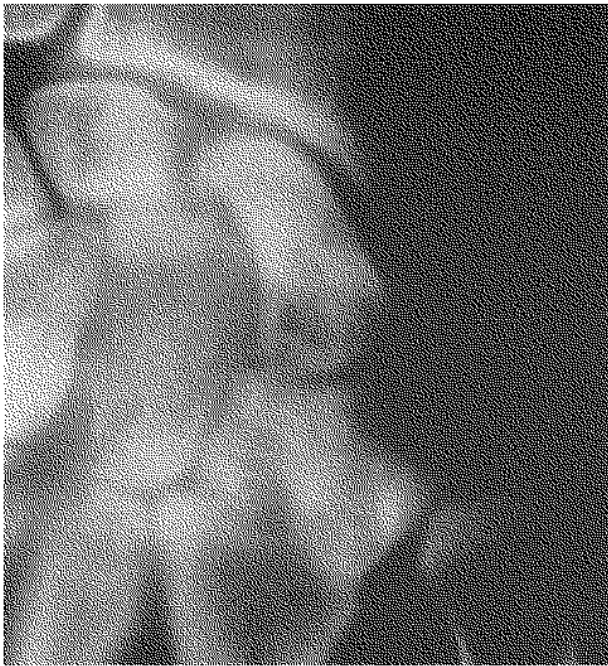

Fig. 2. — Case 2 typical X-ray finding.

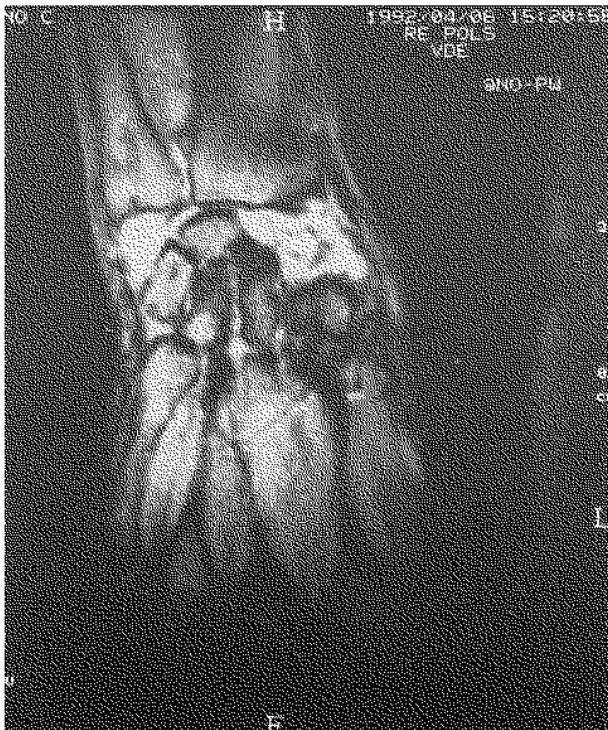


Fig. 3. — Case 5 MRI aspect.

be submitted to greater pressures or might be more vulnerable than in normal situations. In all our cases however the morphology of the scaphoid was normal.

The association with a negative ulnar variance was suggested by Parkinson *et al.* (15) but later refuted by Vidal *et al.* (19). The role of negative ulnar variance was determined by comparing the incidence of ulna minus in a group compiled from the published cases of Preiser's disease (1, 2, 3, 6, 15), Vidal's series (19) and ours, excluding those with an obvious external cause, and the incidence of ulna minus in a large population measured by Nakamura *et al.* in 1991 (13) (table II). The breakdowns are similar. The chi-square test was not significant ($p > 0.1$). The influence of negative ulnar variance can be excluded as an element in the pathogenesis.

Table II

	Preiser	Nakamura <i>et al.</i> (12)
<i>Ulna minus</i>	9 (39%)	32.2%
<i>Ulna zero</i>	9 (39%)	39.3%
<i>Ulna plus</i>	5 (22%)	27.1%

Treatment is still under discussion. Conservative measures (NSAID's, rest and splinting) are recommended initially, but the outcome is not very convincing (19). Scaphoid excisions, partial or total, with or without replacement have been reported occasionally. In our opinion a choice has to be made between proximal row carpectomy, a full wrist fusion, a four-part bone fusion (lunate-capitate-triquetrum and hamate) with scaphoid resection (20) or a denervation of the wrist.

Our good results with proximal row resection in other conditions of the wrist was a stimulus to extend the indications, not only as a salvage procedure but as a primary reconstructive treatment, i.e. for Preiser's disease. This technique has been confirmed recently by Alnot *et al.* (2).

REFERENCES

1. Allen P. Idiopathic avascular necrosis of the scaphoid. *J. Bone Joint Surg.*, 1983, 65-A, 333-335.

2. Alnot J. Y., Frayman J. M., Bocquet L. Les ostéonécroses aseptiques primitives totales du scaphoïde. À propos de 3 cas. *Ann. Chir. Main Membre Super.*, 1990, 9, 221-225.
3. Bray T., Carroll H. Preiser's disease : a case report. *J. Hand Surg.*, 1984, 9-A, 730-732.
4. De Smet L., Aerts P., Fabry G. Avascular necrosis of the carpal scaphoid. Report of 3 cases treated with a proximal row carpectomy. *J. Hand Surg.*, 1992, 17-A, 907-909.
5. Elkerot L., Eiken O. Idiopathic avascular necrosis of the scaphoid : a case report. *Scand. J. Plast. Reconstr. Surg.*, 1981, 15, 69-72.
6. Ferlic D., Morin P. Idiopathic avascular necrosis of the scaphoid : Preiser's disease ? *J. Hand Surg.*, 1989, 14-A, 13-16.
7. Gelberman R., Menon J. The vascularity of the scaphoid bone. *J. Hand Surg.*, 1980, 5, 508-513.
8. Gelberman R., Gross M. The vascularity of the wrist. *Clin. Orthop.*, 1986, 202, 40-49.
9. Green D. Proximal row carpectomy. *Hand Clinics*, 1987, 3, 163-168.
10. Harper P., Radk C., Souhami R. Avascular necrosis of bone caused by combination chemotherapy without corticosteroids. *Br. Med. J.*, 1984, 288, 267-268.
11. Helbig B., Almeling M. Long-term results of treatment of rare aseptic necrosis of the scaphoid bone (Preiser disease) with the Swanson implant. *Handchir. Mikrochir. Plast Chir.*, 1989, 21, 178-81.
12. Kawai H., Tsuyuguchi Y., Yonenobu K., Inoue A., Tada K. Avascular necrosis of the carpal scaphoid associated with a progressive systemic sclerosis. *Hand*, 1983, 15, 270-273.
13. Nakamura R., Tanaka Y., Amaeda T., Miura T. The influence of age and sex on ulnar variance. *J. Hand Surg.*, 1991, 16-B, 81-88.
14. Neviasser R. On resection of the proximal row. *Clin. Orthop.*, 1986, 202, 12-15.
15. Parkinson R., Noble J., Bale R., Freemont. Rare abnormalities of the scaphoid in association with congenital radial ray defects of the hand. *J. Hand Surg.*, 1991, 16-B, 208-211.
16. Preiser G. Eine typische posttraumatische und zur Spon-tanfraktur führende Osteitis des Naviculare carpi. *Fort-schr. Geb. Roentgenstr.*, 1910, 15, 189-197.
17. Preiser G. Zur Frage der typische traumatische Erna-trungsstörungen der kurzen Hand- und Fuss-Wurzelkno-chen. *Fortshr. Geb. Rontgenstr.*, 1911, 17, 360-362.
18. Taleisnik J., Kelly P. The extraosseous and intraosseous blood supply of the scaphoid bone. *J. Bone Joint Surg.*, 1966, 48-A, 1125-1137.
19. Vidal M., Linscheid R., Amadio P., Dobyns J. Preiser's Disease. *Ann. Hand Upper Limb Surgery*, 1991, 10, 227-236.
20. Watson H., Ballet F. The SLAC wrist : scapholunate advanced collapse pattern of degenerative arthritis. *J. Hand Surg.*, 1984, 9-A, 358-65.

SAMENVATTING

L. DE SMET, P. AERTS, M. WALRAEVENS, G. FABRY. Avasculaire necrosis van het scaphoid. Ziekte van Preiser over 6 gevallen en bespreking van de literatuur.

Zes gevallen van niet-traumatische avasculaire necrose van het scaphoid worden beschreven. Bij twee van hen was er een chronische corticoidtherapie ; bij de vier anderen waren er geen enkele risikofactor. Bij 4 werd er een proximale rij-resectie uitgevoerd, 3 met uitstekend resultaat, bij 1 diende de pols te worden gefusioneerd.

RÉSUMÉ

L. DE SMET, P. AERTS, M. WALRAEVENS, G. FABRY. Nécrose aseptique du scaphoïde carpien. Maladie de Preiser. Présentation de 6 cas et revue de la littérature.

Six cas de nécrose aseptique atraumatique sont rapportés. Deux d'entre-eux faisaient un usage chronique de glucostéroïdes ; les 4 autres ne présentaient pas de facteurs de risque. Des 4 résections de la première rangée du carpe, 3 ont donné un résultat excellent. Pour la quatrième une arthrodèse secondaire fut nécessaire.