

DELAYED POST-TRAUMATIC OSTEONECROSIS OF A VERTEBRAL BODY (KUMMELL'S DISEASE)

W. F. YOUNG¹, D. BROWN¹, A. KENDLER², D. CLEMENTS³

Kummell's disease is a rare spinal disorder characterized as avascular necrosis of a vertebral body occurring in a delayed fashion after minor trauma. The disease derives its name from the German surgeon Hermann Kummell, who described a series of patients with the disorder in 1895. Kummell's disease is distinguished from typical osteoporotic compression fractures, by virtue of the fact that patients with Kummell's disease develop symptoms in delayed fashion. In addition, Kummell's disease exhibits different signal characteristics on magnetic resonance imaging when compared to osteoporotic compression fractures. In this review we discuss the pathophysiology, histopathology and treatment of this interesting disorder.

Keywords : osteonecrosis ; vertebral ; Kummell's disease.

Mots-clés : ostéonécrose ; vertèbre ; maladie de Kummell.

INTRODUCTION

Post traumatic osteonecrosis of a vertebral body occurring in a delayed fashion was first described by the German surgeon Kummell in 1895 (2, 4, 11). Since Kummell's original description there have been several reports in the medical literature of this rare entity. The pathophysiology of Kummell's disease is unclear. Moreover, not until the development and refinement of xray was Kummell's concept anatomically confirmed. In this report we review the history, clinical symptoms, radiographic findings, histopathology and treatment of this rare entity. We also discuss current

concepts regarding the pathophysiology of delayed post traumatic vertebral osteonecrosis.

HISTORY

In 1895 the German Surgeon Hermann Kummell (1852-1937) described a series of six patients who sustained "vertebral body collapse" after seemingly minor trauma (in 6, 9). Three phases of development of the disease were described. In the first phase patients initially experienced back pain which subsided leading to an asymptomatic period. The second phase was characterized by recurrence of the pain weeks to months after the initial incident (15, 16, 17). In the third phase patients went on to develop kyphotic spinal deformities in the apparent absence of further trauma. Kummell went on to develop the following hypothesis regarding this entity : "Whether a traumatic compression fracture of the vertebrae is to be assumed in all cases I shall leave undecided ; nevertheless it seems very probable to me that in many of them... (we are dealing) with a compression, which is caused by trauma that is often slight, whereby the nutrition of the affected vertebral bodies is injured so that a softening and resorption or atrophy of the

¹ Department of Neurosurgery ; ² Department of Pathology ; ³ Department of Orthopaedics, Temple University Hospital, Philadelphia, Pa., U.S.A.

Correspondence and reprints : William F. Young, Department of Neurosurgery, Temple University Hospital, 3401 North Broad Street, Philadelphia, Pa. 19140, U.S.A. E-mail : wyoung@astro.ocis.temple.edu.

Table I. — Summary of Cases of Kummel's disease reported since 1950

Author/ Year	Age/Sex	Duration of Asym.*	Vertebra	Risk Factors	Treatment	Outcome
Steel/1951	23/male	6 months	T 10	none	bracing	pain resolved
Steel/1951	62/male	6 months	T 8	none	bracing	pain resolved
Brower/1981	71/male	3weeks	T 12	osteoporosis	unknown	unknown
Hermann/1984	45/female	1 month	L 1	Gaucher	unknown	unknown
Van Eenenaam/1993	75/male	3 weeks	T 11	steroids	bracing	pain resolved

* = asymptomatic

adjacent vertebral surfaces and progressive pressure atrophy develops..." (3). A. A. Verneuil (1823-1895), a French surgeon, described a similar case. In some instances the syndrome has been referred to as "Kummell-Verneuil disease" (16).

Kummell's original observations were made prior to the availability of xray. The concept that initial radiographic studies are "normal" in Kummell's disease was added when xrays were routinely available. Subsequent authors called into question the existence of Kummell's disease, once xrays were developed because of variability in the quality of the studies. Some authors thought that the reason initial xrays were "normal" was that the fracture was missed due to the poor quality of the studies. Not until the papers of Rigler (1931) and Steel (1951) was it clearly documented that initial xrays are normal and that only on delayed films does one see vertebral compression (3, 18).

CLINICAL FEATURES

Kummell's disease occurs primarily in middle age and the elderly. We found only one case in the English literature which occurred in childhood (12). Moreover, there may be a slight male predominance. Acute back pain is the most salient symptom during its early phases. Falls are the most common precipitating event. Pain typically occurs in the lower thoracic or upper lumbar regions. During the initial phase overt neurologic signs are absent. When the pain recurs a gross kyphotic deformity is often found in the thoracolumbar region of the back, corresponding to the collapsed vertebral body. Only one vertebral body is usually involved at the T8 through L4 level. Moreover, when pain recurs it is usually of greater intensity

when compared to the initial insult. During later phases overt neurologic signs can develop characterized by lower extremity weakness, paresthesias and bowel/bladder disturbance to varying degrees.

We analyzed in greater detail those cases reported to be Kummell's disease in the English literature since 1950. A total of nine cases of "Kummell's disease" were reviewed of which five met Kummell's original criteria for diagnosis. Moreover, these five cases also were documented to have "normal" plain xrays during the initial evaluation for back pain. Four cases were rejected as Kummell's disease because of either lack of an asymptomatic period prior to documenting vertebral body collapse or having a history of a second spinal injury during the asymptomatic period (table I).

RADIOGRAPHIC FEATURES

Ideally Kummell's disease is diagnosed on the basis of repetitive plain xrays, in which initial films do not demonstrate evidence of a fracture (5).

However, in many instances initial xrays are not performed due to the seemingly innocuous nature of the precipitating event. Radiographs are then performed when symptoms recur showing vertebral collapse (fig. 1, 2). Bone scan has been shown to demonstrate abnormalities during the early phase of Kummell's disease, when plain xrays are normal (19).

Maldague *et al.* first described the intravertebral vacuum cleft phenomenon (13). They described an accumulation of gas in a vertebral body seen on plain xray and CT as pathognomonic of Kummell's disease or spontaneous cases of vertebral osteonecrosis (fig. 3). However, subsequent authors have demonstrated the presence of intravertebral air in

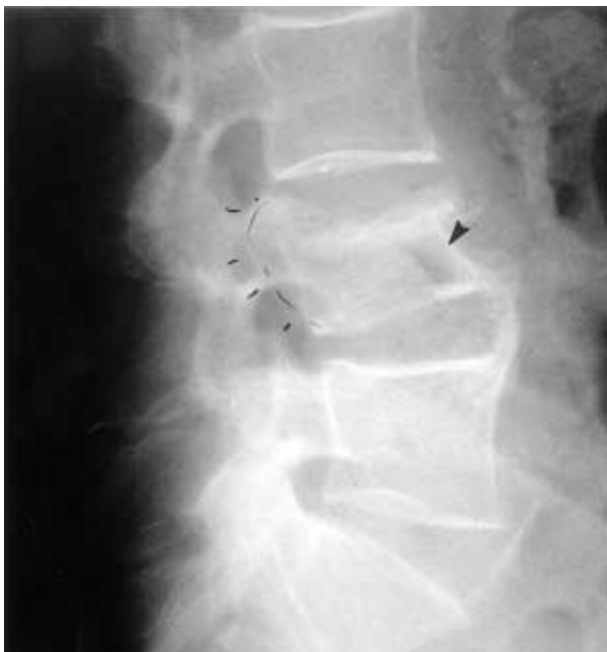

Fig. 1. — Lateral xray showing partial collapse of L4 vertebrae in a patient with Kummell's disease. See arrow pointing to intraosseous air.

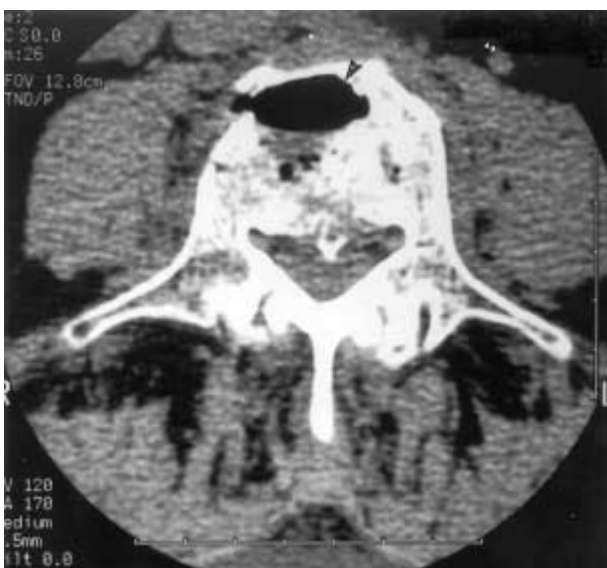

Fig. 3. — Axial CT scan of L4 vertebral body showing intraosseous air (see arrow).

cases of malignancy and intraosseous disc prolapse. The intravertebral vacuum cleft sign is probably not pathognomonic of Kummell's disease, but may be highly suggestive of it.

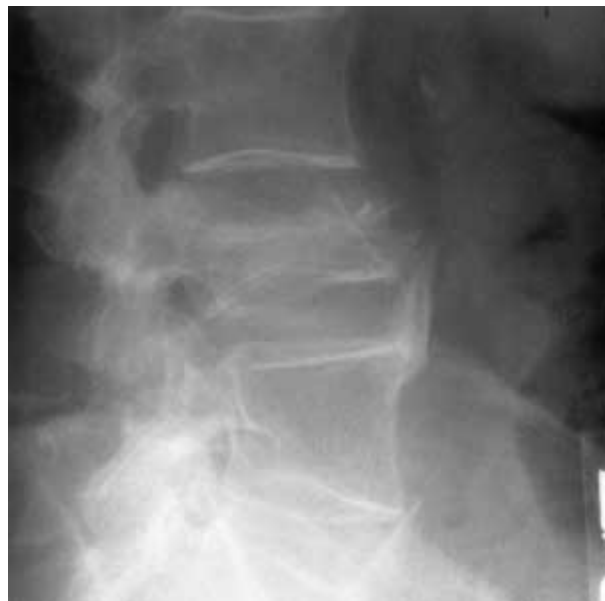

Fig. 2. — Lateral xray taken one month after xray in figure 1 showing progression of collapse.

Kummell's disease and spontaneous vertebral osteonecrosis can be distinguished from osteoporotic compression fractures since osteoporotic compression fractures are not as commonly associated with neurologic deficits. Moreover, osteonecrotic vertebral fractures typically have different signal characteristics on MRI (7, 14). Osteonecrotic vertebral collapse usually has an increased signal on T1-weighted images and decreased signal on T2-weighted images. Chronic osteoporotic fractures usually are not associated with MRI signal changes (8). In addition, a linear area of hyperintensity can be seen on MRI in cases of Kummell's disease and spontaneous vertebral osteonecrosis (fig. 4). This pattern of signal change is also referred to as the "double line sign". It corresponds to the intravertebral vacuum cleft phenomenon on plain xray indicative of intraosseous air. The double line sign has also been described in cases of avascular necrosis of the femoral head (14). The presence of a double line sign is thought to be highly suggestive of avascular necrosis of a vertebral body. The presence of necrosis on histopathology in cases where the diseased vertebra is biopsied or resected is confirmatory.

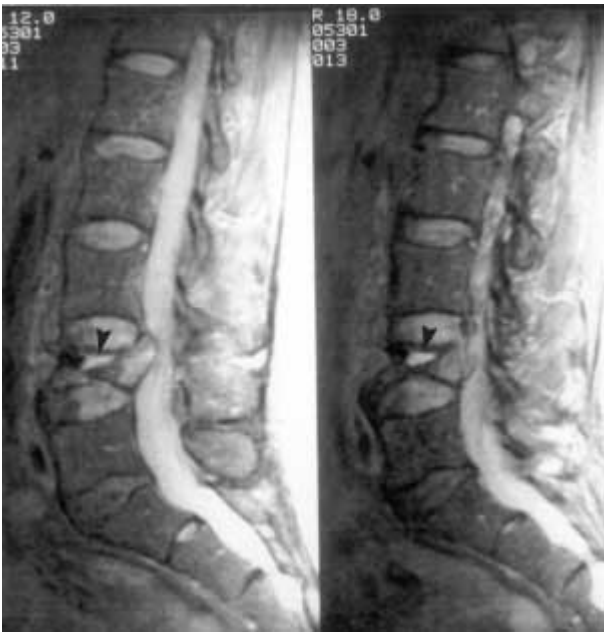

Fig. 4. — Sagittal T2- weighted MRI showing high signal changes in the L4 vertebral body with retropulsed bone and resulting canal compromise. In addition a linear hyperintense signal was seen with surrounding hypointensity.(see arrow).

TREATMENT

The treatment of Kummell's disease has depended to a large extent upon three factors : severity of the patient's pain, the degree of kyphotic deformity and the presence of any neurologic deficits. In the early medical literature most patients were reportedly treated conservatively with bed rest, lumbar traction or bracing. The more recent literature has demonstrated that patients can be treated successfully with surgery. Anterior thoracolumbar procedures, in which the diseased body is removed (corpectomy) and an interposition bone graft is placed, have been described (fig. 6). The advantages of surgery include : earlier ambulation of the patient, better correction of kyphotic deformities.

HISTOPATHOLOGY

Few authors have reported upon pathologic examination of vertebrae, which by clinical history had undergone delayed vertebral collapse. Cardis *et*

al. were the first to describe the histopathologic appearance of Kummell's disease from autopsy specimens. They reported that examination of an L2 vertebral body at autopsy demonstrated "...was wedge shaped and the spongiosa showed multiple hemorrhages. Microscopic examination of a sagittal section of the middle third of the 2nd lumbar body showed marked atrophy of the bony framework" (3). Kux described findings of "multiple microscopic fractures" which result in delayed collapse (in 5). Inflammatory changes and paravertebral fibrosis have also been described. Since most patients are middle age or elderly, degenerative changes including osteoporosis are likely to be a universal finding in specimens. Some authors have speculated that these factors predispose the vertebral body to fracture and thus serve as an explanation why seemingly innocuous injuries result in often very severe destruction in cases of Kummell's disease.

PATHOPHYSIOLOGY

The pathophysiology of Kummell's is not completely understood.

Kummell thought that the pathophysiology of this condition resulted from disruption of the vertebral body nutritional supply. A variety of other theories have been proposed to explain Kummell's disease. The anterior one-third of the vertebral body may represent a "watershed" zone due to the characteristics of the blood supply in this region. Disruption of the watershed zone arterial supply is akin to an avascular necrosis mechanism for this entity. This concept is supported by the fact that vertebral collapse in cases of osteonecrosis are often seen in the anterior one-third of the vertebral body (8). The use of chronic steroids has been associated with a number of cases of Kummell's disease. Chronic steroid usage may lead to fatty infiltration of the vertebral body leading to compression of the intramedullary arteries (12). Microfractures may lead to vascular disruption of medullary arterioles leading to osteonecrosis. Osteoporotic bone may be more susceptible to the development of Kummell's disease due to the presence of chronic microfractures.

Benedek and Nicholas proposed that vertebral microtrauma in association with a process which interferes with bone repair or healing leads to osteonecrosis of the vertebral body (3). Osteonecrosis of the vertebral body has been associated with chronic steroid usage, pancreatitis, sickle trait and Gaucher's disease (1, 10). Prolonged bed rest and premature weight bearing have also been invoked as possible contributing or inciting factors.

MEDICOLEGAL ASPECTS

Patients who have recurrent or persistent symptoms after seemingly innocuous thoracolumbar spinal trauma should have follow-up radiographic studies, even though initial studies were deemed normal. This is particularly true in patients who exhibit potential risk factors for Kummell's disease such as: advanced age, osteoporosis and chronic steroid usage.

Recently percutaneous vertebroplasty procedures are increasingly being utilized in cases of symptomatic osteoporotic compression fractures. It may be important to recognize those rare cases of Kummell's disease (vertebral osteonecrosis) and distinguish them from typical osteoporotic frac-

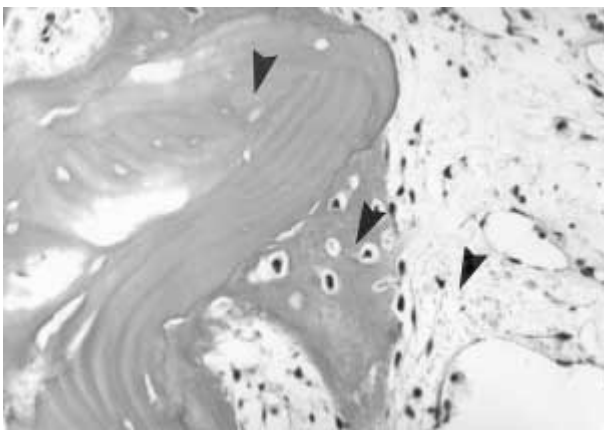


Fig. 5. —Histologic appearance of Kummell's disease : Top arrow showing area of necrotic bone. Middle arrow showing area of new bone formation. Lower arrow showing area of reactive fibrosis due to ischemia of the vertebral body. Hematoxylin and Eosin stain 8X.

tures, since the severe destruction of the vertebrae in Kummell's disease may increase the risk of retropulsion of bone or methylmethacrylate into the spinal canal during vertebroplasty.

ILLUSTRATIVE CASE

A 72-year old male began to experience lower back pain after shoveling snow.

His symptoms spontaneously resolved after a few days. Six weeks after this event he began to experience severe low back pain and lower extremity weakness. He was admitted to the hospital and plain xrays were obtained which demonstrated a compression fracture of the L4 vertebral body (fig. 1). His medical history was significant for diabetes mellitus. Neurologic examination was significant for paraparesis of the lower extremities (4/5 strength bilaterally). Bowel and bladder function were not affected. He was treated conservatively with bed rest and analgesic medications. However, a neurosurgical consultation was subsequently obtained which demonstrated further progression of collapse of the vertebral body (fig. 2). Computerized tomography (CT) was performed showing canal compression and intraosseous air (fig. 3). Magnetic resonance imaging (MRI) was obtained showing a linear hyperintense signal with surrounding low signal changes at the L4 vertebral body on T2-weighted images (fig. 4). A bone scan was performed which did not show any other lesions except degenerative changes at the L4 level. The patient was subsequently taken to surgery because of continued pain and neurologic deficit. An anterior retroperitoneal approach was initially performed in which a subtotal corpectomy was performed of the L4 vertebral body with placement of a strut graft from L3 to L5 consisting of autologous iliac crest graft. One week later a posterior fusion was performed using pedicle fixation.

Histopathologic examination of the L4 vertebral body revealed necrosis of the bone without evidence of malignant tumor consistent with Kummell's disease (fig. 5). The patient was transferred to a rehabilitation service and gradually became ambulatory with improved pain (fig. 6).

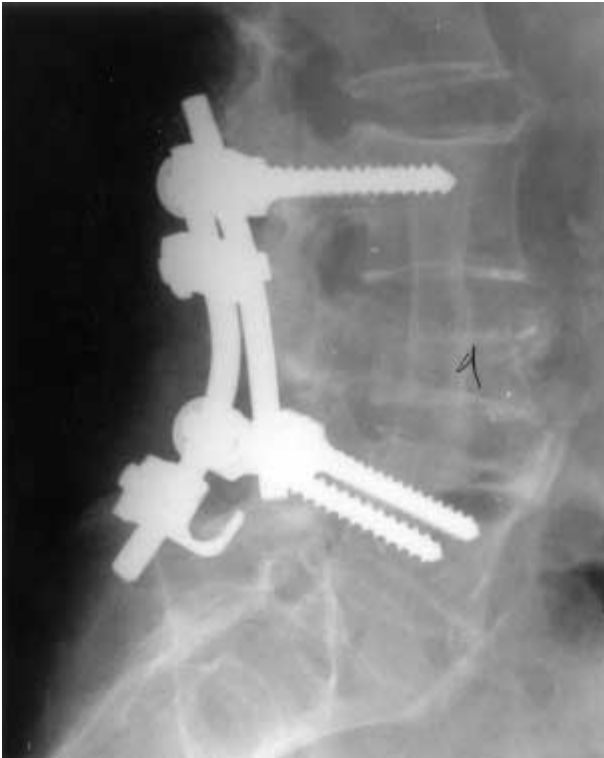

Fig. 6. — Postoperative lateral xray of same patient with Kummels'disease of the L4 vertebral body. Patient underwent an anterior corpectomy with placement of a bone graft followed by posterior instrumentation.

CONCLUSION

In this review we have summarized both the historical and modern aspects of delayed vertebral osteonecrosis or "Kummel's disease". Eventhough Kummel's disease is both rare in incidence and obscure in terms of pathophysiology, practitioners who treat spinal disorders should consider its occurrence in patients with recurrent pain after an asymptomatic period.

REFERENCES

1. Allen B. L., Jinkins W. Vertebral osteonecrosis associated with pancreatitis in a child. *J. Bone Joint Surg.*, 1978, 60-A, 985-987.
2. Baker R. Compression fracture of the vertebral bodies with delayed symptoms. (Kummel's Disease). *Surg., Gyn., Obst.*, 1920, 31, 359-362.

3. Benedek T., Nicholas J. Delayed traumatic vertebral body compression fracture ; part 2 : Pathologic Features. *Seminars in Arthritis and Rheumatism*, 1981, 10, 271-277.
4. Blaine E. Spondylitis Traumatica Tarda (Kummell's Disease). *Radiology*, 1930, 25, 551-561.
5. Brower A., Downey E. Kummell Disease : Report of a case with serial radiographs. *Diagnostic Radiology*, 1981, 141, 363-364.
6. Cardis J., Walker GF, Oliver R Kummell's disease. *Brit. J. Surg.*, 1928, 15, 616-625.
7. Chevalier X., Wrona N., Avouac B., Larget-Piet B. Thigh pain and multiple vertebral osteonecroses : Value of magnetic resonance imaging. *J. Rheumatology*, 1991, 18, 1627-1630.
8. Chou L., Knight R. Idiopathic avascular necrosis of a vertebral body : Case report and literature review. *Spine*, 1997, 22, 1928-1932.
9. Gorsch R. Compression fracture of the first lumbar vertebrae with delayed symptoms (Kummell's disease). *Ann. Surg.*, 1921, 73, 360-361.
10. Hermann G., Goldblatt J., Desnick R. Kummell Disease : delayed collapse of the traumatized spine in a patient with Gaucher Type 1 disease. *Brit. J. Radiology*, 1984, 57, 833-835.
11. Hosford J. Kummell's Disease. *Lancet*, 1936, 1, 249-251.
12. Jones F. Compression fracture of the spine developing delayed symptoms (post traumatic spondylitis or Kummel's disease). *JAMA*, 1923, 81, 1860-1867.
13. Laloux P., Lefèbvre S., Esselinckx W., de Cloedt P. Spinal cord compression secondary to vertebral aseptic necrosis. *Spine*, 1991, 16, 480-481.
14. Maldague B., Noel H., Malghem J. The intravertebral vacuum cleft : a sign of ischemic vertebral collapse. *Radiology*, 1978, 129, 23-29.
15. Naul L., Peet G., Maupin W. Avascular necrosis of the vertebral body M. R. *Imaging Radiology*, 1989, 172, 219-222.
16. Nicholas J., Benedek T., Reece G. Delayed traumatic vertebral body compression fracture. Part 1 : Clinical features. *Seminars in Arthritis and Rheumatism*, 1981, 10, 264-270.
17. Rigler L. Kummell's disease with report of a roentgenologically proved case *Am. J. Roentgenol*, 1931, 35, 749-753.
18. Steel H. Kummell's disease. *Am. J. Surg.*, 1951, 81, 161-167.
19. Van Eenenaam D., El-Khoury G. Delayed post-traumatic vertebral collapse (Kummell's disease) : Case report with serial radiographs, computed tomographic scans, and bone scans. *Spine*, 1993, 18, 1236-1241.

SAMENVATTING

W. F. YOUNG, D. BROWN, A. KENDLER, D. CLEMENTS. Laattijdige post-traumatische necrosis van een wervellichaam (Ziekte van Kummell).

De ziekte van Kummell is een zeldzame wervelaandoening, gekenmerkt door een laattijdige avasculaire necrosis van een wervellichaam na een mineur trauma. De naam is afgeleid van de Duitse chirurg, die een reeks patiënten met deze aandoening beschreef in 1895 n.l. Hermann Kummell.

De ziekte van Kummell onderscheidt zich van een typisch-osteoporotische compressie fractuur door het laattijdig optreden van de symptomen. Bovendien is het NMR beeld gekenmerkt door andere signaalkarakteristieken dan bij osteoporotische compressie.

In dit artikel worden ontstaansmechanisme, anatomopathologie en behandeling van deze ongewone aandoening besproken.

RÉSUMÉ

W. F. YOUNG, D. BROWN, A. KENDLER, D. CLEMENTS. Ostéonécrose tardive d'un corps vertébral (maladie de Kummell-Verneuil).

La maladie de Kummell-Verneuil est une pathologie rare qui touche le rachis et qui se caractérise par la nécrose avasculaire d'un corps vertébral, qui se produit de façon retardée après un traumatisme mineur. Elle doit son nom au chirurgien allemand Hermann Kummell, qui a décrit en 1895 une série de patients qui présentaient cette pathologie. Elle se distingue des fractures-tassements typiques de vertèbres ostéoporotiques par le fait que, dans la maladie de Kummell, les symptômes apparaissent de façon retardée. En outre, on observe en résonance magnétique, dans la maladie de Kummell, des perturbations de signal différentes de ce qui se voit dans les fractures-tassements sur ostéoporose. Les auteurs passent en revue la physiopathologie, l'histopathologie, et le traitement de cette curieuse maladie.