

CASE REPORT

ASSOCIATION OF SEVERE AUTOSOMAL RECESSIVE OSTEOPETROSIS AND DANDY-WALKER SYNDROME WITH AGENESIS OF THE CORPUS CALLOSUM

H. BEN HAMOUDA¹, M. N. SFAR², R. BRAHAM², M. BEN SALAH¹, A. AYADI¹,
H. SOUA¹, H. HAMZA², M. T. SFAR¹

A severe form of autosomal recessive osteopetrosis associated with Dandy-Walker syndrome and agenesis of the corpus callosum is reported in a full-term boy born to consanguineous parents. The diagnosis was made shortly after birth. Clinical features were cranio-facial dysmorphism, macrocephaly, hepatosplenomegaly, severe anemia and thrombocytopenia. Skeletal radiographs revealed generalized increase in bone density and abnormal metaphyseal remodeling. Cranial ultrasonogram and computed tomography scan showed Dandy-Walker syndrome, agenesis of corpus callosum and hydrocephalus. The patient rapidly developed severe medullary deficiency and a severe pulmonary infection. He died at the age of 2 months. This association seems extremely rare and was not previously reported in the literature.

Keywords : osteopetrosis ; newborn ; Dandy-Walker ; corpus callosum.

Mots-clés : ostéopétrose ; nouveau-né ; Dandy-Walker ; corps calleux.

INTRODUCTION

Autosomal recessive osteopetrosis is a very rare skeletal disorder in the infant. The exact incidence is not known, but is estimated to be one in 200 000 (6). The severe form of this disease is characterized by increased skeletal mass and bone density detected shortly after birth (2, 7). Infants affected by this disease have a very poor prognosis and mostly die during the first year of life (2, 6, 8). Some neurologic abnormalities have been noted associated

with autosomal recessive osteopetrosis, but the Dandy-Walker syndrome was previously not reported in the literature. We report here one personal observation.

CASE REPORT

Walid, a boy, was born at term by spontaneous vaginal delivery with a birthweight of 3400 g for a height of 50 cm and a head circumference of 36 cm. His parents were consanguineous in good health. He had a brother who died at 4 months of age from a severe form of osteopetrosis with psychomotor retardation and seizures. The pregnancy had been uneventful, but a fetal hydrocephalus was discovered by ultrasound examination at 32 weeks gestation. The poor prognosis of this brain abnormality was discussed with the parents who refused to arrest the pregnancy. Physical examination after birth revealed cranio-facial dysmorphism, scaphocephaly, forehead convexity, hypertelorism and abnormal eye movements. No other external anomalies were noted. Skeletal radiographs showed a generalized increase in bone density and abnormal

¹ Department of Pediatrics, Tahar Sfar University Hospital, 5111 Mahdia, Tunisia.

² Department of Radiology, Tahar Sfar University Hospital, 5111 Mahdia, Tunisia.

Correspondence and reprints : Hechmi Ben Hamouda, Department of Pediatrics, Tahar Sfar University Hospital, 5111 Mahdia, Tunisia.

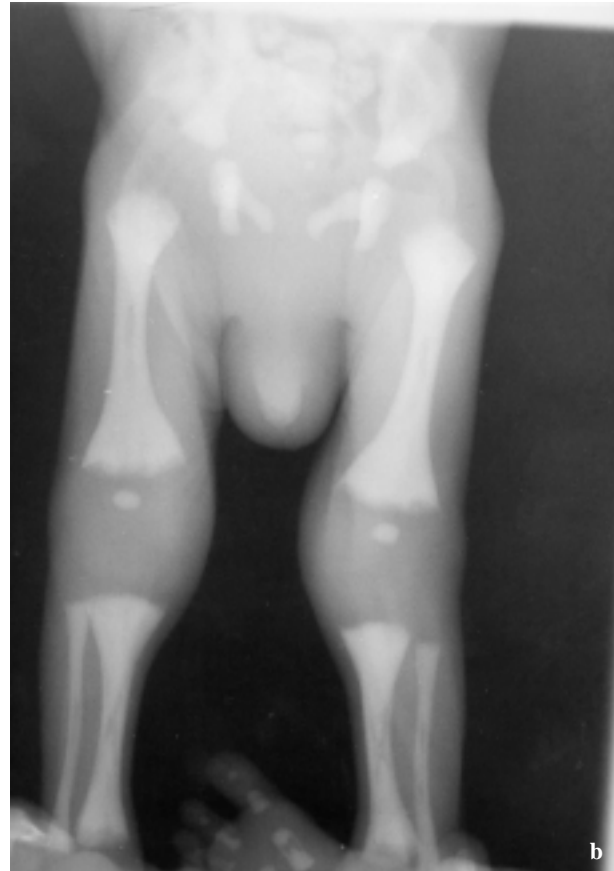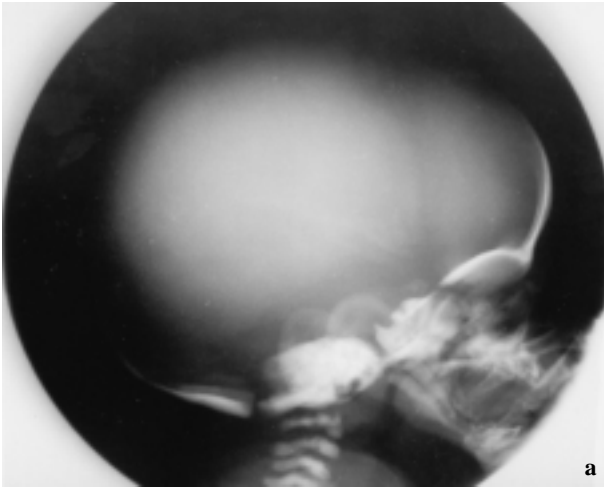


Fig. 1. — *a.* Radiograph of the skull : increased bone density of the base of the skull and sclerotic orbital rim. *b.* Radiograph of inferior limbs : increased bone density and abnormal metaphyseal remodeling.

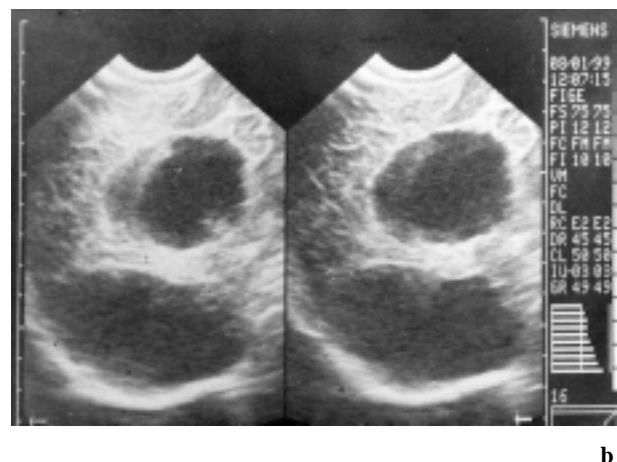
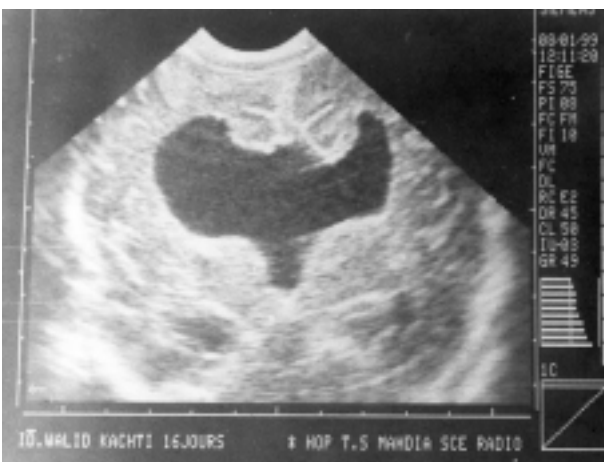
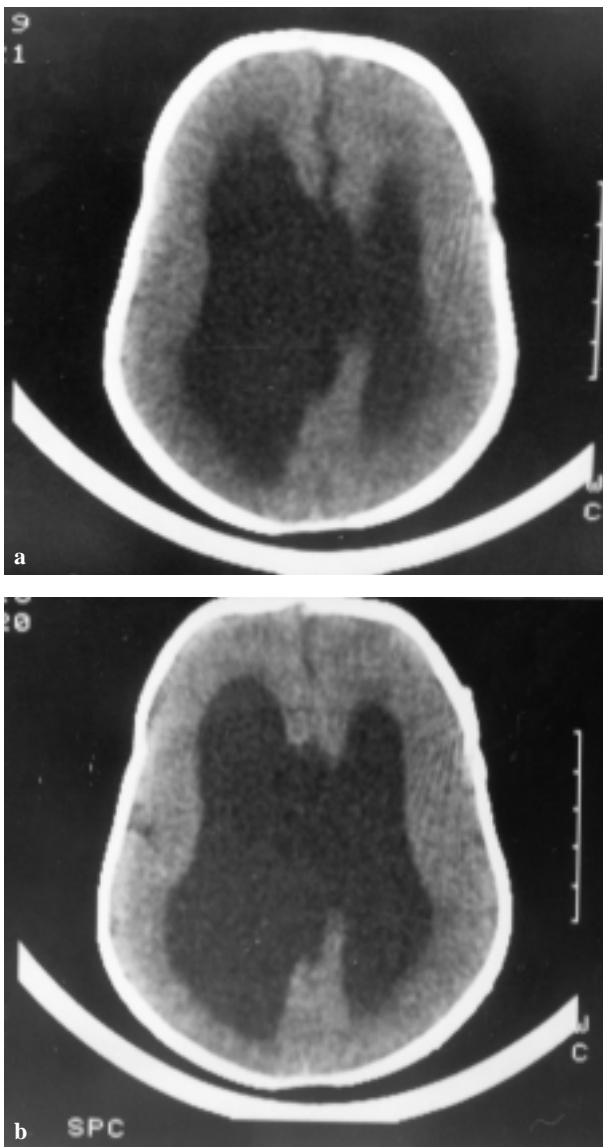


Fig. 2. — Ultrasound scan of the brain (7.5MHZ). *a.* coronal section through the third ventricle : agenesis of corpus callosum, absence of septum pellucidum and dilatation of both lateral ventricles. *b.* sagittal section : dilatation of third ventricle and cystic dilatation of fourth ventricle.

metaphysal remodeling (fig. 1). Cranial ultrasound examination revealed absence of the septum pellucidum, agenesis of corpus callosum, dilatation of both lateral ventricles and cystic dilatation of the fourth ventricle (fig. 2). Computed tomography (CT) scan of the brain confirmed the Dandy-Walker syndrome with agenesis of corpus callosum and severe hydrocephalus (fig. 3). At 19 days of age, the patient developed macrocephaly, hepatosplenomegaly, severe anemia, thrombocytopenia, hypocalcemia (serum calcium = 1,7 mmol/l) and severe medullary deficiency. He died at two months of age from a severe pulmonary infection.



DISCUSSION

Osteopetrosis is an inherited disorder of the skeleton caused by a defect in bone resorption by osteoclasts and is characterized by bone sclerosis (7, 10). The autosomal dominant form is characterized by cortical bone remodeling and exhibits mild symptoms in adult life (3). On the contrary, the autosomal recessive form comes with severe symptoms in infancy, but the clinical expression and the natural course of the disease have been variable, even between siblings (6). As was the case in our patient, the severe form of autosomal recessive osteopetrosis becomes manifest within the first three months of life. Infants affected by this form have a generalized increase in bone density,

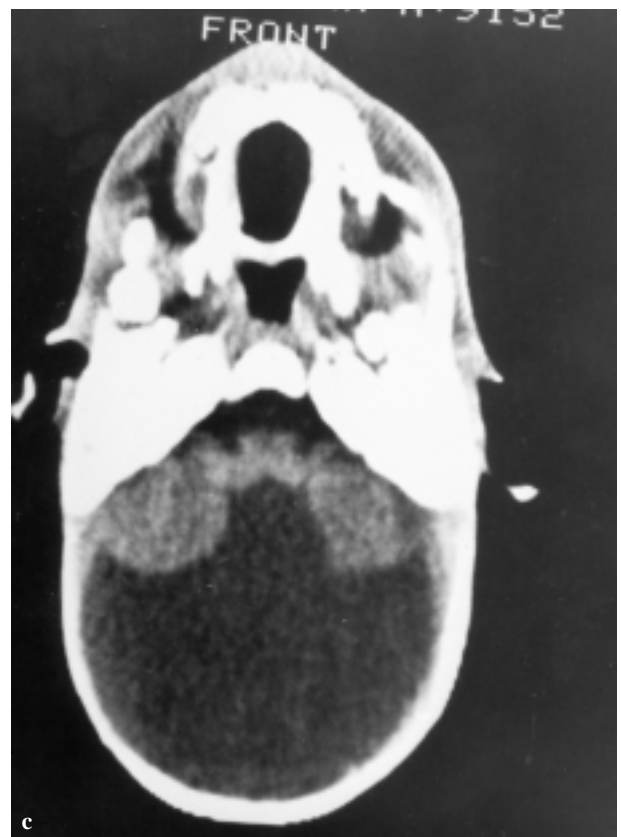

Fig.3. — CT scan of the brain. *a.* agenesis of corpus callosum. *b.* dilatation of both lateral ventricles. *c.* cystic dilatation of fourth ventricle.

abnormal bone remodeling, hepatosplenomegaly, anemia, thrombocytopenia, rachitic lesions and optic atrophy (2). These infants have a very poor prognosis and mostly die during the first year of life. There is an intermediate form of autosomal recessive osteopetrosis which has the same symptoms but less severe and appearing later and 30% of these patients can survive over 6 years (2, 6). The etiology of osteopetrosis is unknown, except in those patients suffering from carbonic anhydrase II deficiency who have a mild form of the disease (9).

Some neurologic abnormalities were reported in the literature, but the association with Dandy-Walker syndrome has not previously been described. To our knowledge, this is the first observation of autosomal recessive osteopetrosis associated with Dandy-Walker syndrome and agenesis of corpus callosum. This association demonstrates the variability of the major findings in autosomal recessive osteopetrosis. The review of 92 cases of autosomal recessive osteopetrosis by Gerritsen *et al.* (6), showed hydrocephalus in 4 patients and generalized neurodegeneration in 7 infants. Another report mentions agenesis of the corpus callosum associated with osteopetrosis in 2 siblings (8), as in our patient. Intracranial calcifications were reported in 22 patients with osteopetrosis, with proximal tubular acidosis and psychomotor retardation caused by carbonic anhydrase II deficiency. These calcifications were in the gray matter of the cortex and basal ganglia. These were not present at birth but appeared between 2 and 5 years of age (4, 9).

The diagnosis of autosomal recessive osteopetrosis is based on conventional radiography of the skeleton which shows a generalized increase in bone density, abnormal metaphyseal remodeling and rachitic lesions. Bone biopsy showed severe bone resorption and myelofibrosis (2). Recently, technetium-99 sulfur colloid scintigraphy and magnetic resonance were performed to determine quantitatively intramedullary hematopoiesis (5). However, cranial imaging by computed tomography or magnetic resonance is necessary to detect the neurodegeneration and neurologic abnormalities which aggravate the already poor prognosis of autosomal recessive osteopetrosis (1).

REFERENCES

1. Allen D., Elster A. D., Theros E. G., Lyndon K. L., Michael Y., Chen M. Cranial imaging in autosomal recessive osteopetrosis. *Radiology*, 1992, 183, 129-144.
2. Bejaoui M., Baraket M., Lakhoua R., Mezni F. *et al.* Recessive osteopetrosis: Identification of an intermediate form. *Arch. Fr. Pediatr.*, 1992, 49, 627-631.
3. Brockstedt H., Bollerslev J., Melsen F., Mosekilde L. Cortical bone remodeling in autosomal dominant osteopetrosis: a study of two different phenotypes. *Bone*, 1996, 18, 67-72.
4. Cumming W. A., Ohlsson A. Intracranial calcification in children with osteopetrosis caused by carbonic anhydrase II deficiency. *Radiology*, 1985, 157, 325-327.
5. Elster A. D., Theros E. G., Key L. L., Stanton C. Autosomal recessive osteopetrosis: bone marrow imaging. *Radiology*, 1992, 182, 507-514.
6. Gerritsen E. J. A., Vossen J. M., Givan Loo I. H., Hermans J., Helfrich M. H., Griscelli C., Fischer A. Autosomal recessive osteopetrosis variability of findings at diagnosis and during the natural course. *Pediatrics*, 1994, 93, 247-253.
7. Lajeunesse D., Busque L., Menard P., Brunette M. G., Bonny Y. Demonstration of an osteoblast defect in two cases of human malignant osteopetrosis. *J. Clin. Invest.*, 1996, 98, 1835-1842.
8. Rees H., Ang L. C., Casey R., George D. H. Association of infantile neuroaxonal dystrophy and osteopetrosis: a rare autosomal recessive disorder. *Pediatr. Neurosurg.*, 1995, 22, 321-327.
9. Ruffa G., Milanaccio C., Sbolgi P., Levato G. L. *et al.* Osteopetrosis and renal acidosis: a new case of this rare syndrome. *Minerva Pediatr.*, 1995, 47, 135-140.
10. Teitelbaum S. I. The osteoclast and osteopetrosis. *Mt. Sinai. J. Med.*, 1996, 63, 399-402.

SAMENVATTING

H. BEN HAMOUDA, M. N. SFAR, R. BRAHAM, M. BEN SALAH, A. AYADI, H. SOUA, H. HAMZA, M. T. SFAR. Ernstige autosomale recessieve osteopetrosis in associatie met een Dandy-Walker syndroom en een agenese van het corpus callosum.

Een dergelijk geval wordt beschreven bij een volderen boorling uit bloedverwante ouders. De diagnose was onmiddellijk duidelijk bij de geboorte. De klinische verschijnselen waren: cranio-faciaal dysmorfisme, macrocephalie, hepatosplenomegalie, zware anemie en thrombocytopenie. Skelet rontgenbeelden toonden diffuse botverdichting en abnormale metaphysaire botbouw.

Echografie van het hoofd door de fontanel en Ct scan van de hersenen toonden de agenesis van het corpus callosum en hydrocephalie en bevestigden het syndroom van Dandy-Walker. Het kind ontwikkelde snel tekens van medullaire insufficiëntie en stierf op de leeftijd van 2 maand, door een ernstige pulmonaire infectie. De beschreven associatie lijkt niet beschreven in de literatuur.

RÉSUMÉ

H. BEN HAMOUDA, M .N. SFAR, R. BRAHAM, M. BEN SALAH, A. AYADI, H. SOUA, H. HAMZA, M. T. SFAR. Ostéopétrose autosomique récessive sévère associée à un syndrome de Dandy-Walker et à une agénésie du corps calleux.

Une forme sévère d'ostéopétrose autosomique récessive associée à un syndrome de Dandy-Walker et à une agénésie du corps calleux est rapportée chez un nouveau-né à terme. Ses parents sont consanguins. Le diagnostic a été fait rapidement après la naissance devant une dysmorphie cranio-faciale, une macrocéphalie, une hépatosplénomégalie, une anémie sévère et une thrombocytopénie. Les radiographies du squelette ont montré une condensation osseuse diffuse avec des troubles du modelage métaphysaire. L'échographie transfontanelle et la tomодensitométrie cérébrale ont montré un syndrome de Dandy-Walker avec une agénésie du corps calleux et une hydrocéphalie. Le patient a présenté rapidement une insuffisance médullaire et est décédé à l'âge de 2 mois d'une infection pulmonaire sévère. Cette association semble être extrêmement rare et ne semble pas avoir été rapportée dans la littérature.