

# THREE CANCELLOUS BONE SCREWS VERSUS A SCREW-ANGLE PLATE IN THE TREATMENT OF GARDEN I AND II FRACTURES OF THE FEMORAL NECK

by H. KUOKKANEN, O. KORKALA, I. ANTTI-POIKA,  
J. TOLONEN, M. Y. LEHTIMÄKI and T. SILVENNOINEN

**A consecutive clinical series of 33 patients with either an undisplaced (Garden I) or minimally displaced (Garden II) femoral neck fracture was randomly divided into two operative protocols. Half of the fractures were treated with three cannulated cancellous bone screws, while the other half were treated with a standard screw-angle plate device. After a mean follow-up of 2 years, 4 patients had died, while 20 of the remaining 29 hips showed excellent or good, 3 fair and 6 poor functional results. The three-screw fixation seemed to yield more technical complications as compared to the screw-angle plate fixation. However, the differences in functional end-results were of no clear statistical significance. We conclude that the screw-angle plate device gives acceptable results in this group of fractures. The use of cannulated hip screws may be more advantageous in the treatment of dislocated femoral neck fractures, where the torsional strength of fracture fixation and femoral head viability are more critical.**

**Keywords :** hip ; fracture ; internal fixation.

**Mots-clés :** hanche ; fracture ; ostéosynthèse.

## RÉSUMÉ

*H. KUOKKANEN, O. KORKALA, I. ANTTI-POIKA, J. TOLONEN, M. Y. LEHTIMÄKI et T. SILVENNOINEN. Traitement des fractures du col fémoral type Garden I ou II soit par 3 vis à spongieux, soit par vis-plaque.*

Trente-trois patients, présentant une fracture sans déplacement (Garden I) ou avec déplacement minime (Garden II), furent traités arbitrairement par 2 techniques différentes. La moitié des fractures fut stabilisée par 3 vis à spongieux et l'autre moitié par un système de vis-plaque, type Richards. Après un recul de 2 ans on relevait 4 décès et 20 excellents résultats chez les 29 hanches restantes ; il y avait 3 résultats moyens et 6 mauvais résultats. La synthèse à l'aide de 3 vis fut à l'origine de plus de complications techniques que la technique de vis-plaque ; le résultat final fonctionnel fut cependant statistiquement comparable dans les 2 séries. Les auteurs concluent que la vis-plaque donne des résultats acceptables dans ce type de fracture. Les vis à spongieux, coulissantes sur Kirschner, présentent des avantages dans les fractures avec déplacement où la sollicitation en torsion est plus élevée et où la viabilité de la tête fémorale peut être compromise.

## SAMENVATTING

*H. KUOKKANEN, O. KORKALA, I. ANTTI-POIKA, J. TOLONEN, M. Y. LEHTIMÄKI en T. SILVENNOINEN. Drie spontiosa schroeven versus schroef-plaat in de behandeling van femurhalsfrakturen type I of II van Garden.*

Een serie van 33 patiënten met een niet verplaatste (Garden I) of minimaal verplaatste (Garden 2) frak-

---

Department of Orthopedics and Traumatology, University Central Hospital, Helsinki (Finland).

tuur van de femurhals werd arbitrair behandeld door osteosynthese met behulp van hetzij 3 spongiosaschroeven hetzij een schroef-plaat-systeem. Bij follow-up na 2 jaar waren 4 patiënten overleden, 20 van de overblijvende 29 heupen hadden een uitstekend of goed resultaat, 3 waren middelmatig en 6 waren functioneel minder goed. Er waren meer technische complicaties bij de fixatie met 3 spongiosaschroeven vergeleken met de schroef-plaat fixatie. Er was echter geen relevant verschil bij het functioneel eindresultaat. De auteurs konkluderen dat de schroefplaat fixatie zeer aanvaardbare resultaten geeft bij deze fracturen. De gecannuleerde heupschroeven kunnen meer aangewezen zijn bij de behandeling van verplaatste fracturen van de femurnek waar er meer torsiëkrachten in het spel zijn en waar de leefbaarheid van de femurkop kritischer is.

## INTRODUCTION

The indications for internal fixation of femoral neck fractures without dislocation are obvious, since the fractures usually unite well and the risk for osteonecrosis of the femoral head is small. The situation is totally different for dislocated fractures. In a recent retrospective series, only 8 out of 129 undislocated hips needed secondary arthroplasty, while one-fourth of dislocated fractures initially treated by osteosynthesis later needed arthroplasty (10).

Although there are numerous studies comparing different methods of internal fixation in all types of femoral neck fractures, no prospective randomized comparison of modern osteosynthesis methods in undislocated or minimally displaced fractures (types I and II) (3) has come to our attention. In undislocated cases internal fixation provides fracture retention, while in the dislocated cases the osteosynthesis is performed both to reduce and retain the fracture.

In a prospective randomized series of Garden I and II fractures, we compared the fixation with three cannulated cancellous bone screws to fixation with a screw-angle plate device.

## PATIENTS AND METHODS

From January 1985 to July 1986 a total of 33 consecutive Garden I and II fractures of the

femoral neck were treated in our department. The patients were randomly allocated to operative treatment either by a Richards screw-angle plate (SAP) or by three Mecron® cannulated cancellous bone screws (CBS) (fig. 1). We attempted parallel adjustment of the three screws as well as advancement of the screw tip to the cortical bone of the femoral head in both treatment rationales.

The operations were performed almost exclusively by younger staff surgeons. A straight lateral approach was used in all cases. The blood loss appeared somewhat less in the CBS group as compared to the SAP group (table I), probably because of the longer approach necessary for fixation of the side plate. Two-directional fluoroscopy was used to position the implants. Full postoperative weight-bearing was started on the first postoperative day (9).

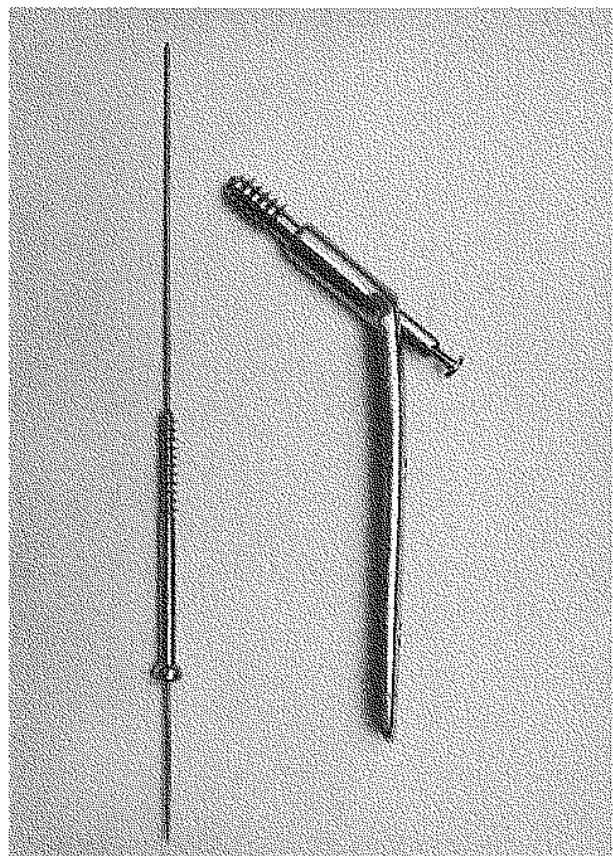


Fig. 1. — Richards screw-angle plate and Mecron® cannulated cancellous bone screw devices.

Table I. — Data for 33 patients with undisplaced or minimally displaced femoral neck fractures

	CBS	SAP
Age	72.5 years (range 62-82)	60.0 years (range 21-84)
Duration of surgery	60.6 min (range 40-90 min)	60.5 min (range 40-85 min)
Loss of blood	200 ml (range 50-350 ml)	245 ml (range 50-350 ml)

Four of the patients died for reasons not directly related to the hip fracture during the mean follow-up of 2 years (range 17 to 35 months). There was no mortality, during the first postoperative month. At follow-up, the hips were evaluated according to Harris (4). The grade of possible osteonecrosis of the femoral head was evaluated by a 6-stage scale (8).

## RESULTS

One deep venous thrombosis was recorded in the CBS group and one postoperative hemiplegia in the SAP group. There was 1 late postoperative death in the CBS and 3 in the SAP group. No infections were recorded. There were 4 other local complications in the CBS but none in the SAP group. Still, 1 delayed union was seen in the SAP group, which, however, resulted in a solid union after 1 year (fig. 2). In the CBS group 2 cases of femoral head necrosis (grades 5 and 6) were recorded, both resulting in a poor functional outcome (fig. 3 A, b). Moreover, in one additional hip one of the screws penetrated the femoral head during late impaction of the fracture site. In this case the penetrating screw was misaligned, as compared to the two other screws, which were inserted in a correct parallel manner (fig. 4). The functional result was fair, however. In the other case of osteosynthesis failure, the three screws were installed too nearly vertical (at an angle of 150°), and the fracture retention was insufficient, resulting in a fracture dislocation at 2 months.

During the follow-up period, 2 hip arthroplasties and 2 simple removals of symptomatic screws were performed in the CBS group. In the SAP group,

the fixation material was removed in 7 cases, but no additional surgery was indicated.

The functional end results were somewhat better in the SAP group, as compared to the CBS group. Still the difference was too small to give statistical significance (table II).

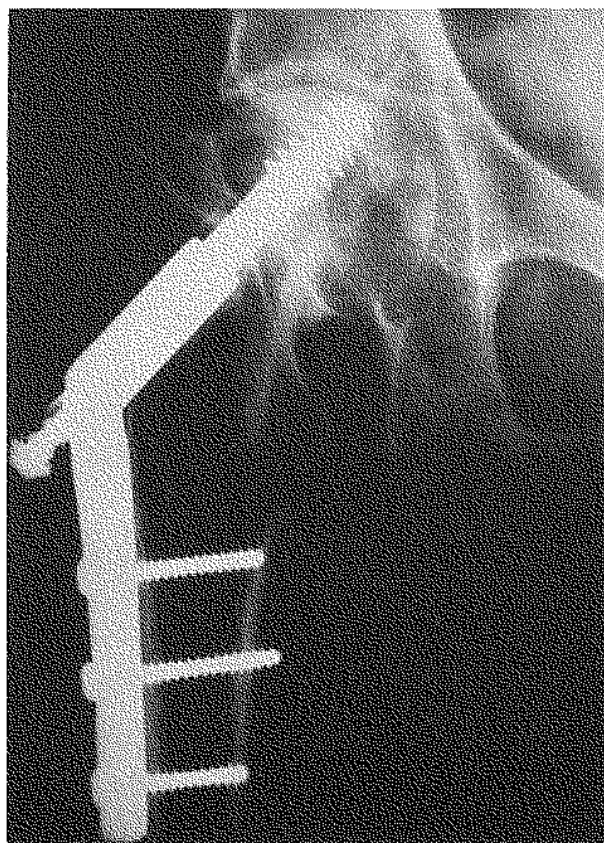
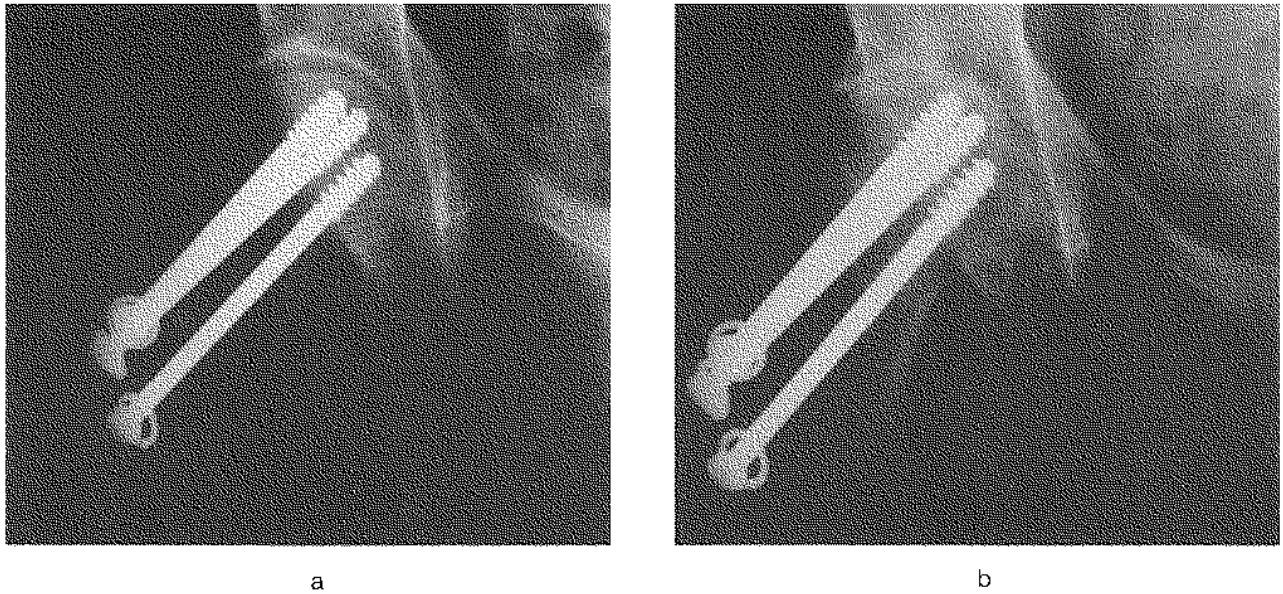


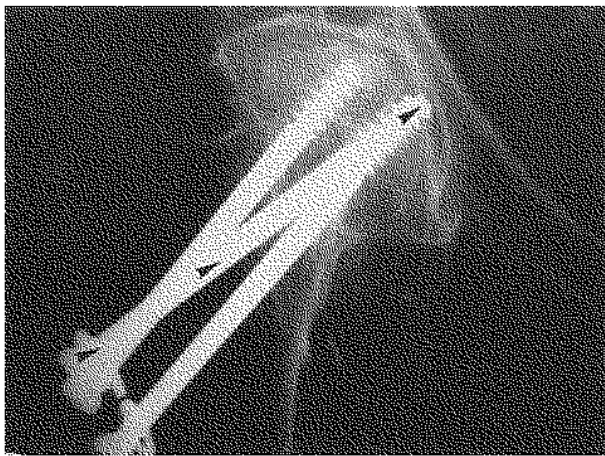
Fig. 2. — Radiograph of a 59-year-old woman 15 months after the SAP internal fixation. The bony union was solid 1 year after the fracture. Clinically the result was poor.

Table II. — Functional results of 29 patients at follow-up. The difference between CBS and SAP groups is not statistically significant ( $p = 0.288$ )

Harris Grade	CBS	SAP	total
excellent	7	9	16
good	2	2	4
fair	2	1	3
poor	4	2	6
total	15	14	29



*Fig. 3.* — Radiographs of an 83-year-old woman. a) 2 weeks and b) 15 months after the CBS osteosynthesis. Necrosis of the femoral head (grade 5) occurred and clinically the result was evaluated as poor.



*Fig. 4.* — Radiograph of a 79-year-old woman 22 months postoperatively. One screw penetrated the cortex of the femoral head during the late impaction of the fracture (arrows). The clinical result was fair.

## DISCUSSION

The use of internal fixation in nondisplaced and minimally displaced fractures of the femoral neck is known to yield acceptable results (1, 2, 12, 13). Accordingly, since the long-term results of arthro-

plasty are less satisfactory (6, 7, 11), this regimen appears preferable. Moreover, the primary mortality in the cases of hemiarthroplasty is 5 to 10% (6, 11), whereas there were no primary deaths in the present series. It seems reasonable to propose that selection of arthroplasty instead of osteosynthesis may increase the risk for primary postoperative death.

The stability of various fixation methods is well tested in cadaver femurs, where the fixation with three screws appears superior to other modes of osteosynthesis (5). In such controlled circumstances operative failures, sometimes seen in practice, are naturally excluded. It must be stated that application of three screws correctly is more difficult than application of one screw in a perfect centrally oriented course. This is especially true if younger surgeons are responsible for the operations.

Based on the present analysis, we therefore suggest that the Garden I and II fractures be treated either by a screw-angle place device or three parallel cancellous bone screws. The latter method should, however, be reserved for more experienced surgeons, and a specific guide apparatus for parallel adjustment of the guide wires prior to cannulated screw installation should be available. Although

such a guide was not available in these operations, it is our current experience that use of the guide improves the alignment of the screws and makes the operation easier.

### CONCLUSION

The rate of complications is low after internal fixation of nondisplaced or minimally displaced femoral neck fractures. Osteosynthesis is regarded as the treatment of choice even in the elderly for this type of fracture.

We found no significant difference between the results of internal fixation by three cannulated cancellous bone screws or a screw-angle plate device, but the three screws appeared somewhat more vulnerable to technical complications.

### REFERENCES

1. BARNES R., BROWN J. T., GARDEN R. S., NICOLL E. A. Subcapital fractures of the femur. *J. Bone Joint Surg.*, 1976, 58-B, 2-24.
2. CEDER L., STRÖMQVIST B., HANSSON L. I. Effects of strategy changes in the treatment of femoral neck fractures during a 17-year period. *Clin. Orthop.*, 1987, 218, 53-57.
3. GARDEN R. S. Low angle fixation in fractures of the femoral neck. *J. Bone Joint Surg.*, 1961, 43-B, 647-663.
4. HARRIS W. H. Traumatic arthritis of the hip after dislocation and acetabular fracture: treatment by mold arthroplasty. An end-result study using a new method of result evaluation. *J. Bone Joint Surg.*, 1969, 51-A, 737-755.
5. HUSBY T., ALHO A., RÖNNINGEN H. Stability of femoral neck osteosynthesis. Comparison of fixation methods in cadavers. *Acta Orthop. Scand.*, 1989, 60, 299-302.
6. KUOKKANEN H., KORKALA O. Christiansen replacement hemiarthroplasty in femoral neck fractures of the elderly. *Ann. Chir. Gynaecol.*, 1987, 76, 104-107.
7. LÜTHJE P., ROKKANEN P., RÖNTY J., PENTTI O. Faktoren, die Ergebnisse der Behandlung von Patienten mit Schenkelhalsfrakturen beeinflussen. *Z. Orthop.*, 1976, 114, 813-818.
8. MARCUS N. D., ENNEKING W. F., MASSAM R. A. The silent hip in idiopathic aseptic necrosis. *J. Bone Joint Surg.*, 1973, 55-A, 1351-1366.
9. NIEMINEN S. Early weightbearing after classical internal fixation of medial fractures of the femoral neck. *Acta Orthop. Scand.*, 1975, 46, 782-794.
10. NILSSON L. T., STRÖMQVIST B., THORNGREN K.-G. Nailing of femoral neck fracture. Clinical and sociologic 5-year follow up of 510 consecutive hips. *Acta Orthop. Scand.*, 1988, 59, 365-371.
11. RISKA E. B. Prosthetic replacement in the treatment of subcapital fractures of the femur. *Acta Orthop. Scand.*, 1971, 42, 281-290.
12. SVENNINGSSEN S., BENUM P., NESSE O., FURSET O. I. Internal fixation of femoral neck fractures. *Acta Orthop. Scand.*, 1984, 55, 423-429.
13. ZORMAN D., DE ROOSE M., GUNZBURG R., WAGNER J., BURNY F. Intracapsular fractures of the neck of the femur treated with the Thornton nail. *Acta Orthop. Belg.*, 1988, 54, 268-273.

H. KUOKKANEN  
 University Central Hospital  
 Department of Orthopedics  
 and Traumatology  
 Topeliuksenkatu 5  
 SF-00260 Helsinki (Finland)